

# León 2012

## Joint Meeting of

30<sup>th</sup> Meeting of the European Society of Veterinary Pathology  
Annual Meeting of the European College of Veterinary Pathologists  
24<sup>th</sup> Annual Meeting of the Spanish Society of Veterinary Pathology

León (Spain) September 5th to 8th of 2012





# León 2012 Joint Meeting

of

30th Meeting of the European Society of Veterinary Pathology,  
Annual Meeting of the European College of Veterinary Pathologist  
24<sup>th</sup> Annual Meeting of the Spanish Society of Veterinary Pathology

This meeting is dedicated to honour

**Prof. Franco Guarda**

León (Spain) September 5<sup>th</sup> to 8<sup>th</sup> 2012



## **ESVP Council**

Roderick Else (President), University of Edinburgh (United Kingdom)  
Sanja Aleksic-Kovacevic, University of Belgrado (Serbia)  
Cinzia Benazzi, University of Bologna (Italy)  
Felix Ehrensperger, University of Zürich (Switzerland)  
Juan Francisco García Marín, University of León (Spain)  
Carl Härd af Segerstad, National Veterinary Institute, Uppsala (Sweden)  
Jacob Walter, Bayer Schering Pharma AG, Berlin (Germany)

## **ECVP Council**

Mona Aleksandersen, (President), University of Oslo, (Norway)  
Chiara Brachelente, Perugia (Italy)  
Sean Callanan, University of Dublin (Ireland)  
Flavio Cramerí, Basel (Switzerland)  
Anja Kipar, University of Liverpool (UK) and University of Helsinki (Finland)  
Xavier Palazzi, Alfortville (France)  
Laura Peña, University of Madrid (Spain)  
Gabriele Pohlmeyer-Esch, Saint Louis (France)  
Paola Roccabianca, University of Milan (Italy)

## **SEAPV Council**

Aniceto Méndez Sanchez (President), University of Cordoba (Spain)  
Juan Manuel Corpa Arenas, Universidad CEU- Cardenal Herrera, Valencia (Spain)  
Antonio Espinosa de los Monteros y Zayas University of Las Palmas (Spain)  
José Pérez Arévalo, University of Cordoba (Spain)  
Rosa María Rabanal Prados, Universitat Autònoma de Barcelona (Spain)  
Juan Seva Alcaraz, University of Murcia (Spain)

## **ESVP / ECVP Scientific Committee**

Lluis Luján Lerma, (Chairperson), University of Zaragoza (Spain)  
Sean Callanan, University of Dublin (Ireland)  
Roderick Else, University of Edinburgh (United Kingdom)  
Juan Francisco García Marín, University of León (Spain)  
Carl Härd af Segerstad, National Veterinary Institute, Uppsala (Sweden)  
Ken Smith, University of London (United Kingdom)  
Federico Valenza, University of Torino (Italy)

## **Local Organizing Committee**

Juan Francisco García Marín (Chairperson), University of León.  
Julio Benavides Silvan, Animals Research Institute. CSIC. León.  
María del Carmen Ferreras Estrada, University of León.  
María José García Iglesias, University of León.  
Jorge González Fernández, Micros Veterinaria. León.  
Beatriz Martínez Fernández, University of León.  
Claudia Pérez Martínez, University of León  
Valentín Pérez Pérez, University of León.  
Laura Polledo Ruiz, University of León.

# INDEX

|   | Pages Nº         |
|---|------------------|
| <b>Welcome from the Local Organizing Committee</b>  | <b>5</b>         |
| <b>General Information</b>  | <b>7 - 10</b>    |
| <b>León city and Conference venue maps</b>  | <b>11 -13</b>    |
| <b>Program overview</b>   | <b>15 - 18</b>   |
| <b>Program schedule</b>   | <b>19 - 27</b>   |
| <b>Posters list</b>   | <b>28 - 44</b>   |
| <b>Keynotes</b>   | <b>45 - 58</b>   |
| <b>Oral presentations</b>   | <b>59 - 109</b>  |
| Mammary tumours pathology   | 61 - 66          |
| Tumour pathology  | 67 - 72          |
| Infectious diseases: virus, protozoa  | 73 - 78          |
| Infectious diseases: bacteria, mycoplasma   | 79 - 82          |
| Bird Pathology  | 83 - 85          |
| Fish pathology  | 86 - 89          |
| Wildlife and zoo animal pathology   | 90 - 95          |
| Neuropathology  | 96 - 101         |
| Digestive tract pathology   | 102 - 105        |
| Miscellanea   | 106 - 109        |
| <b>Poster presentations</b>   | <b>111 - 298</b> |
| Mammary tumours: canine and feline  | 113 - 126        |
| Tumours in dogs and cats  | 127 - 147        |
| Tumours in equine and ruminants   | 148 - 157        |
| Tumours in laboratory animals and other species   | 158 - 163        |
| Infectious diseases: virus, prions  | 164 - 183        |
| Infectious diseases: mycoplasma, bacteria and parasites                                   | 184 - 212        |
| Wildlife and zoo animal pathology   | 213 - 245        |
| Fish pathology  | 246 - 249        |
| Toxicopathology   | 250 - 261        |
| Naturally occurring and experimentally induced pathology in different organs and tissues. | 262 - 289        |
| Diagnostic methods  | 290 - 298        |
| <b>Discussion cases</b>   | <b>299 - 305</b> |
| <b>Participant list</b>   | <b>307 - 315</b> |



Dear colleagues,

On behalf of the scientific and local organizing committees and the University of León, it is a pleasure to welcome you in León in September, 2012. This year is a joint congress of the 30th Meeting of the European Society of Veterinary Pathology (ESVP) and the European College of Veterinary Pathology (ECVP), both societies which have been in close collaboration since 2009, is to be held in León together with the 24th Annual Meeting of the Spanish Society of Veterinary Pathology (SEAPV). As always, the meeting will provide an ideal venue for senior and young veterinary pathologist from all over the Europe and other countries and we will have the opportunity to share and interchange experiences on animal pathology as well as to know the recent scientific advances in this field.

This year there are six interesting keynotes and 240 contributions, including 186 posters, 49 oral presentations and 5 discussion cases. Moreover, interesting meetings, seminar and preconference satellite symposium, will be also held, improving the quality and interest of the Congress. We are sure that your contributions will be of importance, thus making it better year by year. Moreover, this will be also an excellent opportunity to meet again our colleagues and friends, and to discover León, one of the most interesting regions to visit in Spain.

The meeting is to be held at the Veterinary Faculty, founded in 1852, making it the oldest centre in the University of Leon. Moreover, the University is near the oldtown and the city centre and hotels, making it an easy place to walk around. In addition, León is also one of the most important farming areas of ruminants in Spain (particularly in dairy sheep) and thus, this Veterinary Faculty has specialized and is recognized in the knowledge in these species.

The City of León is located in the North of Spain should be discovered on foot, as its outstanding monuments and its rich cultural heritage are located within the Roman walls, the magnificent and wonderful Gothic Cathedral or the old city, with the “Barrio Humedo”. You can also enjoy the region of León with its spectacular natural landscape. León is also on “El Camino de Santiago” (“the road to Santiago” or “Saint James Way”). Accompanying persons are welcome and an attractive program has been drawn up for them.

We promise to do our best to make your stay at the meeting and in the city the most enjoyable.

Last of all, we wish to thank everyone who made this Congress possible.

Juan Francisco García Marín

Chairman of the Organizing Committee.





## GENERAL INFORMATION

**Date:** Wednesday 5<sup>th</sup> to Saturday 8<sup>th</sup> of September 2012

**Official language:** English

**Conference Venue:** The congress will be held at Veterinary Faculty. University of León. Campus de Vegazana, s/n. 24071. León. Spain. (2,5 km from central León.)

**Conference chartered buses:** there will be specially chartered buses available for conference delegates from hotels in the morning and from the venue in the afternoon. They will run according to the conference program.

**Conference Secretariat:** Located in the main hall and exhibition area of Conference Venue, from September 6<sup>th</sup> (8am) to September 8<sup>th</sup> (1pm)

**Registration:** In the Conference Secretariat at any time during the meeting. Also, it will be possible in the Welcome Reception Venue at “Real Colegiata de San Isidoro” (Plaza Santo Martino, 5) on September 5<sup>th</sup>, Wednesday, from 5pm to 8pm.

**Name badges:** will be distributed at the registration desks. Participants without badges will not be admitted to the Meeting activities.

**Exhibition area:** Located in the main hall of the conference venue. Commercial exhibition (technical equipment, instruments, laboratory products, etc), posters and coffee will be in this area.

**Oral presentations:** Time for oral presentation will last 10 minutes and 5 minutes for discussion. Any facilities for presentation will be available in rooms. (Computer, projectors, etc). Bring your presentation on a USB memory stick. Presentations should be handed in to the technician in the lecture room where your talk is scheduled at the latest during the pause before your session starts. The authors will be able to check the presentation before the session in the Aula 1B or in the computer room.

**Posters:** The poster area will be in the hall beside the lecture rooms. Poster viewing and tours times are scheduled in the program. Facilities to attach posters will be provided by the organizers. Posters must be placed from September 6<sup>th</sup> (in the early morning) to the end of the meeting (Saturday 8<sup>th</sup>). The organizers take no responsibility for posters which are not dismantled by this time. The posters stands will be marked with numbers. The number of each poster will coincide with the number in the program. If you wish to check your poster number in advance, please download the abstract book below.

**Discussion cases:** The cases will be presented in one session on Friday 7<sup>th</sup> September (see the program). The session will be interactive, the presenter will project a series of images of lesions and suggest a choice of diagnosis/answers in each case. The audience will then vote via wireless keypads, and the voting results will be displayed on the

## GENERAL INFORMATION

screen. After each voting session, time will be allowed for discussion of the diagnoses. Time for case presentation will be maximum of 5 minutes and 5-7 minutes for voting and discussion. Bring your presentation on a USB memory stick. Presentations should be handed in to the technician in the lecture room where your talk is scheduled at the latest during the pause before your session starts. The authors will be able to check the presentation before the session at the Aula 1B or in the computer room.

**Scientific Program:** Includes keynotes lectures, oral, poster and case presentation, and list of participants.

**Streaming, wifi and computer facilities:** Keynotes will be recorded and broadcast in real time on the conference website. We will give a password.

After, they will be edited and included in the website ESVP with restricted access to associated members.

In the conference venue there are open wifi for delegates of the Congress. To use it:

- Username: congreso
- Password: congreso2012
- Connected to: INTRACAMPUS

An open computer room is available beside main hall and exhibition area.

**Lunch and coffee:** Lunches will be served in a nearby building. Coffee and refreshment will be served in the main hall and outside (weather permitting). The name badge is your admission to the lunch and coffee area.

### **Social events:**

Welcome reception: Located in Leon's historical centre, the Royal Collegiate Church of Saint Isidoro Hotel is a restful sojourn in the Saint James's pilgrimage route, offering clients an experience they won't easily forget. In the same monumental complex where the hotel is housed, one can find the Real Colegiata de San Isidoro which has been declared National Monument and is considered one of the most complete complexes of the Romanic area. The welcome reception will take place in this building. Is in 5-10 minutes walking distance from the diferent hotels. 2 minute`s walk from the Cathedral. And 12 minutes` walk from the University of León. The welcome reception is included in the delegate fee.

On Thursday evening we will enjoy a guided night tour around the most emblematic places of the city and we will finish it at the "Barrio Húmedo" with infinity of bars, taverns and inns which have given the area its name ("húmedo" means wet, or damp, in reference to the availability to have something to drink) suggesting pleasant and entertaining possibilities. Let's enjoy Spanish Tapas!

Gala dinner: Located at "Hostal Parador San Marcos". Regal halls, spacious rooms, a library and a restaurant which in the main part offers an impeccable traditional

## GENERAL INFORMATION

gastronomy with touches of signature cuisine; all of which makes the Parador de San Marcos a unique establishment on St. James's Way and the Silver Way. The conference dinner is included in the delegate fee.

Post Conference Tour: The post conference tour includes a guided tour to Caves of Valporquero, bus transport and a lunch with typical gastronomy of the region in a restaurant with wonderful views of León Mountain. The bus departs from Leon in the afternoon, at the end of the conference (Saturday afternoon). The bus will be back in León approximately at 19:00h.

Accompanying person program: This program includes:

- Welcome Reception Cocktail
- On Thursday 6<sup>th</sup> we offer you an all day tour of the western region. The bus will arrive back in León at approximately 19:00h. Afterwards you can enjoy the guided night tour.
- Guided tour of the City: On Friday 7<sup>th</sup>. Morning: 12:00h to 14:00h A guided tour around the City, visiting the main important buildings. At 14:30h lunch at wine cellar turned into a restaurant, where you can taste the gastronomy and culinary secrets of León. At the afternoon you will have free time until the Conference Gala Dinner

### **León City:**

The congress will be held in the Veterinary Faculty at the León University. Veterinary Faculty was founded in 1852 being the most ancient center of the University of León and giving rise to the future University. The University is near the downtown and to the main centre.

The city of León should be discovered step by step and on foot, as its precious monuments and its rich cultural heritage are located inside the Roman walls with medieval remodeling with border the old city. And, of course, it's wonderful Gothic Cathedral. Apart from that, tourists coming to León will also have the chance to enjoy visiting a modern and commercial city, with residential neighbourhoods, big avenues and garden areas. You can also find the "Barrio Húmedo"(the "wet district"), which is a real temptation for people as their offer the very best gastronomy and wines of the region, which can be tasted either by "tapeo" (a very typical Spanish habit wich consists in eating tapas, minisnacks and cuisine in miniature) or by savouring a delicious meal in a good restaurant. We are sure that you will enjoy the visit to this city and the region.

## GENERAL INFORMATION

### Useful telephone number:

- Tourist Office: 0034- 987 23 70 82
- RENFE station, Spanish Railway: 0034- 902 24 02 02
- Bus station: 0034- 987 21 10 00
- Urban Transport: 0034- 987 89 56 68
- Leon Airport: 0034- 987 87 77 00
- Radio Taxi: 0034- 987 26 14 15
- Post Office: 0034- 902 19 71 97

### Local City buses Buses to the conference venue:

There are local urban buses from Santo Domingo Square (hotel area) to the University of León (Conference venue): Lines 3 and 4.

Monday to Friday:

Departure from Santo Domingo Square: 7am to 11pm, frequency 20 minutes.

Departure from University: 7.30am to 10.30pm, frequency 20 minutes

Saturday:

Departure from Santo Domingo Square: 7am to 3pm, frequency 60 minutes.

Departure from University: 7.30am to 14.30pm, frequency 60 minutes

### Distances from hotels to Santo Domingo Square:

San Marcos: 20 minutes walking.

Real Colegiata: 5 minutes walking.

Riosol: 15 minutes walking.

Conde Luna: 5 minutes walking.

Alfonso V: 5 minutes walking.

París: 5 minutes walking.

Infantas de León and Campus San Mamés: It is easier and quicker to walk to the University (15' and 5' minutes respectively).

We will provide you a map.

**Disclaimer:** The organizers are not liable for damages and/or losses of any kind which may be incurred by the meeting delegates or by any other individuals accompanying them, both responsible for their own safety and belongings.

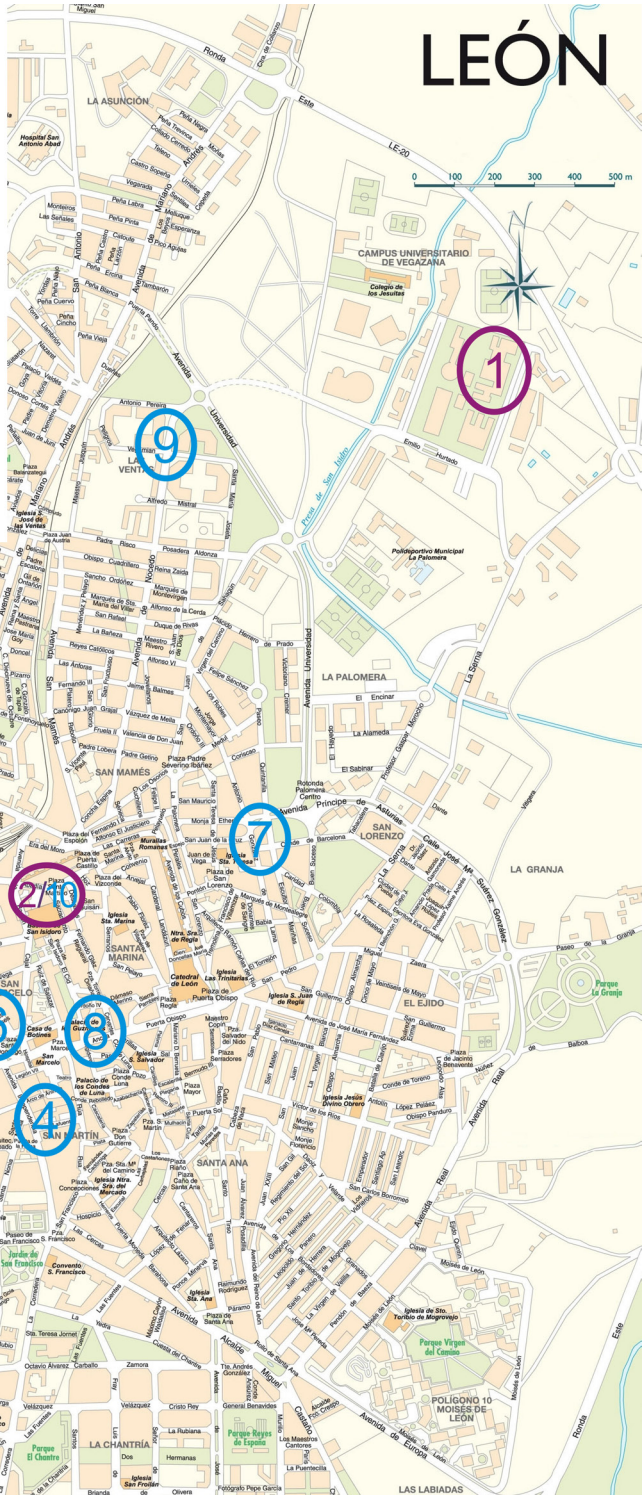**LEÓN CITY**  
**AND**  
**CONFERENCE VENUE**  
**MAPS**

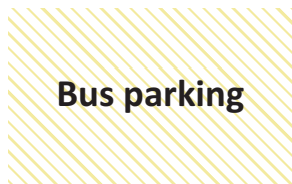
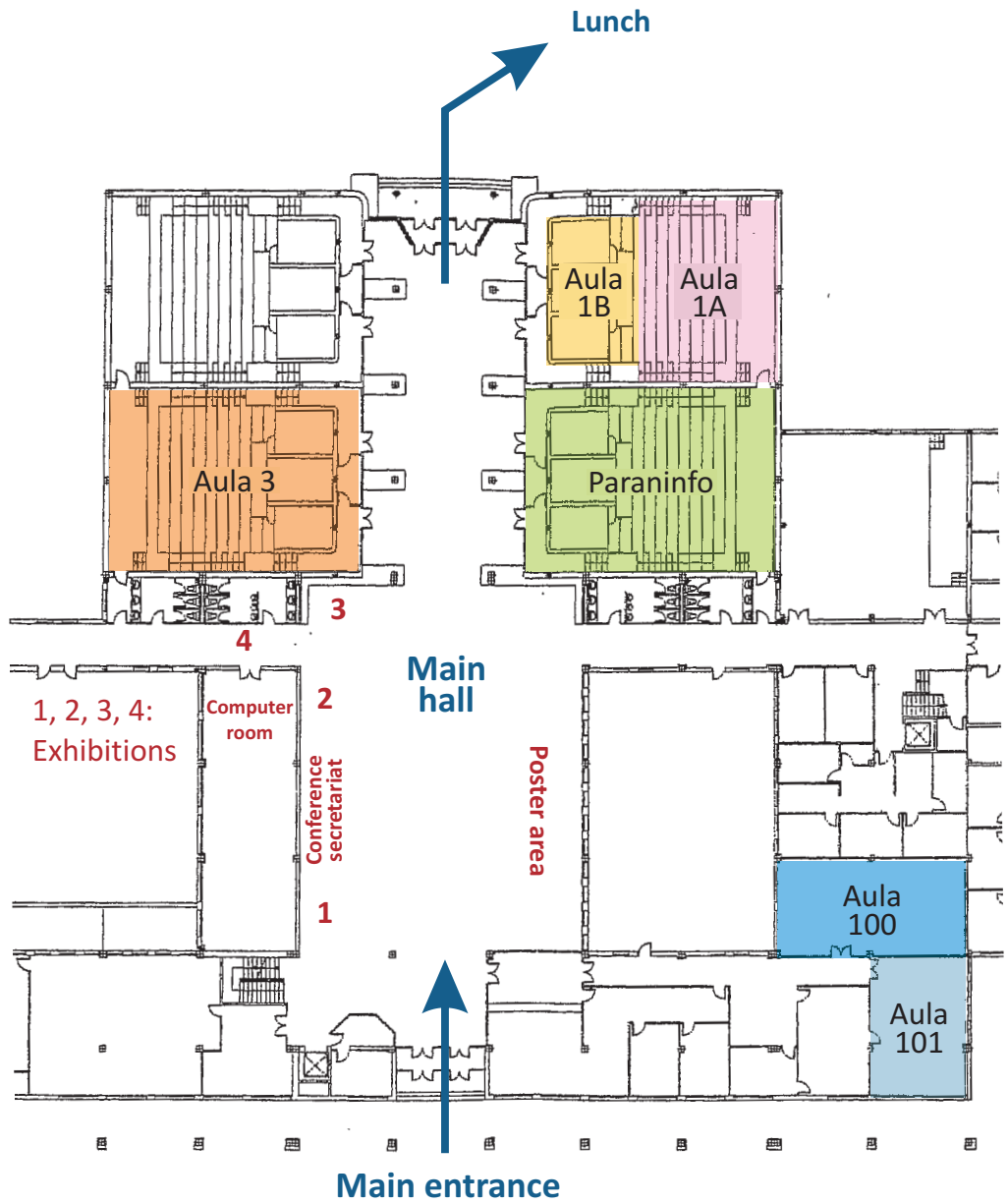
# MAPS

1. Conference Venue
2. Welcome reception venue

## Hotels

3. Parador de San Marcos
4. Conde Luna
5. Riosol
6. Alfonso V
7. Infantas de León
8. París
9. Campus San Mamés
10. Real Colegiata









## PROGRAM OVERVIEW

**Wednesday, 5th September 2012**

|                      |  |
|----------------------|--|
| <b>15:30 - 19:00</b> | <b>Satellite Symposium: Neuropathology</b><br><b>Speakers: K. Matiasek. University of Munich</b><br><b>M. Pumarola Batlle. Autonomia University of Barcelona</b> |
| <b>18.00</b>         | <b>Registration (Welcome Reception Venue)</b>  |
| <b>20.00</b>         | <b>Opening Ceremony and Welcome Reception</b><br><b>Hospedería Colegiata San Isidoro</b>   |

PROGRAM OVERVIEW

**Thursday, 6th September 2012**

|               |   |  |
|---------------|---|--|
| 8.15          | <b>Registration</b> (Conference Venue)  |  |
| 8.45 - 9.00   | <b>Opening of the Conference</b> (Main Room: Paraninfo)   |  |
| 9.00 - 10.45  | <b>Keynotes Lectures 1 and 2:</b> (Main Room: Paraninfo).<br>“Schmallenberg and other teratogenic viruses”.<br>Sandra Scholes. Animal Health Veterinary Laboratories Agency. UK<br>“Orthobunyavirus malformations: Akabane, Cache Valley and Schmallenberg viruses: not new, just a change in venue”<br>John Edwards. Texas A&M University. USA |  |
| 10.45 - 11.15 | <b>Coffee break</b>   |  |
| 10.45 - 11.30 | <b>Poster viewing and guided tour presentation 1.</b><br>Simultaneous tours. A: P15-P25; B: P51-P61 and C: P136-P147.   |  |
| 11.30 - 13.00 | <b>Oral presentations:</b><br>Session 1A (Paraninfo)<br>Infectious diseases: virus, protozoa<br>(O13 - O18)   | <b>Oral presentations:</b><br>Session 1B (Aula 3)<br>Mammary tumours pathology<br>(O1 - O6)  |
| 13.00 - 14.15 | <b>Lunch</b>  |  |
| 14.15 - 15.30 | <b>Poster viewing and guided tour presentation 2</b><br>Simultaneous tours. A: P35-P45; B: P86-P97 and C: P98-P110.   |  |
| 15.30 - 16.30 | <b>Keynote Lecture 3:</b> (Main Room: Paraninfo)<br>“Transboundary Animal Diseases: Pathology and Pathogenesis”.<br>Corrie Brown. University of Georgia, Athens. USA  |  |
| 16.30 - 17.00 | <b>Coffee break</b>   |  |
| 16.30 - 17.00 | <b>Presentation of the European Association of Veterinary Neuropathology (EAVN).</b> (Aula 1A)  |  |
| 17.00 - 18.30 | <b>Poster viewing and guided tour presentation 3</b><br>Simultaneous tours. A: P1-P14; B: P70-P85; C: P148-P163 and D: P176-P184.   |  |
| 17.00 - 18.30 | <b>Oral presentations</b><br>Session 2 (Paraninfo)<br>Wildlife pathology<br>(O31 - O36)   | <b>Seminar: Q&amp;A Session</b> (Aula 3)<br>ECVF Exam Informative Session<br>Andrea Groene. University of Utrecht<br>Koen Chiers. University of Gent |
| 18.30 - 19.30 | <b>ECVP annual Meeting</b> (Paraninfo)  |  |
| 18.45 - 19.45 | <b>SEAPV annual meeting</b> (Aula 3)  |  |
| 21.00         | <b>Old town night tour and “Tapas”</b>  |  |

PROGRAM OVERVIEW

Friday, 7th September 2012

|               |   |  |
|---------------|---|--|
| 9.00 - 10.00  | <b>Keynote Lectures 4:</b> (Main Room: Paraninfo).<br>“Wildlife Disease Control in the 21st Century”<br>Christian Gortázar. IREC, Ciudad Real, Spain.                 |  |
| 10.00 - 11.00 | <b>Oral presentations:</b><br>Session 3A (Paraninfo)<br>Bird Pathology (Infectious diseases)<br>(O23-O26)   | <b>Oral presentations:</b><br>Session 3B (Aula 3)<br>Fish pathology<br>(O27- O30)      |
| 11.00 - 11.30 | Coffee break  |  |
| 11.00 - 12.00 | <b>Poster viewing and guided tour presentation 4.</b><br>Simultaneous tours. A: P26-P34; B: P62-P69 and C: P121-P131.   |  |
| 12.00 - 13.00 | <b>Oral presentations:</b><br>Session 4A (Paraninfo)<br>Infectious diseases: Bacteria,<br>mycoplasma<br>(O19-O22)   | <b>Oral presentations:</b><br>Session 4B (Aula 3)<br>Discussion Cases<br>(C1-C5)       |
| 13.00 - 14.15 | Lunch   |  |
| 14.15 - 15.30 | <b>Poster viewing and guided tour presentation 5.</b><br>Simultaneous tours. A: P46-50/P132-135; B: P111-120; C: P164-P175.   | <b>International Veterinary Pathology Coalition Meeting (ECVP - ACVP).</b><br>(Aula 3) |
| 15.30 - 16.30 | <b>Keynote Lecture 5:</b> (Main Room: Paraninfo)<br>“What’s new on the histopathology of canine mammary tumors?”<br>Laura Peña. Complutense University, Madrid, Spain |  |
| 16.30 - 17.00 | Coffee break  |  |
| 17.00 - 18.30 | <b>Oral presentations:</b><br>Session 5A (Paraninfo)<br>Neuropathology<br>(O38- O43)  | <b>Oral presentations:</b><br>Session 5B (Aula 3)<br>Tumours pathology<br>(O7- O12)    |
| 18.30 - 19.45 | ESVP Annual Meeting (Paraninfo)   |  |
| 21.00         | Conference Dinner at “Hostal San Marcos”  |  |

## PROGRAM OVERVIEW

### Saturday, 8th September 2012

|                      |   |  |
|----------------------|---|--|
| <b>10.00 - 11.00</b> | <b>Keynote Lectures 6:</b> (Main Room: Paraninfo).<br>“Intestinal inflammatory disease in animals as a slow infection”.<br>Ramón A. Juste.<br>NEIKER, Bilbao, Spain |  |
| <b>11.00 - 12.00</b> | <b>Oral presentations:</b><br>Session 6A (Paraninfo)<br>Digestive Tract Pathology<br>(O44-O47)  | <b>Oral presentations:</b><br>Session 6B (Paraninfo)<br>Miscellanea<br>(O48-O51) |
| <b>12.00 - 12.30</b> | <b>Coffee break (“Brunch”)</b>  |  |
| <b>12.30</b>         | <b>Closing of Congress</b>  |  |
| <b>12.30</b>         | <b>Post Congress Tour</b> (Departure from Congress Venue)   |  |

## Thursday, 6th September 2012

- 8.45 - 9.00** **Opening of the Conference** (Main Room: Paraninfo)
- 9.00 - 10.45** **Keynotes Lectures 1 and 2:** (Main Room: Paraninfo)  
*Chairpersons: Valentín Pérez and Antonio Fernández*  
**1. Schmallenberg and other teratogenic viruses.**  
Sandra Scholes. UK  
**2. Orthobunyavirus malformations: Akabane, Cache Valley and Schmallenberg viruses: not new, just a change in venue.**  
John Edwards. USA
- 10.45 - 11.15** **Coffee break**
- 10.45 - 11.30** **Poster viewing and guided tour presentation 1:**  
*Chairpersons: A: J. Ortega; B: M. Aleksandersen and C: B. Biolatti*  
Simultaneous tours: A: P15-P25; B: P51-P61 and C: P136-P147.
- 11.30 - 13.00** **Oral presentations:**  
Session 1A (Paraninfo)  
Infectious diseases: virus, protozoa (O13-O18)  
*Chairperson: M. Hilbe/L. González*
- O13- TERATOGENIC EFFECTS OF SCHMALLEMBERG VIRUS INFECTION IN SHEEP AND CATTLE**  
*Peperkamp K, Wouda W, Dijkman R, Greijdanus S, Junker K, Roumen T, Vos J. The Netherlands.*
- O14- "LOUPING ILL" IN GOAT IN NORTHERN SPAIN: MORE THAN A FORGOTTEN DISEASE**  
*Balseiro A, Royo LJ, Pérez C, Copano MF, Rubio T, Höfle U, Prieto M, García Marín JF. Spain.*
- O15- EFFECT OF TWO STRAINS OF PRRSV ON THE EXPRESSION OF DIFFERENTIATION ANTIGENS OF MONOCYTE-DERIVED DENDRITIC CELLS**  
*Rodríguez-Gómez IM, Burgara-Estrella AJ, Mateu E, Gómez-Laguna J, Carrasco L, Saalmüller A, Käser T. Spain.*
- 11.30 - 13.00** **Oral presentations:**  
Session 1B (Aula 3)  
Mammary tumours (O1-O6)  
*Chairperson: C. Benazzi / J. Martín de las Mulas*
- O1- NATURAL HISTORY OF IN SITU, MICRO-INVASIVE, AND INVASIVE CANINE MAMMARY CARCINOMAS**  
*Nguyen F, Loussouarn D, Godard T, Morio F, Ibisch C, Campone M, Abadie J. France.*
- O2- CORRELATION BASED ON THE PROTEIN EXPRESSION PROFILE BETWEEN PRIMARY CANINE MAMMARY TUMOUR AND ITS LYMPH NODE METASTASIS**  
*Beha G, Brunetti B, Asproni P, Muscatello LV, Millanta F, Poli A, Sarli G, Benazzi C. Italy.*
- O3- IN VITRO ESTABLISHMENT AND CHARACTERIZATION OF MYOEPITHELIAL CELL LINES FROM FOUR CANINE MAMMARY CARCINOMAS AND TWO NORMAL MAMMARY GLANDS**  
*Sánchez-Céspedes R, Maniscalco L, Iussich S, Martignani E, Millán Y, Guillón Luna, S, De María R, Martín de las Mulas J. Spain.*

## PROGRAM

**O16- A VIRULENT EASTERN EUROPEAN PRRSV STRAIN INDUCES HIGH LEVELS OF IL-1 $\alpha$  IN THE LUNG**

*Amarilla S.P, Morgan S; Gómez-Laguna J, Graham S, Frossard JP, Steinbach F, Carrasco L, Salguero FJ. Spain.*

**O17- IMMUNE PHENOTYPING OF PLACENTAS FOLLOWING EXPERIMENTAL INOCULATION WITH NEOSPORA CANINUM DURING PREGNANCY.**

*Cantón G, Benavides J, Maley S, Katzer F, Palarea-Albaladejo J, Bartley P, Rocchi M, Innes E, Chianini F. Scotland.*

**O18- TOXOPLASMOSIS: DOES RECRUDESCENCE OCCUR IN A FLOCK IN BREEDING SEASONS AFTER AN OUTBREAK?**

*Edwards, JF, Dubey JP.*

**O4- MARKERS FOR CIRCULATING TUMOR CELLS ARE ABLE TO IDENTIFY BLOOD FROM DOGS WITH MALIGNANT MAMMARY TUMORS**

*Klopfleisch R, da Costa A, Gruber AD. Germany.*

**O5- EXPRESSION OF MAMMALIAN TARGET OF RAPAMYCIN (mTOR) IN FELINE MAMMARY TUMORS: A POTENTIAL TARGET THERAPY IN TRIPLE NEGATIVE TUMORS**

*Maniscalco L, Iussich S, Denina M, Martín de Las Mulas J, Millán Y, Biolatti B, Sasaki N, Nakagawa T, De Maria R. Italy.*

**O6- TARGETING CANCER STEM CELLS IN CANINE MAMMARY CANCER**

*Pereira D, Vieira AF, Schmitt F, Paredes J, Gama A. Portugal.*

**13.00-14.15 Lunch**

**14.15 - 15.30 Poster viewing and guided tour presentation 2**

*Chairpersons: A: F. Gusceti; B: S. Aleksic-Kovacevic; C: M.A. Pires*  
Simultaneous tours: A: P35-P45; B: P86-P97 and C: P98-P110.

**15.30-16.30 Keynote Lecture 3: (Main Room: Paraninfo)**

*Chairperson: Ken Smith*

**Transboundary Animal Diseases: Pathology and Pathogenesis**

*Corrie Brown. USA*

**16.30 -17.00 Coffee break**

**16.30 - 17.00 Presentation of of the European Association of Veterinary Neuropathology (EAVN). (Aula 1A)**

**17.00 - 18.30 Poster viewing and guided tour presentation 3**

*Chairpersons: A: F. Nguyen; B: J.A. Navarro; C: L. Luján; D: I. Babinska*  
Simultaneous tours: A: P1-P14; B: P70-P85; C: P148-P163 and D: P176-P184.

**17.00 - 18.45 Oral presentations:**

Session 2 (Aula 3)

Wildlife and zoo animal pathology (O31-O37)

*Chairperson: A. Balseiro/E. Bollo*

**17.00 - 18.45 Seminar: Q&A Session (Aula 3)**

ECVP Exam Informative Session  
Andrea Groene. University of Utrecht

Koen Chiers. University of Gent

**O31- EARLY LESIONS IN NON-HUMAN PRIMATES FOLLOWING AEROSOL EXPOSURE TO MYCOBACTERIUM TUBERCULOSIS.**

*Rayner EL, Hall GA, Pearson GR, Dennis M, Sharpe S. United Kingdom.*

## PROGRAM

**O32- HISTOPATHOLOGICAL  
DETECTION OF SUBCLINICAL  
LEPTOSPIROSIS IN FREE-  
RANGING IBERIAN LYNXES  
(LYNX PARDINUS)**

*Jiménez MA, Sánchez B, Peña L.  
Spain.*

**O33- RESPIRATORY DISEASES  
IN CHAMOIS (*Rupicapra  
rupicapra*)**

*Scaglione FE, Gelmetti D,  
Grande D, Chiappino L, Sereno  
A, Ferroglio E, Bollo E. Italy.*

**O34- COMPARISON OF  
TEMPORAL AND SPATIAL  
DYNAMICS OF SEASONAL  
H3N2, PANDEMIC H1N1 AND  
HIGHLY PATHOGENIC AVIAN  
INFLUENZA H5N1 VIRUS  
INFECTIONS IN FERRETS**

*van den Brand J, Stittelaar K, van  
Amerongen G, Reperant L, de  
Waal L, Osterhaus A, Kuiken T.  
The Netherlands.*

**O35- NEW INSIGHTS ON  
THE IMPORTANCE OF  
RODENT POPULATION IN  
A ZOO ECOSYSTEM IN THE  
PATHOLOGY AND SPREAD OF  
CALODIUM HEPATICUM IN  
PRIMATES**

*Correia J, Crespo A, Noiva  
R, Pissarra H, Fernandes T,  
Bernardino R, Afonso F1, Lapão  
N, Vaz Y, Carvalho L, Peleteiro C.  
Portugal.*

**O36- ASYMMETRICAL  
CAMPOMELIC DYSPLASIA-  
LIKE SYNDROME IN A COLONY  
OF COMMON MARMOSETS  
(*CALLITHRIX JACCHUS*)**

*Bosseler L, Cornillie P, Saunders  
J, Bakker J, Langermans J,  
Casteleyn C, Decostere A, Chiers  
K. Belgium*

**18.30-19.30 ECVF annual Meeting  
(Paraninfo)**

**18.45 -19.45 SEAPV annual meeting  
(Aula 3)**

## Friday, 7th September 2012

**9.00 - 10.00 Keynote Lectures 4:** (Main Room: Paraninfo)  
*Chairperson: Anja Kipar*  
**Wildlife Disease Control in the 21st Century**  
Christian Gortázar. Spain.

**10.00 - 11.00 Oral presentations:**  
Session 3A (Paraninfo)  
Bird pathology (O23-O26)  
*Chairperson: N. Majó/A. Pospischil*

**O23- PATHOGENESIS AND TRANSMISSIBILITY OF HIGHLY AND LOW PATHOGENIC AVIAN INFLUENZA VIRUS INFECTION IN COMMON QUAIL (*Coturnix coturnix*)**

*Bertran K, Dolz R, Busquets N, Ramis A, Gamino V, Abad FX, Höfle U, Majó N. Spain.*

**O24- TISSUE TROPISM AND PATHOLOGY OF NATURAL INFLUENZA VIRUS INFECTION IN BLACK-HEADED GULLS (*Chroicocephalus ridibundus*)**

*Höfle U, van de Bildt, Leijten L, Verhagen JH, Fouchier RAM, Osterhaus A, Kuiken T. Spain.*

**O25- PATHOLOGIC AND IMMUNOHISTOCHEMICAL FINDINGS IN EYES OF FLAVIVIRUS INFECTED GAME BIRDS**

*Virginia G, Gutiérrez-Guzmán AV, Escribano-Romero E, Blázquez AB, Saiz JC, Höfle U. Spain.*

**11.00 - 11.30 Coffee break**

**10.00 - 11.00 Oral presentations:**  
Session 3B (Aula 3)  
Fish pathology (O27-O30)  
*Chairperson: H. Schmidt-Posthaus/J. Szarek*

**O27- PROLIFERATIVE KIDNEY DISEASE - AN EMERGING DISEASE INFLUENCED BY GLOBAL WARMING?**

*Schmidt-Posthaus H, Bettge K, Sattler U, Wahli T. Switzerland.*

**O28- NEW CONTRIBUTIONS TO THE STUDY OF ENTEROENDOCRINE SYSTEM IN TURBOT (*Psetta maxima*) FOLLOWING INFECTION WITH *Enteromyxum scophthalmi***

*Losada AP, Bermúdez R, Ronza P, Quiroga MI, Di Giancamillo A, Domeneghini C. Spain.*

**O29- RED MARK SYNDROME IN RAINBOW TROUT (*O. mykiss*) FARMED IN ITALY: ANATOMOHISTOPATHOLOGICAL INVESTIGATIONS.**

*Galeotti M, Volpatti D, Beraldo P, Brunetti B, Galletti E e Feist SW. Italy.*

**O30- EXPRESSION OF TNF-ALPHA IN TELEOST FISH: AN IMMUNOHISTOCHEMICAL STUDY**

*Ronza P, Losada AP, Coscelli GA, Failde LD, Sancho AR, de Azevedo AM, Bermúdez R, Quiroga MI. Spain.*

**11.00 - 12.00 Poster viewing and guided tour presentation 4.**

*Chairperson: A: G. Bettini; B: B.*

*Moreno; C: A. Espinosa*

Simultaneous tours: A: P26-P34;

B: P62-P69 and C: P121-P31.



## PROGRAM

- 12.00 - 13.00 Oral presentations:**  
Session 3A (Paraninfo)  
Infectious diseases: bacteria, mycoplasma (O19-O22)  
*Chairperson: P. Juntas/R. Lindberg*
- O19- NEW INSIGHTS INTO IMMUNOPATHOLOGICAL FORMS OF BOVINE PARATUBERCULOSIS**  
*Vázquez P, Garrido JM, Pérez V, Juste RA. Spain*
- O20- HISTOPATHOLOGICAL, IMMUNOHISTOCHEMICAL AND MOLECULAR STUDIES ON NATURALLY OCCURRING PARATUBERCULOSIS IN SHEEP**  
*Sonawane GG, Tripathi BN. India*
- O21- HISTOPATHOLOGICAL FINDINGS IN DOGS WITH "HAEMORRHAGIC GASTROENTERITIS".**  
*Leipig M, Busch K, Unterer S, Hermanns W. Germany.*
- O22- PREVALENCE AND RISK FACTOR ANALYSIS OF FELINE HAEMOPLASMA INFECTION IN NEW ZEALAND DOMESTIC CATS**  
*Dittmer KE, Jenkins KS, Kwan E, Marshall JC, Tasker S. New Zealand.*
- 13.00-14.15 Lunch**
- 14.15 - 15.30 Poster viewing and guided tour presentation 5:**  
*Chairperson: A: R. Feinstein; B: J. Pérez; C: E. Mozos*  
Simultaneous tours: A: P46-P50/P132-P135; B: P111-P120 and C: P164-P175.
- 15.30 -16.30 Keynote Lecture 5: (Main Room: Paraninfo)**  
*Chairperson: Paola Roccabianca*  
**What's new on the histopathology of canine mammary tumors?**  
*Laura Peña, Spain*
- 16.30 -17.00 Coffee break**
- 17.00 - 18.30 Oral presentations:**  
Session 4A (Paraninfo)  
Neuropathology (O38-O43)  
*Chairperson: K. Matiassek/M. Pumarola*
- 12.00 - 13.00 Oral presentations:**  
Session 3B (Aula 3)  
Discussion Cases Presentation (C1-C5)  
*Chairperson: S. Callanan/A. Gruber*
- C1- SPLENIC MASS IN A DOG**  
*García-Quirós, A., Penadés, M., Viana, D., Ortega, J. Spain*
- C2- MULTIPLE RAPIDLY PROGRESSING CUTANEOUS NODULES IN A BOXER DOG BUT NO MAST CELL TUMOR?**  
*Plog S, Gruber Achim D, Linek M*
- C3- "EPIDERMAL PROLIFERATIVE DISORDER" IN A FERRET (Mustela putorius furo)**  
*Penadés, M., García-Quirós, A. Zuriaga, E., Ortega, J. Spain*
- C4- DERMATITIS IN SHEEP: WHAT IS YOUR DIAGNOSIS?**  
*Zafra R, Bautista MJ, Pérez EM, Oliver F, Pacheco IL, Escamilla, Acosta I, Pérez J. Spain*
- C5- CASES OF NERVOUS CLINICAL SIGNS IN A GOAT HERD**  
*Polledo L, Iglesias MJ, Ferrero C, Gonzalez J, Perez-Martinez C, Garcia-Marin JF. Spain*
- 14.15 - 15.30 International Veterinary Pathology Coalition Meeting (ECVP - ACVP).**  
(Aula 3)

**O38- POSSIBLE ROLE OF PERIVASCULAR LESIONAL TYPES IN THE NEUROPATHOGENESIS OF VISNA/MAEDI ENCEPHALITIS LESIONS.**

*Polledo L, González J, Benavides J, Martínez-Fernández B, Pérez V, Ferreras MC, García Marín JF. Spain.*

**O39- SHATTERING THE MYTH OF RABBIT RESISTANCE TO PRION INFECTION.**

*Chianini F, Fernández-Borges N, Vidal E, Pintado B, Hamilton S, Eaton SL, Finlayson J, Pang Y, Dagleish MP, Castilla J. Scotland (UK)*

**O40- GENE AND PROTEIN PATTERNS OF SIX SCRAPIE RELATED MARKERS IN THE CNS OF NATURALLY INFECTED SHEEP**

*Filali H, Vidal E, Bolea R, Márquez M, Marco P, Vargas A, Pumarola Mí, Martin-Burriel I, Badiola JJ. Spain.*

**O41- A PORCINE MODEL OF HAEMATogenous BRAIN INFECTION WITH STAPHYLOCOCCUS AUREUS**

*Astrup L, Agerholm J, Nielsen O, Jensen H, Leifsson Pl, Iburg T. Denmark.*

**O42- TOXICOPATHOLOGICAL CHARACTERIZATION OF GOAT AS ANIMAL MODEL OF BOVINE CEREBELLAR CORTICAL DEGENERATION INDUCED BY *Solanum bonariense*.**

*Verdes JM, Dehl V, Borteiro C1, Dura L, Gimeno EJ, Guidi MG, Guerrero F, Fidalgo LE, Moraña A. Uruguay.*

**O43- SPONGY DEGENERATION OF THE CEREBELLAR NUCLEI WITH ATAXIA IN MALINOIS PUPPIES**

*Högler S, Kleiter M, Leschnik M, Kneissl S, Url A. Austria.*

**O7- IS BAG3 PROTEIN INVOLVED IN AUTOPHAGIC MECHANISMS IN PAPILLOMAVIRUS-ASSOCIATED UROTHELIAL TUMORS IN CATTLE?**

*Roperto S, Paciello O, Borzacchiello G, Esposito I, Riccardi M, Lucà R, Urraro C, Ceccarelli DM, Russo V, Roperto F. Italy.*

**O8- A COMPREHENSIVE PATHOLOGICAL STUDY ON BOVINE ADRENAL GLAND TUMOURS.**

*Capucchio MT, Biasibetti E, Deideri F., Rocha PRD, Giorcelli J, Bianco P,Valenza F,Guarda F, Volante M.Italy.*

**O9- CANINE DIGIT SQUAMOUS CELL CARCINOMA: epidemiological, histological and immunohistochemical study.**

*Belluco S, Brisebard E, Watrelot D, Marchal T, Ponce F. France.*

**O10- IMMUNOHISTOCHEMICAL DETECTION OF THE BCL-2 FAMILY MEMBERS BAK AND BAX IN CANINE LYMPHOMA**

*Croci M, Guscelli F. Switzerland.*

**O11- MACROPHAGES AND T CELLS INFILTRATION IN FELINE ENDOMETRIAL ADENOCARCINOMAS**

*Tavares Pereira M, Payan-Carreira R, Saraiva AL, Pires MA. Portugal.*

**O12- ASSAY OF STANDARDIZATION FOR IMMUNOHISTOCHEMICAL COX-2 STAINING**

*Belluco S, Castagnaro M, Carnier P, Chiers K, Millanta F, Peña L, Queiroga F, Pires I, Riffard S, Scase T, Polton G. France.*

## Saturday, 8th September 2012

**10.00 - 11.00 Keynote Lectures 6:** (Main Room: Paraninfo)

*Chairperson: Juan Badiola*

**Intestinal inflammatory disease in animals and humans as a slow infection.**  
Ramón A. Juste. Spain

**11.00 - 12.00 Oral presentations:**

Session 5A (Paraninfo)  
Digestive tract pathology  
(O44-O47)

*Chairperson: C. Hard af Segerstad/H. Posthaus*

**O44- CHARACTERIZATION OF THE IMMUNE CELL INFILTRATE IN THE INTESTINE OF HORSES WITH INFLAMMATORY BOWEL DISEASE**

*Olofsson K, Press C, Lindberg R. Norway.*

**O45- EFFECT OF COATED CALCIUM BUTYRATE ON SOY PROTEIN CONCENTRATE ASSOCIATED INTESTINAL DAMAGE IN CALVES**

*Wegge B, Saey V, Ducatelle R, Chiers K. Belgium*

**O46- INTESTINAL ADENOCARCINOMA IN A HERD OF FARMED SIKA DEER (CERVUS NIPPON). A NOVEL SYNDROME.**

*Kelly P, Toolan D, Jahns H. Ireland.*

**O47- INTESTINAL LEIOMYOSITIS AND CHRONIC INTESTINAL PSEUDO-OBSTRUCTION IN A BICHON MALTESE DOG.**

*Galindo-Cardiel I, Soto S, Lloret A, Marco A. Spain.*

**11.00 - 12.00 Oral presentations:**

Session 5B (Aula 3)  
Miscellanea  
(O48-O51)

*Chairperson: M. Hewicker-Trautwein/A. Méndez*

**O48- SLIMMING SYNDROME IN SHEEP. FROM VACCINE ADVERSE REACTION TO SEVERE ANAEMIA AND SKINNY ANIMALS**

*Acín C, Bolea R, Marín B, Fernández de Luco D, García L, Garza M, Sarasa R, Pitarch JL, Hedman C, Vargas A, Badiola JJ. Spain.*

**O49- ULTRASTRUCTURAL MITOCHONDRIAL ALTERATIONS IN EQUINE MYOPATHIES OF UNKNOWN ORIGIN**

*Van Driessche K, Ducatelle R, Chiers K, Van Coster R, van der Kolk H. Belgium.*

**O50- FOCUS ON HEART AND KIDNEY PATHOLOGY IN DIFFERENT COMBINATIONS OF FcγR-DEFICIENT MICE**

*Salvatori D, Bergmann W, Grinwis G, Verbeek JS. The Netherlands*

**O51- ASSESSMENT OF COLONY FORMING CAPACITY OF THE CANINE HAIR FOLLICLE UNDER TWO DIFFERENT CULTURE CONDITIONS**

*Wiener DJ, Suter M, Welle MM. Switzerland.*

**12.00 - 12.30 Coffee break ("Brunch")**

**12.30 Closing of Congress**

**12.30 Postconference tour**

## Poster viewing and guided tours presentation.

### Session 1. Thursday, 6<sup>th</sup>, 10.45-11.30

- A- Tumours in dogs and cats. Nº posters: P15 – P25  
 Chairperson : J. Ortega
- B- Infectious diseases, virus, prions. Nº posters: P51 – P61  
 Chairperson : M. Aleksandersen
- C- Toxicopathology. Nº posters: P136 – P147  
 Chairperson : B. Biolatti

### Session 2. Thursday, 6<sup>th</sup>, 14.15-15.30

- A- Tumours in equine and ruminants Nº posters: P35 – P45  
 Chairperson : F: Gusceti
- B- Infectious diseases: bacteria, parasites. Nº posters: P86 – P97  
 Chairperson : S. Aleksic-Kovacevic
- C- Wildlife and zoo animal pathology (infectious diseases: virus, mycobacteria). Nº posters: P 98 – P110  
 Chairperson : M.A. Pires

### Session 3. Thursday, 6<sup>th</sup>, 17.00-18.30

- A- Mammary tumours: canine and feline. Nº posters: P1 – P14  
 Chairperson : F. Nguyen
- B- Infectious diseases: mycoplasma, bacteria. Nº posters: P70 – P85  
 Chairperson : J.A. Navarro
- C- Naturally occurring and experimentally induced pathology in different organs and tissues: genetic, nervous system and skeletal pathology. Nº posters: P148 – P163  
 Chairperson : L. Luján
- D- Diagnostic methods. Nº posters: P176 – P184  
 Chairperson : I. Babinska

**Session 4. Friday, 7<sup>th</sup>, 11.00-12.00**

- A- Tumours in canine and feline. Nº posters: P26 – P34  
Chairperson : G. Bettini
- B- Infectious diseases, virus 2<sup>nd</sup>. Nº posters: P62 – P69  
Chairperson : B. Moreno
- C- Wildlife and zoo animals pathology. Nº posters: P121 – P131  
Chairperson : A. Espinosa de los Monteros

**Session 5. Friday, 7<sup>th</sup>, 14.15-15.30**

- A- Tumours in laboratory and others animal species. Nº posters: P46 – P50  
Fish pathology. Nº posters: P132 – P135  
Chairperson : R. Feinstein
- B- Wildlife and zoo animal pathology (infectious diseases: bacteria, parasites). Nº posters: P 111 – P120  
Chairperson : J. Pérez
- C- Naturally occurring and experimentally induced pathology in different organs and tissues: skin, cardiovascular, endocrine, reproductive pathology and others. Nº posters: P164 – P175  
Chairperson : E. Mozos

**Mammary tumours: canine and feline**

**P1- INSULIN-LIKE GROWTH FACTOR-1 RECEPTOR (IGF-1R) EXPRESSION CORRELATES WITH PROGNOSIS IN DOGS WITH MAMMARY CARCINOMA**

*Nguyen Frédérique, Godard Tiffanie, Jaillardon Laëtizia, Morio Floriane, Ibisch Catherine, Abadie Jérôme, Siliart Brigitte. France.*

**P2- DETECTION OF PROGESTERONE RECEPTOR BY qPCR ANALYSIS FROM FORMALIN-FIXED PARAFFIN EMBEDDED CANINE MAMMARY TISSUES**

*Guil-Luna S, Stenvang J, Brünner N, Sánchez-Céspedes R, Millán Y, Gómez-Laguna J, Martín de las Mulas J. Spain.*

**P3- ALTERED P120 CTN EXPRESSION IN CANINE MAMMARY CARCINOMAS IS ASSOCIATED WITH POOR SURVIVAL**

*Pereira D, Alves A, Paredes J, Schmitt F, Gama A. Portugal.*

**P4- IMMUNOHISTOCHEMICAL STUDY OF TRANSFORMING GROWTH FACTOR BETA-1 (TGF BETA-1) EXPRESSION IN CANINE MAMMARY GLAND TUMORS**

*Movassaghi Ahmad Reza, Rezaee-Oghazi Massoud, Maleki Mohsen. Iran.*

**P5- IMMUNOHISTOCHEMICAL EXPRESSION OF RANK (RECEPTOR ACTIVATOR OF NUCLEAR FACTOR KAPPA B) IN CANINE MAMMARY CARCINOMAS**

*Guil-Luna S, Sánchez-Céspedes R, Millán Y, Martín de las Mulas J. Spain*

**P6- HISTOPATHOLOGICAL AND IMMUNOHISTOCHEMICAL STUDY OF CANINE MAMMARY SARCOMAS**

*Dolka I, Sapiernyński R, Król M. Poland.*

**P7- HEPCIDIN EXPRESSION IN CANINE AND FELINE MAMMARY TUMORS**

*Marques O, Canadas A, Rêma A, Faria F, Simão J, Gärtner F, Martins da Silva B, Porto G and Lopes C. Portugal.*

**P8- IMMUNOHISTOCHEMICAL EXPRESSION OF MATRIX METALLOPROTEINASE 2 (MMP-2) IN FELINE FIBROADENOMATOUS CHANGE**

*Millán Yolanda, De Maria Raffaella, Maniscalco Lorella, Iussich Selina, Sánchez-Céspedes Raquel, Guil-Luna Silvia, Martín de las Mulas Juana. Spain.*

**P9- CYCLOOXYGENASE-2 EXPRESSION IN FELINE MAMMARY CARCINOMAS AND ADJACENT MAMMARY GLAND**

*Seixas F, Silva S, Pires MA, Lopes C. Portugal.*

**P10- MOLECULAR CLASSIFICATION OF PRIMARY MAMMARY TUMORS AND METASTASIS IN CAT**

*Soares, M., Correia J., Murta A., Carvalho S., Ferreira F. Portugal.*

**P11- AN ANAPLASTIC MAMMARY CARCINOMA IN A CAT**

*Soares M., Correia J., Ferreira A., Ferreira F. Portugal*

## POSTERS LIST

### **P12- A MALE CAT SQUAMOUS CELL MAMMARY CARCINOMA**

*Soares M., Correia J., Bom R., Carvalho S., Ferreira F. Portugal*

### **P13- A METASTATIC LIPID-RICH CARCINOMA OF THE MAMMARY GLAND IN A CAT**

*Gal AF, Tăbăran F, Taulescu M, Bolfă P, Cătoi C. Romania*

### **P14 - IMMUNOHISTOCHEMICAL EVALUATION OF Ki-67, MMP-9 AND CD3+ LYMPHOCYTES IN FELINE BREAST CANCER – CORRELATION WITH CLASSIFICATION STANDARDS**

*Machado GF, Schweigert A, Melo GD, Picciuto R. Brazil.*

## Tumours in canine and feline

### **P15- DOG'S NEOPLASIA IN PORTUGAL- A THREE YEARS DESCRIPTIVE STUDY**

*Santos S, Castel-Branco M, Faisca P. Portugal.*

### **P16- CARDIAC VALVE MYXOSARCOMA WITH THROMBOSIS OF THE RIGHT CORONARY ARTERY IN A DOG**

*Karlstam Erika, Bernodt Karin and Hård af Segerstad Carl. Sweden*

### **P17- GLOMUS TUMOR IN THE CARPUS OF A DOG**

*Ortega J, Sanchis F, Rosell J, Bolta D, Clemente F, Barragan A y Viana D. Spain.*

### **P18- CO-OCCURRENCE OF HEMANGIOPERICYTOMA AND HEMANGIOSARCOMA IN A DOG**

*Sabbagh A, Tavasoli A, Rostami A, Tamimi N, Dehghan M.M. Iran*

### **P19- GASTRIC HELICOBACTERIOSE AND EARLY GASTRIC CARCINOMA IN DOG: COINCIDENCE OR CONSEQUENCE?**

*Romero, D.C. Brazil*

### **P20- VISCERAL MAST CELL TUMOUR WITH HEPATOCELLULAR EMPERIPOLESI IN A YORKSHIRE TERRIER**

*Cuesta-Garcia Nerea, Lamm Catherine. United Kingdom*

### **P21- MAST CELLS AND THEIR RELATIONSHIP TO ANGIOGENESIS AND PROGNOSIS IN CANINE MELANOCYTIC TUMORS**

*Cuitiño M1, Guido N, Massone A, Idiart J. Argentina.*

### **P22- EIGHTEEN MONTHS FOLLOW UP OF CASES OF MELANOMA VACCINATION – TUMORS FENOTYPE AND POST VACCINATION INFLAMMATORY REACTION**

*Henriques Joaquim, Felisberto Ricardo, Faisca Pedro, Araújo Manuela, Carvalho Tania, Peleteiro Maria. Portugal.*

### **P23- DYSEMBRYOPLASTIC NEUROEPITHELIAL TUMOR IN A FRENCH BULLDOG**

*Bacci Barbara, Bowman Chloe, Long Sam. Australia.*

## POSTERS LIST

### **P24.- FELINE CUTANEOUS NERVE SHEATH TUMOURS (CNSTS): HISTOLOGICAL FEATURES AND IMMUNOHISTOCHEMICAL EVALUATIONS**

*Mandara Maria Teresa, Fabriani Eleonora, Pavone Silvia, Pumarola Martì. Italy.*

### **P25- NEUROENDOCRINE CARCINOMA IN THE NASAL CAVITY OF A CAT**

*Resende Luís, Pereira Hugo, Godinho Ana, Carvalho Inês, Melo Marta, Anagua Marly, Faisca Pedro. Portugal.*

### **P26- CANINE SEMINOMAS – DIFFERENTIATION INTO CLASSICAL AND SPERMATOCYTICAL SEMINOMAS**

*Hohšteter M, Artuković B, Ćorić M, Severin K, Gudan Kurilj A, Beck A, Sabočanec R, Šoštarčić-Zuckermann IC, Grabarević Ž. Croatia.*

### **P27- A CASE OF SCROTAL LEIOMYOSARCOMA IN A DOG**

*Laloy Eve, Chateau-Joubert Sophie, El Mrini Meryem, Rakotovao Faraso, Carlus Marine, Reyes-Gomez Edouard, Delfosse Vincent, Cordonnier Nathalie. France.*

### **P28- MESOTELIOMAS OF THE TUNICA VAGINALIS TESTIS IN THE DOG: AN UNCOMMON NEOPLASM WITH MALIGNANT BEHAVIOUR**

*Ramírez GA, Suárez-Bonnet A, Espinosa-de-los-Monteros A, Altimira J, Vilafranca M. Spain.*

### **P29- ENDOMETRIAL ADENOCARCINOMA IN A CAT WITH ABDOMINAL METASTASIS – CASE REPORT**

*Pires MA, Saraiva AL, Vilhena H, Miranda S, Fonseca I, Moreira P, Alves AM, Paiva R, Payan-Carreira R. Portugal.*

### **P29 bis- IMMUNOHISTOCHEMICAL EXPRESSION OF CYCLOOXYGENASE-2 (COX-2) IN FELINE ENDOMETRIAL ADENOCARCINOMAS: A PRELIMINARY STUDY**

*Saraiva AL, Gärtner F, Payan-Carreira R, Rema A, Lourenço LM, Pires MA. Portugal*

### **P30- EXPRESSION OF CELL CYCLE REGULATORS, 14-3-3 $\sigma$ AND P53 PROTEINS, AND VIMENTIN IN CANINE TRANSITIONAL CELL CARCINOMA OF THE URINARY BLADDER**

*Suárez-Bonnet A, Herráez P, Quesada O, Andrada M, Jaber R, Espinosa de los Monteros A. Spain.*

### **P31- SALIVARY GLAND CARCINOSARCOMA IN A DOG**

*Osińska Barbara, Dolka Izabella. Poland.*

### **P32- ASSESSMENT OF EGFR AND HER-2 EXPRESSION AND KRAS-STATUS IN CANINE GASTRIC TUMORS**

*Bettini G, Casadei Gardini A, Terragni R, Capelli L, Morini M, Sabattini S, Vignoli M, Saunders JH, Ulivi. Italy.*

### **P33- ASSESSING INTERACTIONS BETWEEN CANINE BCL-2 FAMILY PROTEINS IN YEAST (*Saccharomyces cerevisiae*)**

*de Brot S, Guscetti F. Switzerland.*

### **P34- PATHOLOGY AND CLINICAL DATA INTEGRATED IN ARTIFICIAL NEURAL NETWORKS FOR PROVIDING PROGNOSTIC IN CANCER**

*Gaita L, Militaru M. Romania.*



**Tumours in equine and ruminants**

**P35- PATHOLOGIC AND IMMUNOHISTOCHEMICAL FEATURES OF A TUBULOPAPILLARY CARCINOMA IN A MARE**

*Perez-Ecija A, Mendoza F, Estepa José. Spain.*

**P36- VERRUCOUS HEMANGIOMA WITH PSEUDOCARCINOMATOUS EPIDERMAL HYPERPLASIA IN A HORSE**

*Perez-Ecija Alejandro, Estepa Jose, Barranco Inmaculada, Rodriguez-Gomez Irene, Mendoza Francisco, Gomez-Laguna Jaime. Spain.*

**P37- CONGENITAL ASCITES DUE TO HEPATOBLASTOMA WITH EXTENSIVE PERITONEAL IMPLANTATION METASTASES IN A PREMATURE EQUIN FETUS**

*de Vries C, Rocha PRD, Vanhaesebrouck E, Govaere J, Hoogewijs M, Bosseler L, Chiers K, Ducatelle R, Belgium.*

**P38- TELOMERASE ACTIVITY AND TELOMERE LENGTH IN CATTLE INFECTED WITH BOVINE LEUKEMIA VIRUS (BLV)**

*Szczotka M., Kuzmak J.Poland.*

**P39- MORPHOPATHOLOGICAL STUDY OF NATURALLY OCCURRING VULVAR AND VAGINAL SQUAMOUS CELL CARCINOMA IN CATTLE**

*Motaghypisheh M, Shirian S. Iran.*

**P40- ASSOCIATION OF BPV-2 INFECTION AND BOVINE URINARY BLADDER TUMORS FROM NORTH CENTRAL REGION OF ROMANIA**

*Taulescu Marian, Valentin Balteanu, Gal Adrian, Bolfă Pompei, Laura Farcas, Gabi Borza, Andras Nagy, Flaviu Tabaran, Bogdan Sevastre, Cătoi Cornel. Romania.*

**P41- RUMINAL LEIOMYOSARCOMA AND NATURALLY OCCURRING *Calicophoron daubneyi* INFECTION IN A COW**

*Ferreras M C, Pérez V, González-Lanza M C, Benavides J, Mezo M, Fuertes M, González-Warleta M, Delgado L, Martínez-Ibeas A, Manga-González M Y. Spain.*

**P42- COEXISTENCE OF SEVERAL PRIMARY TUMORS IN AN ADULT GOAT**

*Moreno B, Jirón, W, Marcuello P, Badiola JJ, Marín B. Spain.*

**P43- PRECISION CUT LUNG SLICES TO STUDY THE PATHOGENESIS OF OVINE PULMONARY ADENOCARCINOMA**

*Alleaume Charline, Dagleish Mark, Cousens Chris. Francia.*

**P44- PATHOLOGICAL AND AETIOLOGICAL STUDIES IN SHEEP EXHIBITING EXTRA-THORACIC METASTASIS OF OVINE PULMONARY ADENOCARCINOMA (JAAGSIEKTE)**

*Minguijón E, González L, De Las Heras M, Gómez N, García-Goti M, Juste RA, Moreno B. Spain.*

**P45- OCURRENCE OF PAPILLARY ADENOCARCINOMA OF ETHMOID OLFATORY MUCOSA IN SHEEP**

*Tavasoly Abbas, Taghipour-bazargani Taghi, Kamyabi-moghaddam Zahra, Bagheri Farnoosh. Iran.*

**Tumours in laboratory and other animal species**

**P46- SPONTANEOUS TUMOURS OBSERVED IN CYNOMOLGUS MONKEYS**

*J.Kaspereit, S.Friderichs-Gromoll, E.Buse, G. Habermann. Germany.*

**P47- ROLE OF LKB1 AND BRAF IN UV INDUCED MELANOMAS IN MICE**

*Suarez C, Martin-Caballero J, Recio JA and Flores JM. Spain.*

**P48- COOPERATION BETWEEN P21 cip1/waf1 AND P27 KIP2 IN CELLULAR SENESCENCE IN TUMORS**

*García-Fernández RA, García-Palencia P, Suárez C, Sánchez MA, Sánchez B, Martín-Caballero J y Flores JM. Spain.*

**P49- B CATHENIN IN MICE: EXPRESSION IN NORMAL UROTHELIUM AND IN CHEMICALLY INDUCED PRE-NEOPLASTIC AND NEOPLASTIC LESIONS**

*Vasconcelos-Nóbrega C, Costa C, Vala H, Colaço A, Santos L, Lopes C, Oliveira PA. Portugal.*

**P50- HEPATOCELLULAR ADENOCARCINOMA IN A RACING PIGEON – CASE REPORT**

*Szweda M, Babińska I, Paździor K1, Gesek M1. Poland.*

**Infectious diseases: virus, prions**

**P51- SUSCEPTIBILITY TO SCRAPIE AND DISEASE PHENOTYPE IN SHEEP: CROSS-Prnp GENOTYPE TRANSMISSIONS WITH NATURAL SOURCES**

*González L, Jeffrey M, Dagleish MP, Chianini F. United Kingdom.*

**P52- THE PATHOGENESIS AND DISEASE PHENOTYPE OF SCRAPIE IS NOT AFFECTED BY THE DOSE OR ROUTE OF INOCULATION**

*Pitarch JL, Jeffrey M, Thurson L, Martin S, Acín C, González L. United Kingdom.*

**P53- DETECTION OF PrP<sup>Sc</sup> IN SKIN OF NATURAL SCRAPIE INFECTED SHEEP**

*Garza MC, Acín C., Monzón M., Bolea R., Badiola J.J., Monleón, E. Spain*

**P54- EXPERIMENTAL SHEEP-BOVINE SPONGIFORM ENCEPHALOPATHY IN PIGS**

*Hedman Carlos, Marín Belén, Corbière Fabien, Filali Hicham, Márquez Merce, Vidal Enric, Vázquez Francisco, Romero Antonio, Pitarch José L., Garza Ma Carmen, Sarasa Rocío, Acín Cistina, Monzón Marta, Pumarola Martí, Badiola Juan J, Andreoletti Olivier, Bolea Rosa. Spain.*

**P54 bis- A POSSIBLE ROLE OF P-GLYCOPROTEIN IN BSE**

*Van der Heyden S, Wegge B, Dobby A, Ducatelle R, Roels S. Belgium*

**P55- VISNA/MAEDI: AN EXPERIMENTAL STUDY ON THE DISTRIBUTION OF TWO VIRAL STRAINS WITH MARKED TISSUE TROPISM USING THE BONE MARROW ROUTE**

*Pinczowski P, San José L, Gimeno M, Pérez M, Insausti N, de Andrés D, Badiola JJ, Amorena B, Reina R, Luján L. Spain.*

## POSTERS LIST

**P56- MEDULLAR VISNA BY 697 STRAIN IN SHEEP: WIDER DISTRIBUTION THAN PREVIOUSLY THOUGHT**

*Pinczowski P, Gimeno M, Pérez M, Insausti N, Moreno B, San José L, Badiola JJ, de Andrés D, Amorena B, Reina R, Luján L. Spain.*

**P57- EQUINE MULTINODULAR PULMONARY FIBROSIS: THE ROLE OF EHV-5 IN THE PATHOGENESIS OF AN EMERGING DISEASE**

*Leeming Gail, Kipar Anja, Hartley Catherine, Malbon Alexandra, Hetzel Udo, Stewart James P. United Kingdom.*

**P58- EQUINE HERPESVIRUS INFECTION IN A FOAL WITH BRONCHOINTERSTITIAL PNEUMONIA**

*Perez-Ecija Alejandro, Mendoza Francisco, Estepa José, Zafra Rafael, Bautista M<sup>a</sup> Jose, Perez José. Spain.*

**P59- INTERSTITIAL PNEUMONIA IN HORSES INFECTED WITH EQUINE INFECTIOUS ANEMIA VIRUS**

*Bolfa P, Cadore JL, Nolf M, Catoi C, Vidrighinescu R, Taulescu M, Nagy A, Tabaran F, Farcas L, Leroux C. Romania.*

**P60- BORNA DISEASE VIRUS INFECTION OF TNF-TRANSGENIC NEURONAL CULTURES PROMOTES ASTROGLIAL PROLIFERATION**

*Melo GD, Brachthäuser L, Ahlemeyer B, Baumgart-Vogt B, Herden C. Germany.*

**P61- DIFFERENTIAL EXPRESSION OF CITOKINES IN OVINE LUNG IN RESPONSE TO EXPERIMENTAL BOVINE RESPIRATORY SYNCYTIAL VIRUS**

*García A, Masot J, Gázquez A, Redondo E. Spain.*

**P62- SPONTANEOUS NECROTIZING BRONCHOPNEUMONIA IN THREE YOUNG PIGS POSSIBLY CAUSED BY A(H1N1)pdm09**

*Kinji Shirota, Akiko Sakuma. Japan.*

**P63- DIFFERENTIAL EXPRESSION OF CLEAVED CASPASE-3 AND TUNEL IN LUNG AND LYMPHOID ORGANS OF PRRSV INFECTED PIGS**

*Barranco I, Gómez-Laguna J, Rodríguez-Gómez IM, Pallarés FJ, Ramis G, García-Nicolás O, Salguero FJ, Carrasco L. Spain.*

**P64- IL-10 TRANSCRIPTIONAL AND PROTEIN EXPRESSION IN LUNGS OF PORCINE REPRODUCTIVE AND RESPIRATORY SYNDROME VIRUS (PRRSV) INFECTED PIGS**

*García-Nicolás O, Quereda JJ, Gómez-Laguna J, Barranco I, Ramis G, Pallarés FJ, Carrasco L. Spain.*

**P65- TYPE 2 PRRSV INFECTION MEDIATED APOPTOSIS IN B- AND T-CELL AREAS IN LYMPHOID ORGANS**

*Gómez-Laguna J, Salguero FJ, Fernández de Marco M, Barranco I, Rodríguez-Gómez IM, Quereda JJ, Quezada M, Carrasco L. Spain.*

**P66- PORCINE CIRCOVIRUS TYPE 2 (PCV2) IN CASES OF DIARRHOEA IN PIGS**

*Anna Szczotka, Zygmunt Pejsak. Poland.*

## POSTERS LIST

### **P67- AN OUTBREAK OF CONGENITAL POXVIRUS INFECTION IN A COMMERCIAL BREEDING PIG HERD**

*Cardona S, De Martino A, Urrea M, Jeffrey M, De las Heras M. Spain.*

### **P68- HSP 70 MEDIATED INNATE IMMUNITY IN THE BRAIN OF MICE INFECTED WITH VESICULAR STOMATITIS VIRUS**

*Rocha PRD, Kim MY, Capucchio MT, Shu Y, Oglesbee M2. Italy.*

### **P69- ROLES OF UBIQUITIN AND HEAT SHOCK PROTEIN 70 IN FORMATION OF NEGRI'S BODY LIKE STRUCTURE IN VITRO.**

*Sakai Y, Sunden Y, Umemura T. Japan.*

## **Infectious diseases: mycoplasma, bacteria and parasites**

### **P70- COMPARISON OF ELISA ANALYSIS FROM SERUM AND LUNG EXTRACT SAMPLES OF PIGS NATURALLY INFECTED WITH MYCOPLASMA HYPNEUMONIAE**

*Díaz J, Paz Y, Quesada-Canales O, Rivero MA, Saavedra P, Fernández A, Andrada M. Spain.*

### **P71- QUANTIFICATION AND LOCALIZATION WITHIN THE BRONCHIAL TREE OF LESIONS INDUCED BY MYCOPLASMA HYOPNEUMONIAE IN NATURALLY INFECTED PIGS**

*Ramírez T, Gil V, Quesada-Canales O, Paz Y, Sierra E, Rodríguez F, Andrada M. Spain.*

### **P72- A MODEL OF INTRATRACHEAL INOCULATION FOR TESTING VACCINES AGAINST CHLAMYDIA ABORTUS IN SHEEPS**

*JA Navarro; MR Caro; N Ortega; AJ Buendía; MC Gallego; L Del Rio; F Cuello; A Murcia; D Alvarez; J Sanchez; J Salinas. Spain.*

### **P73- OVEREXPRESSION OF IL-10 IN TRANSGENIC MICE INCREASE MULTIPLICATION OF CHLAMYDIA ABORTUS**

*AJ Buendía; JA Navarro; MR Caro; N Ortega; MC Gallego; L Del Rio; F Cuello; A Murcia, J Sánchez; J Salinas. Spain.*

### **P74- NEUTROPHILS ARE THE PRIMARY SOURCE OF IFN- $\gamma$ IN LISTERIC RHOMBENCEPHALITIS OF RUMINANTS**

*Ahmed Y., Guldemann C., Zurbriggen A., Vandeveld M., Janda J., Oevermann A. Switzerland.*

### **P75- BEHAVIOUR OF TWO STREPTOCOCCUS SUIS SEROTYPE 2 FIELD STRAINS IN AN ACUTE EXPERIMENTAL INFECTION IN PIGS**

*Gómez-Gascón L, Gómez-Laguna J, Luque I, Amarilla P, Cardoso F, Carrasco L, Tarradas C. Spain.*

### **P76- CHARACTERIZATION OF ACUTE MAMMARY GLAND LESIONS ASSOCIATED WITH DIFFERENT *Staphylococcus aureus* STRAINS**

*Guerrero I., Viana D., Selva L., Ferrián S., Penadés M., García-Quirós A., Corpa J.M. Spain.*

### **P77- ENDOCARDITIS IN FOUR WEEKS-OLD BROILERS DUE TO ENTEROCOCCUS SPP**

*Andrés S, Bolea R, Chirino M, Vargas A, Marín B, Badiola JJ, Moreno B. Spain.*

## POSTERS LIST

**P78- RELATIONSHIP BETWEEN HISTOPATHOLOGICAL FINDINGS AND SALMONELLA SPECIES, TESTED BY BACTERIAL CULTURE, SEROTYPING AND PCR METHODS IN CATTLE**

*Sasani.F.; Zahedi. M.M ; Musakhani.F ; Zafari.M ; Bashiri.S. Iran.*

**P79- PROLIFERATIVE PLEURITIS CAUSED BY ACTINOMYCES HORDEOVULNERIS ASSOCIATED WITH LEUKEMIA IN A DOG**

*Gimeno M, Pinczowski P, Pérez M, Insausti N, Aceña C, Cortabarría N, Atxaerandio R, de Martino A, Aduriz G, Luján L. Spain.*

**P80- HISTOPATHOLOGICAL CLASSIFICATION OF THE DIFFERENT STAGES OF LYMPH NODE GRANULOMAS FROM PPD POSITIVE GOATS**

*Pérez M, Quesada-Canales O, Paz Y, Vigo V, Arbelo M, Espinosa de los Monteros A, Andrada M, .Spain.*

**P81- COMPARATIVE STUDY ON CROHN'S DISEASE & JOHNE'S DISEASE IN IRAN: HISTOPATHOLOGICAL FINDINGS AND NESTED-PCR**

*Moayer Fariborz , Seyed Farshi A. , Roudgari R. Iran.*

**P82- CYTOKINE AND INFLAMMATORY MEDIATORS EXPRESSION IN INTESTINAL TISSUES OF LAMBS SHOWING DIFFERENT TYPES OF LESIONS IN EXPERIMENTAL PARATUBERCULOSIS**

*Delgado L, Guilloteau LA, Foret B, Ferreras MC, García Marín JF, Pérez V. Spain.*

**P83- LESIONAL AND IMMUNE RESPONSE IN THE EARLY STAGES OF AN EXPERIMENTAL INFECTION OF LAMBS WITH DIFFERENT STRAINS OF *Mycobacterium avium* subspecies paratuberculosis**

*Fernández M, Sevilla I, Benavides J, Fuertes M, Morales S, Delgado L, Garrido JM, García Marín JF, Ferreras MC, Pérez V: Spain.*

**P84- MYCOBACTERIUM BOVIS INFECTION IN A DONKEY**

*Bryan J, den Boon P, McGuirk J, Madigan G, Fogarty U. Ireland.*

**P85- HISTOPATHOLOGICAL AND BACTERIOLOGICAL INVESTIGATION OF RESPIRATORY LESIONS IN SLAUGHTERED DROMEDARY CAMELS IN IRAN**

*Tavasoly Abbas, Bagheri Farnoosh, Kamyabi-moghaddam Zahra, Akbarinejad Vahid, Shojaei Mohammad, Kazempoor Reza. Iran.*

**P86- THE USE OF PATHOLOGICAL METHODS IN THE DIAGNOSIS OF OVINE ABORTIONS**

*Fernández M, Ferreras MC, González, J, Pérez, C, García-Iglesias, MJ, Pérez V, García Marín JF. Spain.*

**P87- CELLULAR IMMUNE RESPONSE IN WATER BUFFALO PLACENTAS AFTER INOCULATION WITH NEOSPORA CANINUM DURING EARLY GESTATION**

*Cantón Germán, Konrad José, Caspe Gastón, Moore Prando, Campero Carlos, Chianini Francesca. Scotland (UK).*

**P88- OUTBREAK OF BESNOITIOSIS IN DONKEYS (*Equus asinus*) IN THE SOUTH OF SPAIN**

*Zafra R, Soria-López N, Díez de Castro E, Jaber JR, Mozos E, Pérez J.. Spain.*

## POSTERS LIST

**P89- CANINE LEISHMANIASIS IN THE CENTRAL AND PERIPHERAL NERVOUS SYSTEMS**

*Márquez Merce, Pedregosa Jose-Raúl, López Jesús, Marco-Salazar Paola, Fondevila Dolors and Pumarola Martí. Spain.*

**P90- FATAL DIARRHOEA DUE TO EIMERIA LEUCKARTI IN A HORSE**

*Marinković Darko, Nešić Slađan, Katić-Radivojević Sofija, Đoković Stefan. Serbia.*

**P91- BALANTIDIUM COLI IN PMWS-SUSPECTED PIGS**

*Anna Szczotka, Zygmunt Pejsak. Poland.*

**P92- IMMUNOHISTOCHEMICAL STUDY OF THE INFLAMMATORY RESPONSE IN THE RUMEN AND RETICULUM OF Calicophoron daubneyi-INFECTED CATTLE**

*Ferreras M C, Pérez V, González-Lanza M C, Benavides J, Mezo M, Fuertes M, González-Warleta M, Delgado L, Martínez-Ibeas A, Manga-González M Y. Spain*

**P93- EARLY HEPATIC CHANGES AND IMMUNE RESPONSE IN GOATS VACCINATED WITH A RECOMBINANT GLUTATHIONE TRANSFERASE SIGMA CLASS AND CHALLENGED WITH *Fasciola hepatica***

*Zafra R, Pacheco IL, Buffoni L, Escamilla A., Martínez-Moreno A, LaCourse EJ, Brophy PM, Pérez J. Spain.*

**P94- FLOW CYTOMETRY FROM WHOLE BLOOD IN GOATS EXPERIMENTALLY INFECTED WITH *Fasciola hepatica***

*Zafra R, Buffoni L, Martínez-Moreno FJ, Bautista MJ, Escamilla A, Pacheco IL, Pérez J Martínez-Moreno A. Spain.*

**P95- DISTRIBUTION OF STELLATE CELLS IN SHEEP LIVER WITH PARASITIC FIBROSIS**

*Kukolj Vladimir, Aleksić-Kovačević Sanja, Jovanović Milijan. Serbia.*

**P96- PULMONARY HYPERTENSION IN NEW WORLD CAMELIDS (NWC) DUE TO INFECTION WITH LIVER FLUKES**

*Monika Hilbe, Nadja Robert, Christian Gerspach, Andreas Pospischil. Switzerland.*

**P97- STRAELENSIOSIS (*Straelensia cynotis*) IN A HUNTING DOG IN PORTUGAL – A CASE REPORT**

*Faisca Pedro, Santos Sara; Soeiro Joana; Azevedo Patrícia, Hernandez Cláudio, Carvalho Inês. Portugal.*

### **Wildlife and zoo animals pathology: infectious diseases**

**P98- ENCEPHALITIS IN CANTABRIAN CHAMOIS (*RUPICAPRA PYRENAICA PARVA*) CAUSED BY A FLAVIVIRUS**

*Martin-Hernando MP, Balseiro A, Oleaga A, Gortázar C, Ruiz-Fons F. Spain.*

**P99- PROTECTION OF SPANISH IBEX (*Capra pyrenaica*) AGAINST BLUETONGUE VIRUS SEROTYPES 1 AND 8 IN A SUBCLINICAL EXPERIMENTAL INFECTION**

*Lorca-Oró C, Pujols J, García-Bocanegra I, Mentaberre G, Granados JE, Solanes D, Fandos Pg, Galindo -Cardiel I, Domingo M, Lavín S, López-Olvera JR. Spain.*

## POSTERS LIST

**P100- LESIONS ASSOCIATED WITH INTRAMUSCULAR VACCINATION AGAINST WEST NILE VIRUS IN RED-LEGGED PARTRIDGES (ALECTORIS RUFA)**

*Gamino Virginia, Gutiérrez-Guzmán A. Valeria, Escribano-Romero Estela, Blázquez Ana-Belén, Saiz Juan-Carlos, and Höfle Ursula. Spain.*

**P101- ADENOVIRUS INFECTION IN A TURTLE (Testudo graeca) RELATED WITH HYPERPLASIC STOMATITIS AND ESOPHAGITIS**

*García-Morante Beatriz, Péntzes Judit, Costa Taiana, Martorell Jaime, Ramis Antonio, Martínez Jorge. Spain.*

**P102- EPIDEMIC RANAVIRAL DISEASE IN TWO COLLECTIONS OF CAPTIVE POISON DART FROGS**

*Yumi Une, Tomoo Kudou, Ken-ichi Tamukai, Satoshi Taharaguchi, Masaru Murakami. Japan*

**P103- HERPESVIRUS ASSOCIATED TO GENITAL LESIONS IN A STRIPED DOLPHIN (STENELLA COERULEOALBA) IN CANARY ISLANDS**

*Eva Sierra, Manuel Arbelo, Marisa Andrada, Daniele Zucca, Simona Sacchini, Josué Díaz Delgado, Antonio Fernández. Spain.*

**P104- RENAL LESIONS IN DEER (Cervus elaphus) – Mycobacterium avium subsp. paratuberculosis INVOLVEMENT**

*Matos AC, Figueira L, Martins MH, Matos M, Pires MA, Álvares S, Mendes A, Sousa N, Coelho A, Pinto ML. Portugal.*

**P105- GRANULOMATOUS LESIONS AND Mycobacterium avium subsp. paratuberculosis IN PORTUGUESE WILD BOARS (Sus scrofa)**

*Matos AC, Figueira L, Martins MH, Matos M, Andrade S, Álvares S, Mendes A, Sousa N, Coelho A, Pinto ML. Portugal.*

**P106- DIFFUSE LYMPHADENITIS AND DISSEMINATED Mycobacterium avium subsp. paratuberculosis INFECTION IN TWO WILD EURASIAN OTTERS (Lutra lutra L. 1758)**

*Matos AC, Figueira L, Martins MH, Matos M, Pires MA, Álvares S, Mendes A, Sousa N, Coelho A, Pinto ML. Portugal.*

**P107- TUBERCULOSIS-NEGATIVE GRANULOMATOUS INFLAMMATION IN THE LUNG AND LYMPH NODES OF THE ELK (Cervus elaphus)**

*Soon-Seek Yoon, Kyung-Hyun Lee, In-Soon Roh, Oun-Kyong Moon, Young-Hwa Jean, Jae-Won Byun, Myoung-Heon Lee. Gyeonggi-Do. South Korea.*

**P108- MYCOBACTERIOSIS IN OSTRICHES (STRUTHIO CAMELUS)**

*Kelly Pamela, Jahns Hanne, Power Eugene, Kenny Kevin, Corpa Juan M, Callanan John J. Ireland.*

**P109- SUBCUTANEOUS MYCOBACTERIOSIS WITH SYSTEMIC AMYLOIDOSIS IN A DOMESTIC PIGEON (COLUMBA LIVIA DOMESTICA)**

*Nouri M., Azarabad H., Madani A., Kamyabi Z., Moini M. Iran.*

**P110- GRANULOMATOUS SYSTEMIC INFECTION ASSOCIATED WITH Rhodococcus sp. IN POISON DART FROGS**

*David Hugo, Marques Pereira Nuno, Albuquerque Teresa, Faisca Pedro. Portugal.*

## POSTERS LIST

**P111- NECROTIC LARYNGITIS OF EUROPEAN BISON (BISON BONASUS) FROM BIAŁOWIEŻA FOREST**

*Osińska Barbara, Bielecki Wojciech, Rzewuska Magdalena. Poland.*

**P113- ULCERATIVE ENTERITIS-LIKE DISEASE ASSOCIATED WITH CLOSTRIDIUM BEIJERINCKII/ BUTYRICUM IN A PIGEON (COLUMBA LIVIA)**

*Bolfa P, Tabaran F, Niculae M, Borza G, Gal A, Bouari C, Taulescu M, Nagy A, Farcas L, Vidrighinescu R, Catoi C. Romania.*

**P114- HEMORRHAGIC-NECROTIZING COLITIS ASSOCIATED TO CAMPYLOBACTER JEJUNI AND BALANTIDIUM COLI IN A ZOO GORILLA**

*Isidoro Marc, Martínez Jorge, Ramis, Antonio. Spain.*

**P115- PULMONARY LESIONS CONSISTENT WITH DISSEMINATED ADIASPIROMYCOSIS IN EGYPTIAN MONGOOSES (Herpestes ichneumon) FROM PORTUGAL**

*Matos AC, Figueira L, Martins MH, Matos M, Pires MA, Coelho A, Pinto ML. Portugal.*

**P116- TOXOPLASMOSIS IN AUSTRALIAN MARSUPIALS IN CAPTIVITY**

*Cedillo C, Rangel IC, Espinosa D, Salas G, Rico CP, López O, Díaz M, Correa D. Mexico.*

**P117- THE OCCURRENCE EIMERIAN SPECIES AND HISTOPATHOLOGICAL LESIONS OF EUROPEAN BISON IN POLAND**

*Pyziel AnnaMaria, Osińska Barbara, Demiaszkiewicz Aleksander W. Poland.*

**P118- A CASE OF Dirofilaria immitis IN A EURASIAN OTTER (Lutra lutra)**

*Saraiva AL, Sousa S, Silva J, Andrade S, Botelho N, Canavarro I, Costa M, Ferreira F, Meier K, Silva JA, Tiago J, Kanoun-Boulé M. Portugal.*

**P119- IMMUNOPATHOLOGICAL STUDY OF PARASITIC CHOLANGITIS IN DOLPHINS**

*Jaber JR, Pérez J, Zafra R, Suárez-Bonnet A, Quesada O, Fernández A. Spain.*

**P120- BILIARY CIRRHOSIS CAUSED BY CAMPULA SPP IN DOLPHINS: AN IMMUNOHISTOCHEMICAL AND PATHOLOGICAL STUDY**

*Jaber JR, Rotstein D, Pérez J, Zafra R, Suárez-Bonnet A, Quesada O, Fernández A. Spain.*

### Wildlife and zoo animals pathology: miscellanea

**P121- INCREASED MORTALITY IN RED FOXES (Vulpes vulpes) IN SLOVENIA – PRELIMINARY STUDY RESULTS**

*Juntes Polona, Vengušt Gorazd, Žele Diana, Hostnik Peter, Paller Tomislav, Milan Pogačnik. Slovenia.*

**P122- PIGMENTARY NEURODEGENERATIVE DISEASE IN MACROPODS EXPOSED TO PHALARIS TUBEROSA**

*Bacci Barbara, Ceccolini Mary, Whiteley Pam. Australia.*

**P123- MULTIPLE MALFORMATIONS IN NON-RELATED CAPTIVE LIONS (Panthera leo)**

*Negrini J, Guerra R, Ruiz J, Novales M, Blanco B, Diz A, Guil S, Mozos E. Spain.*



## POSTERS LIST

**P124- MULTISEPTATE GALLBLADDER IN AN AFRICAN LIONESS (*Panthera leo*)**

*Garcia-Gonzalez Beatriz, Cuesta-Garcia Nerea. United Kingdom.*

**P125- THE ALOPECIA-SYNDROME OF SPECTACLED BEARS (TREMARCTOS ORNATUS) – WHAT DO WE KNOW, WHAT CAN WE DO?**

*Jäger, Kathrin, Langguth, Sandra, Einspanier, Almuth, Schachtner, Martina, Bechstein, Nadine, Schoon, Heinz-Adolf. Germany.*

**P126- CELLULAR IMMUNOPHENOTYPICAL CHARACTERISTICS IN A CASE OF EXTRAMEDULLARY HEMATOPOIESIS IN A GOELDI'S MONKEY (*Callimico goeldii*)**

*Noiva R, Pissarra H, Fernandes T, Bernardino R, Peleteiro C. Portugal.*

**P127- DECOMPRESSIVE PATHOLOGY IN RISSO'S DOLPHIN: DEADLY HUNTING**

*Fernández A, Bernaldo de Quirós Y, Sierra E, Sacchini S, Andrada M, Rivero M, Zucca D, Arbelo M. Spain.*

**P128- AMELOBLASTIC FIBROMA IN CHAMOIS (*Rupicapra rupicapra*)**

*Scaglione FE, Iussich S, Grande D, Chiappino L, Sereno A, Ferroglio E, Bollo E. Italy.*

**P129- ANAPLASTIC LARGE CELL LYMPHOMA IN A EUROPEAN WILD BOAR (*Sus scrofa*)**

*Rocha PRD, Biasibetti E, Palmerini D, Sereno A, de Vries C, Capucchio MT. Italy.*

**P130- A CASE OF IRIDOPHOROMA IN A DWARF BEARDED DRAGON (*Pogona henrylawsoni*)**

*de Brot S, Ruetten M, Sydler T. Switzerland*

**P131- MIXED TESTICULAR NEOPLASIA IN A COMMON DOLPHIN (*Delphinus delphis*) INVOLVING SERTOLI CELL TUMOR, INTERSTITIAL (LEYDIG) CELL TUMOR AND SEMINOMA**

*Arbelo M, Díaz-Delgado J, Espinosa de los Monteros A, Fernández-Maldonado C, Quesada O, Rivero M, Andrada M, Rodríguez-Grau Bassas E, Fernández A. Spain.*

## Fish pathology

**P132- DIAGNOSTIC METHODS FOR THE DETECTION OF VERTEBRAL MALFORMATIONS IN SENEGAL SOLE (*Solea senegalensis*, KAUP 1858) AT DIFFERENT STAGES OF DEVELOPMENT**

*De Azevedo AM, Losada AP, Barreiro A, Barreiro JD, Ferreiro I, Riáza A, Vázquez S, Quiroga MI. Spain.*

**P133- HISTOLOGICAL AND MORPHOMETRIC CHANGES OF SPLENIC MELANOMACROPHAGE CENTRES IN TURBOT (*Psetta maxima*) VACCINATED AGAINST FURUNCULOSIS**

*Coscelli G, Ronza P, de Azevedo AM, Losada AP, Failde LD, Sancho AR, Bermúdez R, Quiroga M. Spain.*

**P134- DOES THE TYPE OF TECHNOLOGY OF RAINBOW TROUT (*Oncorhynchus mykiss*) BREEDING INFLUENCE MORPHOLOGICAL PATTERN OF THE INTERNAL ORGANS AND IMMUNITY IN THIS FISH?**

*Szarek J, Siwicki KA, Babińska I, Skibniewska KA, Dobosz S, Goryczko K, Guziur J, Szynaka B, Strzyżewska E, Wojtacka J, Terech-Majewska E, Zakrzewski J, Wiśniewska A, Szweda M. Poland.*

## POSTERS LIST

**P135- CHANGES IN SPLENIC MELANOMACROPHAGE CENTRES OF TURBOT, PSETTA MAXIMA (L.), EXPERIMENTALLY INFECTED WITH ENTEROMYXUM SCOPHTHALMI (MYXOZOA)**

*Ronza P, Coscelli G, Losada AP, Bermúdez R, Quiroga MI. Spain.*

## Toxicopathology

**P136- FRACTAL ANALYSIS USED FOR IDENTIFYING THE IMPACT OF DRUGS ON THE HEPATIC TISSUE**

*Gaita L., Militaru M. Romania.*

**P137- ASSESSMENT OF MULTI-WALLED CARBON NANOTUBES (MWCNT) IMMUNOTOXICITY ON THE PERITONEUM-ASSOCIATED LYMPHOID TISSUE**

*Tăbăran Alexandru-Flaviu, Cătoi Cornel, Bolfă Pompei, Nagy Andras, Gal Adrian, Taulescu Marian, Bouari Cosmina, Simona Clichici, Teodora Mocanu. Romania.*

**P138- MORPHOLOGICAL LESIONS IN MOUSE LIVER AND LUNGS AFTER CARBON NANOTUBES LUNG EXPOSURE**

*Szarek J, Mortensen A, Jackson P, Saber AT, Kyjovska ZO, Wallin H, Vogel U, Hougaard KS. Poland.*

**P139- CELL PROLIFERATION-INDUCING CARCINOGENS LEAD TO ABERRANT ACTIVATION OF G2/M CHECKPOINT AND APOPTOSIS AFTER 28-DAY ADMINISTRATION IN RATS**

*Eriko Taniai, Atsunori Yafune, Kunitoshi Mitsumori, Makoto Shibutani. Japan.*

**P140- STUDIES ON LIVER TUMOR PROMOTING EFFECTS OF ORPHENADRINE IN RATS**

*Reiko Morita, Hitomi Hayashi, Kazuhiko Suzuki, Makoto Shibutani and Kunitoshi Mitsumori. Japan.*

**P141- EFFECT OF MATERNAL EXPOSURE TO GLYCIDOL ON NERVOUS SYSTEM OF DAMS AND OFFSPRING IN RATS**

*Hirotohi Akane, Fumiyo Saito, Ayako Shiraki, Kunitoshi Mitsumori, Makoto Shibutani. Japan.*

**P142- MELAMINE INDUCED NEPHROTOXICITY IN WEANED PIGS**

*Kureljušić B, Ivetić V, Savić B, Krnjajić S, Risteovski D, Kureljušić J, Jezdimirović N, Jakić-Dimić D. Serbia.*

**P143- SAFETY ASSESSMENT IN PIGS OF AN EXPERIMENTAL MOLECULE WITH IN VITRO ANTIVIRAL ACTIVITY AGAINST AFRICAN SWINE FEVER**

*Roels Stefan, Van der Heyden Sara, Neyts Johan, Krečmerová Marcela. Belgium.*

**P144- THE EFFECT OF WHITE-ROT FUNGI ON *Jatropha curcas* L. PRESSED-SEED CAKE DETOXIFICATION ON CHICKS VISCERAL ORGANS**

*Alves A, Barros C, Gama A, Bezerra R, Mourão J, Rodrigues M. Portugal.*

**P145- OXT GENE UP-REGULATION IN BOVINE SKELETAL MUSCLE INDUCED BY DEXAMETHASONE AND 17BETA-OESTRADIOL**

*Divari S, Cannizzo FT, Starvaggi Cucuzza L, Brina N, Mulasso C, Spada F, De Maria R, Biolatti B. Italy.*

## POSTERS LIST

**P146- PROGESTERONE RECEPTOR UP-REGULATION FOLLOWING IN VITRO ESTROGEN TREATMENT**

*Starvaggi Cucuzza L, Cannizzo FT, Divari S, Spada F, Botta M, Biolatti . Italy.*

**P147- MORPHOMETRIC ANALYSIS OF TESTICULAR STRUCTURES IN TENCH (TINCA TINCA) AFTER EXPOSURE TO 17 ALPHA-ETHYNYLESTRADIOL**

*Gómez L, Jiménez B, Fallola C, Pula HJ, Cuesta JM, Galapero J, Oropesa AL. Spain.*

### **Naturally occurring and experimentally induced pathology in different organs and tissues**

**P148- INTERSPECIES DIVERGENCE OF MODULATOR GENES IN CYSTIC FIBROSIS AND ITS RELEVANCE TO TRANSLATIONAL MEDICINE**

*Plog S, Klymiuk N, Mundhenk L, Wolf E, Gruber AD. Germany.*

**P149- THE INCIDENCE OF GROSS MALFORMATIONS IN CHICK EMBRYOS OF ROSS 308 BROILERS**

*Dolka I, Kosowska G, Żbikowski A, Dolka B, Doner S, Szeleszczuk P. Poland.*

**P150- DEGENERATIVE MOTOR POLIOENCEFALOPATHY WITH CYTOSKELETON DISRUPTION IN GENETICALLY MODIFIED MICE**

*Márquez Merce, Capdevila Sara, Zamora Carolina, Rabanal Rosa M., Pumarola Martí, Martín Caballero Juan. Spain.*

**P151- IMMUNOMODULATION WITH EPIGALLOCATECHIN GALLATE IN INJURED SPINAL CORD OF RABBIT**

*Shaho Ghahramani Dehbokri, Hossein Dehghani, Reza Mohammadzadeh. Iran.*

**P152- HISTOPATHOLOGICAL & IMMUNOHISTOCHEMICAL SURVEY ON ALCL3 MICROINJECTION IN RAT HIPPOCAMPUS**

*Moayer Fariborz , Seyed Farshi A. , Roudgari R. Iran.*

**P153- PATHOHISTOLOGICAL AND IMMUNOHISTOCHEMICAL EXAMINATIONS OF BRAINS IN DYING AND SURVIVING SEPTIC MICE.**

*Klang Andrea, Högler Sandra, Osuchowski Marcin, Katrin Weixelbaumer, Tichy Alexander, Schmidt Peter. Austria.*

**P154- THE WOBBLY HEDGEHOG SYNDROME– A CLINICAL ENTITY WITH VARIABLE CNS LESIONS**

*Karkamo Veera, Dillard Kati, Schulman Kitty, Anttila Marjukka. Finland.*

**P155- AGED-RELATED LIPOFUSCIN ACCUMULATION IN DOG BRAIN**

*Nesic S, Ristic B, Jovanovic M. Serbia.*

**P156- MORPHOLOGIC EVALUATION OF THE AGING PROCESS IN BOVINE PERIPHERAL NERVES**

*Biasibetti E, Iuliano A, Rocha PRD, Amedeo S, Mioletti S, Bianco P, Bisanzio D, Capucchio MT. Italy.*

## POSTERS LIST

**P157- DISEASES OF THE CENTRAL NERVOUS SYSTEM IN CATTLE FROM THE STATE GOIÁS, MIDWESTERN BRAZIL**

*Sant'Ana FJF, Ferreira Junior JA, Moreira Junior CA, Freitas Neto AP, Costa YL, Resende RM. Brazil.*

**P158- HIGH-FLOW PRIAPISM CONSECUTIVE TO LUMBAR SPINAL STENOSIS IN A DOG: CASE REPORT**

*Payan-Carreira R, Colaço B, Albuquerque C, Abreu H, Rocha C, Pires MA. Portugal*

**P159- EFFECTS OF GLUCOSAMINE SULFATE, CHONDROITIN SULFATE AND HIALURONIC ACID ON ARTICULAR CARTILAGE**

*Mónica López, María Permuy, Fernando Muñoz, Oscar Varela, David Guede, José Ramón Caeiro, Antonio González-Cantalapiedra. Spain.*

**P160- A CASE OF BULL-DOG TYPE CHONDRODYSPLASIA IN A MINIATURE SCOTTISH HIGHLAND CALF**

*Dittmer KE, Hogan T, Thompson KG. New Zealand.*

**P161- OSTEOCHONDROSIS IN YOUNG FIGHTING BULLS: PATHOLOGY, FREQUENCY AND SEVERITY IN SPANISH FARMS**

*Dávila, U. M, Méndez-Angulo, J.L., Sierra M.A., Méndez, A. Spain.*

**P162- A CASE OF HYPERTROPHIC OSTEOPATHY IN A CAT ASSOCIATED WITH A PNEUMONIA DUE TO AN AWN**

*Brandes K, Heblinski N. Germany.*

**P163- FRONTONASAL INTRADIPLOIC EPITHELIAL INCLUSION CYST IN THREE HORSES**

*Gunnarsdottir Helga, Chiers Koen, Saunders Jimmy, Schauvliege Stijn, Vlaminc Lieven. Belgium.*

**P164- CONGENITAL CUTANEOUS MUCINOSIS IN GREAT DANE PUPPIES**

*Hoffmann Annalena, Wöhlke Anne, Distl Ottmar, Peters Martin, Hewicker-Trautwein Marion. Germany.*

**P165- INTRAEPIDERMAL CYTOKERATIN CAM5.2-POSITIVE CELLS IN DOG NIPPLES**

*Yasuno K, Kobayashi R, Yoshimura H, Takahashi K, Ohmachi T, Kamiie J, Shirota K. Japan.*

**P166- CANINE DILATED CARDIOMYOPATHY IS ASSOCIATED WITH INCREASED MYOCARDIAL ICAM1 EXPRESSION**

*Sonja Fonfara, Udo Hetzel, Mark Oyama, Simon R Tew, Anja Kipar. Finland.*

**P167- TETRALOGY OF FALLOT IN A PIG**

*Laura Polledo, Jorge González, Beatriz Martínez-Fernández, Claudia Pérez-Martínez M<sup>a</sup> José García Iglesias. Spain.*

**P168- ATYPICAL HYPERCHYLOMICRONAEMIA IN A DOMESTIC SHORTHAIRED CAT**

*Richard Blundell, Lorna Arrol. United Kingdom.*

**P169- MORPHOMETRIC CHARACTERISTICS OF THYROID GLAND IN APO E KO MICE**

*T. Ristoski, T. Tripunoski, J. Dimitrova-Shumkovska. Republic of Macedonia.*

## POSTERS LIST

**P170- PANCREAS AND THYROID HYPOPLASIA ASSOCIATED WITH RETARDED GROWTH IN A 3.5-MONTH OLD CHIHUAHUA**

*Moreno B, Badiola JJ. Spain.*

**P171- SITAGLIPTIN DELAYS PROGRESSION OF RENAL LESIONS IN A RODENT MODEL OF TYPE 2 DIABETES**

*Mega Cristina, Vala Helena, Oliveira Jorge, Fernandes Rosa, Teixeira Frederico, Teixeira de Lemos Edite, Reis Flávio. Portugal.*

**P172- PRESENCE OF KIMMELSTIEL-WILSON LIKE LESIONS IN CANINE CHRONIC KIDNEY DISEASE**

*Vala H, Mega AC, Mesquita J, Nóbrega C, Cruz R, Esteves F, Ortiz AL, Santos C, Teixeira de Lemos E, Reis F. Portugal.*

**P173- ADRENO-HEPATIC FUSION IN DOMESTIC FERRETS (MUSTELA PUTORIUS FURUS)**

*Quesada-Canales O, Suárez-Bonnet A, Ramírez GA, Herráez P, Andrada M, Paz Y, Espinosa de los Monteros A. Spain.*

**P174- IMMUNOHISTOCHEMICAL DETECTION OF VEGF SYSTEM IN ARRESTING AND VIABLE IMPLANTATION SITES IN IBERIAN PIG**

*García-Fernández RA, Sánchez MA, Sánchez B, García-Palencia P, Ruiz-González I, Naranjo C, Palomo A, y Flores JM. Spain.*

**P175- TNF STAINING PATTERN ON GLANDULAR AND CYSTIC CANINE ENDOMETRIAL EPITHELIA**

*Santos C, Vala H, Pires MA, Payan Carreira R. Portugal.*

## Diagnostic methods

**P176- EVALUATION OF ANIMAL NON-ACCIDENTAL INJURIES IN FORENSIC VETERINARY INVESTIGATIONS**

*Berzina Dace. Latvia.*

**P177- EVALUATION OF ERYTHROPOIESIS SYSTEM IN BONE MARROW OF HEALTHY HOLSTEIN-FRESIAN COWS (HF)**

*Anna Snarska, Izabella Babinska. Poland.*

**P178- EVALUATION OF LEUKOCYTAL SYSTEM IN BONE MARROW OF HEALTHY HOLSTEIN-FRESIAN COWS (HF)**

*Izabella Babińska, Anna Snarska. Poland*

**P179- STUDY OF BONE MARROW HISTOLOGY: THE PROCEDURE CHECKPOINT**

*Lourenço L, Gama A, Pires MA. Portugal*

**P180- IMMUNOHISTOCHEMICAL DETECTION OF DENDRITIC CELL MARKERS IN CATTLE PARAFFIN WAX-EMBEDDED TISSUES**

*Romero-Palomo Fernando, Rivalde María Angeles, Molina Verónica, Sánchez-Cordón Pedro José, Pedrera Miriam, Gómez-Villamandos José Carlos. Spain*

## POSTERS LIST

### **P181- IMMUNOHISTOCHEMICAL EXPRESSION OF CAVEOLIN-1 IN CHRONIC CANINE LIVER DISEASE**

*Nagy Andras-Laszlo, Bolfa Pompei., Taulescu Marian., Tabaran Flaviu., Bouari Cosmina., Gal Adrian., Borza Gabriel., Catoi Cornel. Romania.*

### **P182- MEASUREMENT OF REID INDEX IN NORMAL PIG LUNGS**

*Gil V, Ramírez T, Paz Y, Quesada-Canales O, Suárez-Bonnet A, Herráez P, Andrada M1. Spain.*

### **P183- EVALUATION AND CHARACTERIZATION OF INTESTINAL OEDEMA IN PIGS**

*Ortiz Ana Liza, Vala Helena, Silva Aura, Venâncio Carlos, Garcia Carla, Ferreira David. United Kingdom.*

### **P184- IMMUNOHISTOCHEMICAL CHARACTERIZATION OF LANGERIN IN TURBOT, *Psetta maxima* (L.)**

*Sancho AR, Coscelli GA, Failde LD, Bermúdez R, Quiroga MI. Spain.*

# KEYNOTES





## KEYNOTE 1:

### SCHMALLEMBERG AND OTHER TERATOGENIC VIRUSES

Journal of Comparative Pathology Plenary Lecture 2012

**Sandra F. E. Scholes**

Animal Health and Veterinary Laboratories Agency. UK.

In late Autumn 2011 an epizootic of ruminant congenital deformities, associated with a newly detected orthobunyavirus, was first recorded in Europe. The orthobunyavirus, provisionally named Schmallenberg virus, was detected at the Friedrich-Loeffler-Institut (FLI) by metagenomic analysis of blood samples, initially from adult cattle in Germany presenting with a mild febrile illness. Ruminant orthobunyaviral infections, such as Akabane and Cache Valley viruses, are associated with teratogenic effects consequent to *in utero* infection. Following the rapid dissemination of this information by FLI, diagnosticians throughout Europe were alert for such malformations in ruminants.

A range of malformations of the central nervous system, including hydranencephaly and myelodysplasia leading to arthrogryposis, have since been detected in association with Schmallenberg virus in sheep and cattle in Europe.

In this lecture, the range of congenital lesions associated with *in utero* Schmallenberg virus infections will be described and contrasted with malformations associated with other teratogenic viruses, which provide insights into the varying pathogenesis of transplacental viral infections.



## KEYNOTE 2:

### **ORTHOBUNYAVIRUS MALFORMATIONS: AKABANE, CACHE VALLEY AND SCHMALLEMBERG VIRUSES: NOT NEW, JUST A CHANGE IN VENUE**

**John F. Edwards**

Department of Veterinary Pathobiology. College of Veterinary Medicine and Biomedical Sciences. Texas A&M University. College Station, Texas, USA

When Akabane virus (AKV) was first described as an arthropod-borne virus causing an arthrogryposis and hydranencephaly syndrome (AGH) in cattle and sheep, it was labeled an exotic viral disease. It remained “exotic” despite it being identified in Australia and Israel. In 1985, an identical AGH outbreak occurred in San Angelo Texas in sheep, and the fear was that Akabane had entered the United States. Fortunately, it was demonstrated that Cache Valley virus (CVV) was the etiology. Subsequently CVV was shown to cause malformations sporadically in cattle as well. Experiments showed that several other Orthobunyaviruses could cause AGH in sheep and another orthobunyavirus, Aino virus was associated with sporadic natural AGH cases in Japan. In 2011, Schmallenberg virus (SBV) was identified in cattle and isolated from the blood of a sick cow. Subsequently, this virus was associated with AGH especially in small ruminants. The rapidity of the characterization of SBV is a tribute to the European team of scientists using metagenomics and the collaboration of European Community field veterinarians. Both AKV and CVV viruses were known for over 20 years before AGH was associated with these pathogens.

Over 160 Orthobunyaviruses are known, and it is expected that AGH will be found to be caused by a variety of endemic orthobunyaviruses around the world. This group of viruses is numerous because they have 3 genome segments and have been shown to reassort in nature and give rise to new viruses. The viruses in all cases are associated with a vague set of clinical signs in the host including: fever, myalgia and decreased milk production. However, the necessary constellation of events for a case of AGH includes:

1. a naïve host
2. this host has to be pregnant at the stage of gestation when the fetus is susceptible,
3. the host has to be in an area where competent vectors of the virus are active,  
and
4. all of these features have to occur together when the virus is prevalent.

## KEYNOTES

For that reason, outbreaks in a small geographic area are rare. However, sporadic cases in herds and flocks are the usual epidemiology, and because only sporadic cases occur, vaccines have not been economically justified. These viruses have coevolved with their vectors, and in order to understand and perhaps control the disease, we have to understand the role and biology of the vector. Not all hematophagous arthropods can transmit infections, and vectors have a critical role in amplifying infection. Infection can cause fatal encephalitis infrequently, and infection and recovery confer immunity. This explains cycles of cases in herds because new, naïve hosts must enter the population to have new cases in a population. Transmission by handling blood, fluids and tissues is almost non-existent. Humans are susceptible when bitten by a competent infected vector.

**KEYNOTE 3:**

**TRANSBOUNDARY ANIMAL DISEASES: PATHOLOGY AND  
PATHOGENESIS**

**Corrie Brown**

Department of Veterinary Pathology. College of Veterinary Medicine. University of Georgia. USA

“There are two ways to become famous when a transboundary disease enters your area, and that is to either recognize it or to miss it.” For diagnosticians, this old saying has a special ring of clarity. In our increasingly interconnected world, recognizing transboundary diseases is more relevant than ever. Failure to diagnose an incursion can have drastic national economic consequences. Although many of us have been academically exposed to all the transboundary diseases through our training, often this was not done in a systematic way that allowed for a thorough understanding of the pathogenesis. Visualizing the path of the agent through the body and knowing the various mechanisms by which damage occurs are essential for being able to recognize all the permutations and combinations that a particular disease takes. In this session, pathogenesis of several of the more prominent transboundary disease agents will be reviewed, so that pathologists can feel more comfortable with these entities and rest assured knowing that if one enters their arena, they will become famous for all the right reasons.



## KEYNOTE 4:

### WILDLIFE DISEASE CONTROL IN THE 21ST CENTURY

**Christian Gortazar**

National Wildlife Research Institute IREC. CSIC-University of Castilla-La Mancha.  
Spain

Total eradication of a shared infectious agent is almost impossible if a wildlife host is able to serve as a natural reservoir of the pathogen. In the last decades, difficulties in the eradication of shared diseases such as classical swine fever and bovine tuberculosis have prompted a growing interest in disease control in wildlife reservoirs. The control of diseases shared between livestock and wildlife requires the development of strategies that reduce pathogen transmission between wildlife and domestic animals. This review includes a concise update on the status of several significant diseases shared with European wildlife, and on current knowledge on the role of wildlife in infection maintenance. The main content of this review is a description of the options available for wildlife disease control, from preventive measures to vaccination and culling. This includes a critical review of techniques currently applied and a forecast on wildlife disease control in the coming decade. Pathology is a key tool in the wildlife disease field and contributes significantly to active and passive surveillance and to the assessment of the efficacy of disease control actions.

The first requisite for any disease control in wildlife is establishing a proper monitoring scheme. Monitoring is needed to identify changes in disease occurrence and to measure the impact of intervention. Once such a scheme is set up, actions towards disease control can be critically assessed. Disease control in wildlife reservoir hosts can eventually be achieved by different means, including (1) the improvement of biosafety and hygiene, (2) population control through random or selective culling or through habitat management, and (3) vaccination. Ideally, tools from all three fields should be combined in an integrated control strategy.

Regarding the improvement of biosafety and hygiene, actions can range from (i) dispersing the available water points and replacing feeding sites on the ground by selective feeders which are not accessible to certain species; to (ii) the proper removal of harvested animals (including viscera) to limit potential infection spread by mammals; and (iii) improving farm biosafety. Any practice to segregate wildlife and livestock from common resources such as waterholes or feed may prove beneficial, for example by setting up wildlife or livestock selective enclosures. However, more observational

## KEYNOTES

and experimental research is needed in all these fields, none of these actions has been scientifically assessed regarding its actual contribution to disease control.

In overabundant game populations, methods for controlling overabundance should be used before testing other, more costly means. However, hunting has limitations in its ability to control wildlife populations, for instance in protected areas or urban habitats, and the effects of culling are only temporary if population control is not sustained over time. Moreover, culling is not a single tool but rather one of several elements of an integrated disease control strategy, likely based on vaccination. Again, more observational and experimental research on random and on selective culling is needed. Also, research on alternative means of limiting wildlife numbers, such as immunocontraception, or feeding bans, is needed.

In this context, wildlife vaccination to reduce infection prevalence emerges as a valuable alternative or complementary tool in disease control. The best option to reach wildlife populations over a wide geographical area would be the delivery of the vaccine via oral baits. Disease control through vaccination of wildlife reservoirs may potentially have advantages over other approaches. As opposed to culling, vaccination is a non-destructive and sustainable method of controlling disease in wildlife that may be more acceptable to the public.



## KEYNOTE 5:

### WHAT'S NEW ON THE HISTOPATHOLOGY OF CANINE MAMMARY TUMORS?

**Laura Peña**

Veterinary Pathology. Veterinary Faculty. Complutense University of Madrid (Spain)

Canine mammary tumors (CMT) are the most common neoplasms of the female dog, especially in countries where early ovariectomy is not usually performed. Therefore, CMT are frequent in the daily routine of veterinary pathologists. Histological diversity of CMT makes difficult their diagnosis. In January 2011 a new histological classification<sup>2</sup> of CMT was proposed as an initiative of the American College of Veterinary Pathologists' Oncology Committee, and reviewed and endorsed by the World Small Animal Veterinary Association. This classification, based on the WHO's latest histological classification<sup>3</sup>, includes new histological types and reclassify or rename others. Also, hyperplasias and neoplasms of the nipple have been considered for the first time. Among malignant epithelial neoplasms, cribriform carcinoma, micropapillary invasive carcinoma, comedocarcinoma, carcinoma and malignant myoepithelioma, ductal carcinoma, intraductal papillary carcinoma, adenosquamous carcinoma and inflammatory carcinoma have been included as new histological subtypes, while carcinoma arising in a complex adenoma/mixed tumor, and carcinoma-mixed type have been rename. Among benign mammary neoplasms, myoepithelioma has been included as a new type, and intraductal papillary adenoma and ductal adenoma have been renamed. Regarding canine mammary hyperplasias/dysplasias, lobular hyperplasia has been subdivided in: regular, with secretory activity, with fibrosis, and with atypia; intraductal papillomatosis and canine fibroadenomatous change are other new types considered. Specific histological criteria for malignancy in canine mammary tumors are: tumor type, significant nuclear and cellular pleomorphism, mitotic index, areas of necrosis, peritumoral and lymphatic invasion and regional lymph node metastases.

The histological type of malignant CMT provides little prognostic information. Following the most used worldwide human breast cancer grading system (Elston and Ellis' numeric method, also known as Nottingham method)<sup>1</sup> an adapted system for CMT has been proposed<sup>2</sup>. This grading system is based on the assessment of three morphological features: Tubule formation, nuclear pleomorphism and mitotic counts; each one of these features is scored 1-3. Histological grading of canine malignant mammary neoplasms is a useful tool for the prognosis of animals with malignant CMT,

## KEYNOTES

facilitates the histological interpretation, and offers the veterinary pathologists uniform criteria.

- 1 Elston CW, Ellis IO: Pathological prognostic factors in breast cancer. I. The value of histological grade in breast cancer: experience from a large study with long-term follow-up. *Histopathology* 19: 403-410, 1991
- 2 Goldschmidt M, Pena L, Rasotto R, Zappulli V: Classification and Grading of Canine Mammary Tumors. *Veterinary Pathology* 48: 117-131, 2011
- 3 Misdorp W, Else RW, Hellmen E, Lipscomb TP: *Histologic Classification of Mammary Tumors of the Dog and Cat*, vol. 7, Armed Force Institute of Pathology and World Health Organization, Washington DC, 1999

**KEYNOTE 6:****INTESTINAL INFLAMMATORY DISEASE IN ANIMALS AND HUMANS AS A SLOW INFECTION****Ramon A. Juste**

Animal Health Department. NEIKER-Tecnalia. Derio. Bizkaia. Spain

Chronic regional Intestinal inflammatory disease (IID) is a pathological condition that has been reported in different animal species including humans. Except for paratuberculosis in ruminants the condition is generally assumed to be caused by a dysfunctional immune response to unknown factors. Paratuberculosis or Johne's disease was first reported by Johne and Frothingham in 1895, and thus is one of the first fully described pathological entities in animals. Its human counterpart, even though with some much earlier possible reports, was not classified as a definite entity (CD) until 30 years later by Crohn and others. One of the reasons for a missing causality for human and, in general, non-ruminant IID is that no single microorganism fulfills all classical Koch postulates. Actually Koch postulates are not fulfilled for paratuberculosis either, but in this case the obvious presence of mycobacteria in the most common immunopathological forms made attribution of causality to *Mycobacterium avium* subsp. *paratuberculosis* a model unanimously accepted by the scientific community since its first description. This fact leaves paratuberculosis in a position of biological singularity that prompts challenging either the mycobacterial etiology of paratuberculosis or the non-mycobacterial etiology for the other species IID. Since lack of evidence is a weaker argument than incomplete evidence and given that paratuberculosis broad range of immunopathological forms allows to accommodate granulomatous inflammation without patent presence of mycobacteria, here I will focus the discussion on the mycobacterial hypothesis. Paratuberculosis, like other mycobacterial infections, is considered to be an spectral disease in the sense that it presents a whole spectrum of immunopathological forms that in the most advanced stages can be defined by its two extremes: a) lymphocytic, tuberculoid or paucibacillary and b) non-lymphocytic, lepromatous or multibacillary. This classification firmly established for the three main domestic ruminant species, precisely by the group that hosts this ESPV meeting, is key to undertake a comparative study of IID throughout the different animal species including primates. This concept of spectral immunopathology could provide a frame in which to fit all the forms of IID going from the extreme paucibacillary (slightly higher proportion of MAP DNA positive results than in controls) human and carnivore CD forms, to the intermediate

## KEYNOTES

equine forms (where sometimes multibacillary forms are found), to the paucibacillary (mycobacteria are always detected by culture and PCR) and multibacillary forms of ruminants. This model would fit in the more general concept of slow infection originally proposed for maedi by B. Sigurdsson which would represent a general immunopathological response essentially similar across different species characterized by: a) Involvement of a low virulence agent (that could be part of a normal ecologic balance within the host); b) Association to individual genetic factors; c) Frequent location in the mucosal environment-organism interphase; d) Prominent macrophagic-lymphocytic inflammation (indicative of an innate local immune response); e) Absence or inefficiency of specific immune response; f) High ratio of healthy carriers to clinical cases; g) Clinical onset most frequent in early-adulthood; h) Progressive clinical course leading to wasting to death.

# **ORAL PRESENTATIONS**



## O1- NATURAL HISTORY OF IN SITU, MICRO-INVASIVE, AND INVASIVE CANINE MAMMARY CARCINOMAS

*Nguyen Frédérique, Loussouarn Delphine, Godard Tiffanie, Morio Floriane, Ibisch Catherine, Campone Mario, Abadie Jérôme Oniris, Nantes, France, frederique.nguyen@oniris-nantes.fr*

**Introduction:** In human breast cancer, the distinction between ductal carcinoma in situ (DCIS) and invasive ductal carcinoma (IDC) precedes the establishment of prognosis and adjuvant therapies. We aimed to assess if such a classification would apply in dogs.

**Materials and Methods:** Retrospective study of 274 surgically-treated canine mammary carcinomas, with a 2-year follow-up. Invasiveness was defined immunohistochemically using p63 as a myoepithelial cell (MEC) marker. Pure DCIS (N=49) had a complete p63-positive MEC layer, ductal carcinomas in situ with microinvasion (DCISMI, N=29) had an incomplete layer, IDCs lacked such a MEC layer (N=196 cases, free of lymph node metastasis).

**Results:** Pure DCIS and DCISMI did not significantly differ in terms of tumor size, disease-free survival, overall and specific survival. IDCs were significantly larger ( $18.8 \pm 7.0$  mm, median 19 mm) than DCIS ( $13.2 \pm 6.0$  mm, median 12 mm). Disease-free survival was longer in dogs with DCIS (median not reached) than IDC (median 1297 days, p

## O2- CORRELATION BASED ON THE PROTEIN EXPRESSION PROFILE BETWEEN PRIMARY CANINE MAMMARY TUMOUR AND ITS LYMPH NODE METASTASIS

*Beha Germana<sup>1</sup>, Brunetti Barbara<sup>1</sup>, Asproni Pietro<sup>2</sup>, Muscatello Luisa Vera<sup>1</sup>, Millanta Francesca<sup>2</sup>, Poli Alessandro<sup>2</sup>, Sarli Giuseppe<sup>1</sup>, Benazzi Cinzia<sup>1</sup>*

*1 Department of Veterinary Medical Sciences – University of Bologna, Italy,; 2 Department of Animal Pathology, University of Pisa, Italy. germana.beha2@unibo.it*

**Introduction:** This study was aimed to evaluate the relationship between the molecular phenotype of the primary mammary tumour and its related lymph node metastasis in the dog to develop prognostic-predictive models and targeted therapeutic options.

**Materials and Methods:** Twenty mammary tumour samples and their lymph node metastases were selected and stained by immunohistochemistry using anti-Estrogen Receptor, -Progesterone Receptor, -Human Epidermal growth factor Receptor 2 (c-erbB-2), -cytokeratin 5/6, -cytokeratin 14, -cytokeratin 19 and -protein 63 antibodies.

**Results:** Four phenotypes (Luminal A, Luminal B, c-erbB2 over-expressing, Basal-like) were diagnosed in primary tumours and five (Luminal A, Luminal B, c-erbB2 over-expressing, Basal-like, Normal-like) in the lymph node metastases. Phenotypic concordance was found in 13 of the 20 cases, and 7 cases showed discordance with lymph node phenotypic profile being different than in the primary tumour.

**Discussion and Conclusion:** According to the present results, the phenotype of the primary tumour assumes a predictive-therapeutic role only in concordant cases, this meaning that there should be a simultaneous evaluation of both the primary tumour and its lymph node metastasis. The treatment plan based only on the primary tumour phenotype could produce therapeutic failures if the phenotype of lymph node metastasis was different from that of the primary tumour.



### **O3- IN VITRO ESTABLISHMENT AND CHARACTERIZATION OF MYOEPITHELIAL CELL LINES FROM FOUR CANINE MAMMARY CARCINOMAS AND TWO NORMAL MAMMARY GLANDS**

*Sánchez-Céspedes R<sup>1</sup>, Maniscalco L<sup>2</sup>, Iussich S<sup>2</sup>, Martignani E<sup>2</sup>, Millán Y<sup>1</sup>, Guil-Luna, S<sup>1</sup>, De Maria R<sup>2</sup>, Martín de las Mulas J<sup>1</sup>*

*1 University of Córdoba, Córdoba, Spain 2 University of Turin, Turin, Italy, v32sancr@uco.es*

**Introduction:** Two thirds, approximately, of mammary carcinomas of any histologic subtype contain myoepithelial (ME) cells. Aim of this study was to isolate and culture ME cells from canine mammary glands.

**Materials and Methods:** ME cells from normal (3) and tumoural (5) glands were isolated using CD90 antibody and the MACS® method. Purified ME cells were cultured in supplemented DMEM/F12 media during 40 days. The expression of the ME and luminal epithelial cell markers was evaluated with the ABC method. Tissue samples were routinely processed for histology.

**Results:** Purity of isolated ME cells was some 90%. Growth rate and morphology varied between normal and tumoural glands as well as among histologic subtypes of tumours. Cultured cells expressed CK14, CK5, calponin, alpha-actin and vimentin heterogeneously but not CK19 and maintained this immunophenotype until their first cell passage.

**Discussion and Conclusions:** This is the first time that a pure population of ME cells from normal and neoplastic canine mammary gland have been obtained and cultured. Both morphology and immunophenotype are compatible with ME cells. This methodology opens up the possibility of in vitro studies of the tumour suppressor or tumour progressor role of ME cells in canine mammary cancer.

Acknowledgements: AGL2011-25553.

#### **O4- MARKERS FOR CIRCULATING TUMOR CELLS ARE ABLE TO IDENTIFY BLOOD FROM DOGS WITH MALIGNANT MAMMARY TUMORS**

*Klopfleisch Robert, da Costa Afonso, Gruber Achim D.*

*Institute of Veterinary Pathology, Freie Universität Berlin, Berlin, Germany.  
robert.klopfleisch@fu-berlin.de*

**Introduction:** Detection of circulating tumor cells (CTC) using nucleic-acid based method such as RT-PCR has proven prognostic relevance and is able to monitor the therapeutic success in human oncology but there is no information on their potential benefit in veterinary oncology.

**Material and Methods:** mRNA samples extracted from the blood of bitches with mammary tumors were grouped as carcinomas with (group 1, n=40) or without vascular invasion (group 2, n=40) or bitches with adenomas (group 3, n=40). Samples were tested by RT-PCR for the expression of 7 previously identified marker. Positive marker detection was correlated with histology and analyzed statistically.

**Results :** The marker gene CRYAB was significantly more often present in group 3 blood samples and was able to detect these samples with a sensitivity of 35% and specificity of 100%. Combination of CRYAB, CLDN7, ATP8B1 and EGFR in a multimarker assay enhanced the sensitivity up to 77.5% but decreased specificity to detect group 3 samples.

**Conclusion:** This pilot study provides proof of principle that the presence of CTC mRNA markers in patient blood is associated with the level of malignancy in canine mammary tumors and may be of prognostic relevance by predicting metastatic spread.

## **O5- EXPRESSION OF MAMMALIAN TARGET OF RAPAMYCIN (mTOR) IN FELINE MAMMARY TUMORS: A POTENTIAL TARGET THERAPY IN TRIPLE NEGATIVE TUMORS**

*Maniscalco L<sup>1</sup>, Iussich S<sup>1</sup>, Denina M<sup>1</sup>, Martín de Las Mulas J<sup>2</sup>, Millán Y<sup>2</sup>, Biolatti B<sup>1</sup>, Sasaki N<sup>3</sup>, Nakagawa<sup>3</sup>, De Maria R<sup>1</sup>.*

*1 University of Torino, Italy. lorella.maniscalco@unito.it, 2 Universidad de Córdoba.*

**Introduction:** Triple-negative breast cancer (TNBC) is defined by the absence of the estrogen (ER), progesterone (PR) and HER2 receptors. mTOR is a serine/threonine kinase over-expressed in TNBC representing a suitable target for the treatment of this tumoral sub-type. Feline mammary carcinoma (FMC) represent an excellent model for the TNBC. Aim of this work is to evaluate the expression of mTOR and phospho mTOR (p-mTOR) in FMC samples in comparison with the ER/PR/HER2 phenotype.

**Materials and methods:** Immunohistochemical expression of mTOR, p-mTOR, ER $\alpha$ , PR and HER2 was evaluated on 9 benign lesions, 56 FMC and 4 metastasis. Proteic expression of mTOR and p-mTOR by western blot analysis was performed of 6 FMC cell lines.

**Results:** mTOR positivity was found in 27% of benign lesions, 55.56% of FMC and all metastases analyzed. p-mTOR immunolabelling was present in 27% of benign lesions, 52% of FMCs and all metastases analyzed. Triple negative phenotype resulted statistically associated to mTOR and p-mTOR. Western blot analysis revealed that 5/6 cell lines expressed mTOR with higher expression in metastatic ones.

**Conclusion:** mTOR plays an important role in the pathogenesis of FMC and its high expression in TNFMC confirms FMC as suitable model for the development of new therapeutic strategies in comparative oncology.

## O6- TARGETING CANCER STEM CELLS IN CANINE MAMMARY CANCER

*Pereira D<sup>1</sup>, Vieira AF<sup>2</sup>, Schmitt F<sup>2,3</sup>, Paredes J<sup>2,3</sup>, Gama A<sup>1</sup>*

*1 University of Trás-os-Montes and Alto Douro, CECAV, Vila Real, 2 IPATIMUP, Porto; 3 Faculty of Medicine of the University of Porto, Porto, Portugal, danismpereira@gmail.com.*

**Introduction:** Mammary gland tumours represent an important disease in female dogs. Currently, the cancer stem cell (CSC) hypothesis is being explored in cancer research field. With this study, we intended to expand the knowledge on CSC in canine mammary cancer, hopefully providing new insights into canine mammary carcinogenesis.

**Materials and methods:** By using an in vitro approach (three mammary tumour cell lines), we have isolated cells with stem-like properties, by using a mammosphere formation assay. A phenotypical characterization by flow cytometry, immunofluorescence and western blot has been performed, as well as functional assays. In addition, we have evaluated the immunohistochemical expression of CSC markers (ALDH1, CD24, CD44) in 111 canine mammary carcinomas (CMC).

**Results:** The preliminary results show that all cell lines are able to grow as spheroids in anchorage-independent conditions, present ALDH1 activity (ALDEFLUOR assay) and express CSC markers. Most CMC were CD44 positive (81.1%) and ALDH1 expression was frequently observed (35.6%). No association was observed between CSC marker positive expression and aggressive tumour behaviour.

**Discussion and conclusions:** Our results further consolidate the stem cell theory in this animal model; however, the expression of CSC markers in CMC requires additional studies in order to better define their prognostic value.

## **O7- IS BAG3 PROTEIN INVOLVED IN AUTOPHAGIC MECHANISMS IN PAPILOMAVIRUS- ASSOCIATED UROTHELIAL TUMORS IN CATTLE?**

*Roperto S, Paciello O, Borzacchiello G, Esposito I, Riccardi M, Lucà R, Urraro C, Ceccarelli DM, Russo V, Roperto F*

*Department of Pathology and Animal Health, Faculty of Veterinary Medicine, Naples, Italy, iolanda979@yahoo.it*

**Introduction:** BAG3 appears to be involved in many biological processes such as apoptosis, development, cytoskeleton organization and, recently, autophagy. Autophagy has been shown to play an important role in the pathogenesis of several viral infections; it is known that many viruses are able to evade, subvert, or exploit autophagy, seemingly to insure their own replication or survival advantage. The aim of this study is to investigate the role, if any, of BAG3 in cancer urothelial cells infected with bovine papillomavirus type 2.

**Materials and Methods:** Twenty-five urothelial tumors of the urinary bladder of cattle were investigated. All of them were positive for E5, the major oncoprotein of bovine papillomavirus type-2.

**Results:** Bag3 protein appears to be overexpressed in all of urothelial tumors and to be a biochemical partner with E5. In addition, Bag3 forms a stable complex with HSP70 and HSPB8. Furthermore, there was an increase in the expression of both total and phosphorylated eIF2 alpha factors and LC3II. p62 protein was downregulated.

**Discussion & Conclusion:** These findings suggest the possibility that BAG3 might be involved in chaperone-mediated autophagy (CMA) in papillomavirus-associated urothelial tumors in cattle via eIF2 $\alpha$  phosphorylation, known to play a central role in autophagy and cell survival.

## **08- A COMPREHENSIVE PATHOLOGICAL STUDY ON BOVINE ADRENAL GLAND TUMOURS.**

*Capucchio MT, Biasibetti E, Deideri F, Rocha PRD, Giorcelli J<sup>1</sup>, Bianco P<sup>2</sup>, Valenza F, Guarda F, Volante M<sup>1</sup>.*

*Dept. Animal Pathology, 1 Dept. Clinical and Biological Sciences, University of Turin; 2 ASLTo4, Italy, mariateresa.capucchio@unito.it*

**Introduction:** Adrenal gland tumours (AGT) in cattle are reported as incidental findings at slaughter, but their pathological characterization is poor. Aim of this work is to describe morphological and immunohistochemical features of a large series of AGT.

**Materials and Methods:** From years 2004 to 2011, 39 adrenal glands having macroscopically evident proliferative lesions were collected in a slaughterhouse of the North of Italy. H&E stain and immunostainings for vimentin, pan-cytokeratin, melan A, chromogranin A, synaptophysin, neurofilaments and Ki-67 were performed.

**Results:** Proliferative lesions were classified as focal hyperplasias (8 cases – 20.5%), primary tumours (18 involving the cortex and 9 the medulla – 69%) or secondary tumours (4 cases – 10%). On the basis of morphological features, cortical tumours were classified in five subtypes of carcinomas. Medullary tumours included 2 pheochromocytomas and 7 neuroblastomas. Immunohistochemically, all carcinomas focally stained for both vimentin and pan-cytokeratin; melan A was positive in a small subset of cases. Only one pheochromocytoma was vimentin and chromogranin A positive. All neuroblastomas labeled positive for neurofilaments, vimentin, chromogranin A and synaptophysin.

**Discussion & Conclusion:** The incidence of carcinomas (0.48%) was higher than that reported in the literature (0.05-0.03%). The tumours analyzed showed a heterogeneous profile, that only partially overlapped with the spectrum of pathological findings encountered in humans.

## **O9- CANINE DIGIT SQUAMOUS CELL CARCINOMA: epidemiological, histological and immunohistochemical study**

*Belluco Sara, Brisebard Elise, Watrelot Dorothee, Marchal Thierry, Ponce Frédérique.*

*ICE, 2007-07-113, VetAgro-Sup, Marcy l'Etoile, France; sara.belluco@vetagro-sup.fr.*

**Introduction:** Canine digit squamous cell carcinoma (CDSCC) is the most common tumor involving the digit. It has some particular characteristics as the local invasiveness, the possible multicentric development and a low metastatic potential. Owners which are faced to multiple consecutive tumors or distant metastasis often decide to euthanize their dogs. At the moment, the only relying factor to predict the outcome is the histological grading. In oncology, the epithelial mesenchymal transition is related to the acquisition of invasiveness properties of tumoral cells: they loose the epithelial-marker expression and acquire a mesenchymal phenotype. This is the first large scale study which compare the tumor phenotype with the prognosis and try to find some prognostic markers.

**Materials and Methods:** Samples belonging to 49 dogs were collected and analyzed histologically and immunohistochemically for the expression of pancytokeratin AE1/AE3, Vimentin and E-cadherin. For each animal, epidemiological and clinical follow-up data were recorded. Results were correlated to the clinical outcome.

**Results:** Beauceron was among the three most overrepresented breeds; the forelimb was twice more affected than the hind-limb. The histological grade, the mitotic index and the expression of immunohistochemical markers were not correlated to the prognosis (local recurrence or metastasis).

**Conclusion:** Neither the histological grading nor the EMT phenotype seem to be useful tools to define CDSCC prognosis.

## O10- IMMUNOHISTOCHEMICAL DETECTION OF THE BCL-2 FAMILY MEMBERS BAK AND BAX IN CANINE LYMPHOMA

*Croci M, Guscetti F*

*University of Zurich, Switzerland, [martina.croci@access.uzh.ch](mailto:martina.croci@access.uzh.ch)*

**Introduction:** The pro-apoptotic Bcl-2 family members Bak and Bax are essential for intrinsic apoptosis. Loss of expression of one or both of these proteins might contribute to tumorigenesis through impairment of apoptosis. In this study we validated antibodies for the immunohistochemical detection of these proteins in canine tissues and investigated their expression in lymphoma samples from dogs.

**Materials and Methods:** Commercially available antibodies against Bak and Bax were selected and validated based on their reactivity with canine recombinant proteins and with the endogenous proteins in UV-treated canine keratinocytes and non-neoplastic tissues using Western blots and immunohistochemistry. The expression of these proteins was then assessed by immunohistochemistry in a series of previously classified lymphomas assembled in tissue arrays. Correlations of the expression of Bak and Bax with the immunophenotype and with previously investigated apoptosis-related markers were analysed.

**Results:** Immunolabelling of canine lymphomas showed a cytoplasmic signal for both proteins. The degree of immunoreactivity widely varied between tumours and was independent of the immunophenotype. Bax immunolabelling as assessed with two independent antibodies correlated in both cases positively with the number of active caspase-3 positive cells and negatively with immunolabelling for Bcl-x.

**Discussion and Conclusion:** Immunohistochemical data indicate that canine lymphomas variably express pro-apoptotic proteins Bax and Bak. The association of Bax expression with apoptotic activity suggests a potential role of this protein with lymphomagenesis in dogs.



## O11- MACROPHAGES AND T CELLS INFILTRATION IN FELINE ENDOMETRIAL ADENOCARCINOMAS

*Tavares Pereira M<sup>1</sup>, Payan-Carreira R<sup>1</sup>, Saraiva AL<sup>1,2</sup>, Pires MA<sup>1</sup>*

*1 CECAV-ECAV-UTAD, Vila Real, Portugal, apires@utad.pt, 2 EUVG, Coimbra, Portugal*

**Introduction:** Although considered rare tumours, our studies showed that feline endometrial adenocarcinomas (FEA) seem to be more frequent than once thought. Aware of the importance of the immune system through tumour immunoediting, this study aims to assess the infiltration of immune cells in FEA.

**Material and Methods:** 10 samples of papillary serous FEA (classified at hematoxylin-eosin sections) were used, along with 6 samples of each in follicular and progestagenic stages of the oestrous cycle (controls). Immunolabelling was performed using antibodies against macrophages and T cells (MAC 387, Ab-Serotec®, 1:100 and CD3, Dako®, 1:50). Immune cells were counted in hot spots, within the tumour and in the peripheral stroma.

**Results:** In tumours, T cells were predominant over the macrophages, but both cell types were increased towards controls. Also, different distribution pattern was found in follicular and progestagenic stages; in the former T-cells were abundant in the superficial layer whilst in the later they predominate in deeper endometrial layers.

T-cells and macrophages were significantly increased in the tumours ( $P < 0,05$ ), but while an increased number of T cells were observed in the stroma surrounding the tumors, here the macrophages were scarce.

**Discussion and Conclusion:** The immune cells studied in this work were significantly more numerous in papillary serous FEA than in cyclic uterus. Further, T cells predominate over macrophages, in both intratumoural location and surrounding tissues.

## O12- ASSAY OF STANDARDIZATION FOR IMMUNOHISTOCHEMICAL COX-2 STAINING

*Belluco Sara<sup>1</sup>, Castagnaro Massimo<sup>2</sup>, Carnier Paolo<sup>2</sup>, Chiers Koen<sup>3</sup>, Millanta Francesca<sup>4</sup>, Peña Laura<sup>5</sup>, Queiroga Felisbina<sup>6</sup>, Pires Isabel<sup>6</sup>, Riffard Sylvaine<sup>7</sup>, Scase Tim<sup>8</sup>, Polton Gerry<sup>9</sup>*

*1 VetAgro Sup, Marcy L'etoile, France ; 2 Faculty of Veterinary Medicine, Legnaro, Italy. 3 Faculty of Veterinary Medicine, UGent, Belgium. 4 School of Veterinary Medicine, Pisa, Italy. 5 Veterinary School, Complutense University Madrid, Spain. 6 University of Trás-os-Montes and Alto Douro, Alto Douro, Portugal. 7 Merial, Lyon. 8 Bridge Pathology Ltd., Bristol, United Kingdom. 9 North Downs Specialist Referrals, Surrey, United Kingdom. sara.belluco@vetagro-sup.fr;*

**Introduction:** Immunohistochemical analysis (IHC) of Cox-2 expression in tumoral cells is widely reported. Despite similarities between studies, results are difficult to compare. The aim of our study was to define a Cox-2 IHC technique that could achieve clinically plausible and comparable results in different pathology laboratories.

**Materials and Methods:** Contiguous slides coming from 15 colorectal tumors, 15 oral squamous cell carcinomas and positive control slides from 1-day-old puppy kidney were stained in eight European laboratories. Repeatability and reproducibility of staining were evaluated and statistically analyzed.

**Results:** Marked interlaboratory and intralaboratory variability was demonstrated using a standard technique. The technique was modified by inclusion of a new positive control tissue. Upper and lower limits of stain intensity were defined. Repeatability was achieved, while reproducibility was not.

**Conclusion:** The inclusion of positive control tissue with defined degrees of IHC positivity allows repeatability of the staining. Unfortunately, reproducibility remains a goal to be attained. Presently, our study indicates that comparison of results between different laboratories should not be done.

### **O13- TERATOGENIC EFFECTS OF SCHMALLEMBERG VIRUS INFECTION IN SHEEP AND CATTLE**

*Peperkamp K, Wouda W, Dijkman R, Greijdanus S, Junker K, Roumen T, Vos J.*

*Animal Health Service, Deventer, the Netherlands. k.peperkamp@gddeventer.com*

**Introduction:** Schmalleberg virus (SBV), a novel virus of the genus Orthobunyavirus, was identified as the cause of an emerging disease in ruminants in Europe in 2011. After a period of an unidentified outbreak of fever and milk drop on dairy farms in the Netherlands and Germany congenital malformations in sheep and calves were recorded. SBV was discovered by metagenomic analysis (Friedrich-Loeffler-Institute, Insel Riems, Germany) in blood samples from febrile cows. RT-qPCR confirmed the presence of SBV in brain tissue of malformed lambs and calves.

**Materials and Methods:** 102 lambs and 205 calves, exhibiting congenital lesions, were selected for detailed description of gross and microscopic lesions. Brain, spinal cord, skeletal muscles and various organs were sampled for histological examination. Part of the brainstem was used for detection of SBV by RT-qPCR.

**Results:** In both lambs and calves gross lesions included various degrees of hypoplasia of the CNS, resulting in micrencephaly, porencephaly, hydranencephaly, cerebellar hypoplasia and hypoplasia of the spinal cord. Microscopically cerebral cavitation, depletion of the cerebellar granule cell layer and loss of ventral motorneurons in the spinal cord were the most striking lesions. Musculoskeletal changes consisted of arthrogryposis, mild to marked deformation of the vertebral column and muscular atrophy.

**Discussion and conclusion:** In 2011 a congenital arthrogryposis-hydranencephaly syndrome in cattle and small ruminants emerged in north-west Europe, caused by teratogenic effects of SBV-infection.

**O14- “LOUPING ILL” IN GOAT IN NORTHERN SPAIN: MORE THAN A FORGOTTEN DISEASE**

*Balseiro A<sup>1</sup>, Royo LJ<sup>1</sup>, Pérez C<sup>2</sup>, Copano MF<sup>3</sup>, Rubio T<sup>3</sup>, Höfle U<sup>4</sup>, Prieto M<sup>1</sup>, García Marín JF<sup>2</sup>*

*1 SERIDA, Gijón, Spain; 2 University of León, Spain; 3 LAPSA, Gijón, Spain; 4 IREC, Ciudad Real, Spain, abalseiro@serida.org*

**Introduction:** Louping ill (LI) is a zoonotic disease caused by a neurotropic single-strand RNA virus that has been classified into the Flavivirus genus. We report the case of a “Bermeya” goat herd of 70 animals from Asturias, suspected of being infected with a tick-borne encephalitis virus.

**Materials and Methods:** Eighteen goats died showing neurological clinical signs. Necropsy was performed in two adult goats. Samples of brain were taken for further histopathological and molecular genetic (RT-PCR and sequencing) studies. In order to confirm the importance of the infection, a serological survey (ELISA) was performed in 178 goats belonging to seven herds geographically close to the affected one.

**Results:** The cerebellum showed necrosis of Purkinje cells and neurons. A mild meningeal infiltration with widespread lymphocytic perivascular cuffs, phenomena of neurophagia and gliosis was observed mainly in the hypothalamus region and midbrain, being more severe in the medulla oblongata and cervical spinal cord. Molecular genetic studies identified the virus as a LI strain not described so far. Histopathological lesions together with molecular studies allowed a complete diagnosis: tick-borne encephalitis caused by a new strain of LI virus. The serological survey confirmed the infection in 5.06% of the animals studied.

**Discussion & Conclusions:** These findings underline the necessity to implement a specific surveillance plan in Northern Spain focused on ticks, wildlife species and livestock.

## **O15- EFFECT OF TWO STRAINS OF PRRSV ON THE EXPRESSION OF DIFFERENTIATION ANTIGENS OF MONOCYTE-DERIVED DENDRITIC CELLS**

*Rodríguez-Gómez IM<sup>1</sup>, Burgara-Estrella AJ<sup>2</sup>, Mateu E<sup>2</sup>, Gómez-Laguna J<sup>3</sup>, Carrasco L<sup>1</sup>, Saalmüller A<sup>4</sup>, Käser T<sup>4</sup>*

*1 University of Córdoba, Spain; 2 Autonomous University of Barcelona, Spain; 3 CICAP, Pozoblanco, Córdoba, Spain; 4 Institute of Immunology, Vienna University, Austria.*

**Introduction:** Porcine Reproductive and Respiratory Syndrome (PRRS) is one of the most economically important diseases in swine industry. The causal agent, PRRS virus (PRRSV), comprises two different genotypes, European genotype and American genotype, with strains of diverse virulence. The basis for viral virulence and the determinants facilitating viral escape from the control of the immune system are not well understood. It is known that PRRSV infects antigen presenting cells (APC) and the study of the interaction of PRRSV and APC may be relevant to improve the current knowledge on the pathogenesis of this disease.

**Materials and Methods:** Monocyte-derived dendritic cells (MoDCs) were infected with two either a European or an American PRRSV strain, and the impact of the infection onto CD1, CD14, CD80/86, CD172a, and MHC-II expression in a kinetic (from 0 up to 48 hours-post inoculation(hpi)) was assessed by means of flow cytometry.

**Results:** The results showed that MoDC were permissive for both strains although the percentage of infected MoDC differed, being higher for the European strain. CD172a and CD14 expression decreased progressively over time for both strains. In case of CD80/86 and MHC-II, the highest decrease was observed at 48hpi.

**Discussion & Conclusion:** Infection of MoDC by PRRSV can lead to a severe disturbance of immune reactions. The decreased expression of MHC-II and co-stimulation molecules could contribute to explain the immunosuppressive capacity of PRRSV.

**O16- A VIRULENT EASTERN EUROPEAN PRRSV STRAIN INDUCES HIGH LEVELS OF IL-1 $\alpha$  IN THE LUNG**

*Amarilla S.P<sup>1</sup>, Morgan S<sup>3</sup>; Gómez-Laguna J<sup>2</sup>, Graham S<sup>3</sup>, Frossard JP<sup>3</sup>, Steinbach F<sup>3</sup>, Carrasco L<sup>2</sup>, Salguero FJ<sup>3</sup>.*

*University of Córdoba, Spain. shyroleypaola@yahoo.com.ar*

**Introduction:** Porcine reproductive and respiratory syndrome (PRRS) is the most economically important disease of swine, with the emergence of highly pathogenic PRRS viruses in both Asia and Europe. In this study we correlate the histological changes, viral antigen and IL-1 $\alpha$  expression in the lungs of pigs experimentally infected with different genotype I strains.

**Materials and Methods:** Ninety-six 5-week-old pigs were inoculated with 1) Lelystad prototype virus; 2) 215-06 British field strain; 3) Su1-Bel strain from a farm with poor health status in Belarus; 4) a commercial modified live vaccine; 5) control mock-infected. Animals were euthanized at 3, 7 and 35 dpi. Histopathology, PRRSV and IL-1 $\alpha$  expression were detected by immunohistochemistry.

**Results:** Su1-Bel infected animals showed the most severe clinical signs and the highest gross pathology lung scores. This group also displayed the highest number of PRRSV infected cells in the lungs at 7 dpi. Moreover, the expression of IL-1 $\alpha$  was significantly increased in this group at 3 and 7 dpi while there were no differences between the other groups.

**Discussion & Conclusion:** The virulent Eastern European strain of PRRSV induced higher levels of infection and expression of IL-1 $\alpha$  in the lung when compared to the prototype genotype I (Lelystad) strain and the British field isolate.

## O17- IMMUNE PHENOTYPING OF PLACENTAS FOLLOWING EXPERIMENTAL INOCULATION WITH NEOSPORA CANINUM DURING PREGNANCY.

*Cantón Germán<sup>1,2</sup>, Benavides Julio<sup>1,3</sup>, Maley Stephen<sup>1</sup>, Katzer Frank<sup>1</sup>, Palarea-Albaladejo Javier<sup>4</sup>, Bartley Paul<sup>1</sup>, Rocchi Mara<sup>1</sup>, Innes Elizabeth<sup>1</sup>, Chianini Francesca<sup>1</sup>*

*1 Moredun Research Institute, Scotland, 2 INTA, Argentina, 3 Instituto de Ganadería de Montaña, Spain, 4 BioSS, Scotland. german.canton@moredun.ac.uk*

**Introduction:** Despite *Neospora caninum* (NC) being a major cause of bovine abortion worldwide, its pathogenesis is not completely understood. NC stimulates host cell-mediated immune responses, which may be responsible for placental damage leading to abortion. The aim of our studies was to characterise placental immune responses following experimental infection during pregnancy.

**Materials and Methods:** Cows were infected with NC at day 70, 140 and 210 of pregnancy and culled at 14, 28, 42 and 56 days post inoculation. Placentomes were examined by immunohistochemistry using antibodies against macrophages, T-cells (CD3, CD4, CD8,  $\gamma\delta$ TCR), NK and B cells.

**Results:** Inflammation at early gestation was generally moderate to severe. Meanwhile at mid gestation, inflammation was mild to moderate and scarce to mild at late gestation. Cellular infiltrates were mainly characterised by the presence of CD3+, CD4+ and  $\gamma\delta$  T-cells; whereas CD8+ and NK cells were less numerous. Macrophages were detected in increasing numbers during later time-points after infection.

**Discussion:** The distribution of the cellular subsets observed in the studies was similar. However, cellular infiltrates were more severe following infection during the first trimester in comparison to second and third trimester infections. This may explain the milder clinical outcome observed when animals are infected at mid or late gestation.

**O18- TOXOPLASMOSIS: DOES RECRUDESCENCE OCCUR IN A FLOCK IN BREEDING SEASONS AFTER AN OUTBREAK?**

*Edwards, John F.<sup>1</sup> Dubey Jitander P.<sup>2</sup>*

*1 Texas A&M University College Station Texas, USA, 2 USDA, Agricultural Research Service, Animal and Natural Resources Institute, Beltsville, Maryland, USA*

**Introduction:** The question of whether toxoplasmosis will reoccur in a ewe in subsequent seasons or whether toxoplasma abortion confers a protective immunity is an unresolved, disputed question.

**Materials and Methods:** A small closed Suffolk sheep flock was studied for re-occurrence of toxoplasmosis after an outbreak where 28/41 ewes lost lambs due to toxoplasmosis. The next breeding year, lambs' precolostral sera were tested for Toxoplasma antibody, and the etiology of any newborn lamb losses were investigated for abortifacients including Toxoplasma. Ewe serum titers were compared annually. The flock was monitored for six years.

**Results:** Besides new females reaching maturity in this closed flock, twenty-three of the original 41 animals were studied. Of ewes bled in the previous year, all were still Toxoplasma seropositive, but titers had declined. Only 1 ewe with a toxoplasma titer of 1:3200 and that had lost her lamb the previous year aborted a lamb from which a virulent *T. gondii* was isolated. Other ewes lambled normally. Some lambs were lost due to non-Toxoplasma-related conditions. Except for normal lambs from 3 ewes that may have suckled, precolostral sera had no Toxoplasma antibodies. In subsequent years, abortions were not a problem in the flock, and most of the original ewes had 1-3 normal lambs for 2-4 seasons after the abortion outbreak.

**Discussion:** The low incidence in view of the virulent isolate acting in this herd is significant. The results support the hypothesis that most sheep that have aborted due to *T. gondii* develop protection against future toxoplasmosis-induced abortion.



## O19- NEW INSIGHTS INTO IMMUNOPATHOLOGICAL FORMS OF BOVINE PARATUBERCULOSIS

Vázquez P<sup>1</sup>, Garrido JM<sup>1</sup>, Pérez V<sup>2</sup>, Juste RA<sup>1</sup>.

1 NEIKER-Tecnalia, Derio, Spain, 2 University of León, León, Spain.  
rjuste@neiker.net

**Introduction:** Paratuberculosis is a complex disease. Here, we report a simplified classification of immunopathological forms of bovine paratuberculosis based on serological, microbiological and pathological findings and their implications on epidemiology and disease control.

**Materials and Methods:** We examined 1,031 slaughtered adult Friesian cattle by ELISA for serum antibodies, by isolation and PCR for *Mycobacterium avium* subsp. paratuberculosis (MAP) detection in tissues, and by histopathological examination.

**Results:** The 5 immunopathological forms (Gonzalez et al., 2005) were grouped into latent (delimited focal lesions), accounting for 38.9% of the animals, and patent (delimited multifocal and diffuse lesions), affecting 7.7%. Humoral responses were mostly related to patent forms (69.7%). MAP detection and viability rates increased with tissue damage extension. Age-pattern differed between forms. Latent forms frequencies were relatively constant throughout adulthood whereas patent forms sharply decreased beyond 4 years of age. No wasting or reduced lifespan was observed in latent forms. Carcass weight was strongly reduced in cows with high bacterial loads (22.2%) or diffuse enteritis (26.0%). Lifespan was nearly one year shorter in ELISA-positive or diffuse forms. Diffuse lymphocytic forms showed the shortest and less variable lifespan (37±4.5 months).

**Discussion and Conclusion:** Latent infections might represent forms of resistance because of reduced extension and low MAP viability rate. Patent forms had higher rates of bacterial viability, occupied larger sections of the intestine and were associated with shorter lifespan and smaller weight.

Funded by the Ministerio de Ciencia e Innovación, Spain (AGL2006-14315-CO2)

## O20- HISTOPATHOLOGICAL, IMMUNOHISTOCHEMICAL AND MOLECULAR STUDIES ON NATURALLY OCCURRING PARATUBERCULOSIS IN SHEEP

Sonawane G. G., Tripathi B. N.

Animal Health Division, Central Sheep and Wool Research Institute, Avikanagar, Rajasthan- 304501, India, [bntripathi1@yahoo.co.in](mailto:bntripathi1@yahoo.co.in)

**Introduction:** Paratuberculosis, caused by *Mycobacterium avium* subspecies *paratuberculosis* (MAP) is an economically important disease of ruminants. In this study histopathological, immunohistochemical and molecular studies were carried out in MAP infected sheep.

**Materials and Methods:** Tissues of 56 sheep from an endemically infected organized flock were used for histopathological studies. Immunoperoxidase, and conventional and quantitative polymerase reactions (qPCR) were carried out for demonstration of MAP antigen or its genome.

**Results:** All 56 sheep were classified as paucibacillary (PB=18) or multibacillary (MB=38) on the basis of histopathology and mycobacterial loads. In PB sheep, small intestinal mucosa was predominantly infiltrated with large number of lymphocytes amid which focal to multifocal granulomas with occasional acid-fast bacilli and multinucleated giant cells were observed. Focal to multiple small granulomas were also observed in the mesenteric lymph nodes (MLN) of sheep. In MB sheep, microscopic lesions were characterised by diffuse infiltration of epithelioid macrophages loaded with clusters of AFB in the intestinal mucosa. Positive immunolabeling for MAP was observed in 55.6% (10/18) and 77.8% (14/18) in PB and MB cases, respectively. The IS900 gene PCR detected 13.3% (2/15) of PB and 85.7% (24/28) of MB sheep. The qPCR detected 100% of PB (15/15) and MB (23/23) sheep tested.

**Discussion and conclusion:** In the present study, characteristic histological changes of PB and MB sheep were described for postmortem diagnosis of paratuberculosis. Immunohistochemical staining and qCR were sensitive methods in confirming PB cases with scarce or no bacilli.

## O21- HISTOPATHOLOGICAL FINDINGS IN DOGS WITH “HAEMORRHAGIC GASTROENTERITIS”.

*Leipzig Miriam<sup>1</sup>, Busch Kathrin<sup>2</sup>, Unterer Stefan<sup>2</sup>, Hermanns Walter<sup>1</sup>*

*1 Institute of Veterinary Pathology and 2 Clinic of Small Animal Internal Medicine, Ludwig-Maximilians-University Munich, Germany, leipzig@patho.vetmed.uni-muenchen.de*

**Introduction:** Haemorrhagic gastroenteritis (HGE) in dogs is a disease syndrome of unknown cause characterized by acute onset of bloody diarrhoea, vomiting and haemoconcentration. In previous studies histopathological investigations have been restricted to post mortem examinations. The aim of this study was to describe distribution, character and degree of histopathological lesions in prospectively collected biopsy samples from dogs with HGE.

**Materials and Methods:** After excluding well-known causes of haemorrhagic diarrhoea, samples of stomach, duodenum, ileum and colon were taken endoscopically from 10 acute diseased dogs and investigated histologically (H&E, Giemsa) and immunohistochemically (Parvovirus, Clostridium sp.).

**Results:** A chronic gastritis was found in 9/10 cases. A necrotizing inflammation was present in 9/10 cases in the small intestine and in 8/9 cases in the large intestine. The degree of lesions increased in the caudal part of the intestinal tract. In 9/10 cases clostridial antigen-positive bacteria were found on the surface of the necrotic mucosa in at least one localisation.

**Conclusion:** Main finding in dogs with HGE was an acute necrotizing enterocolitis with detection of Clostridium sp.. Chronic inflammation in the stomach is not interpreted to be in context of the acute haemorrhagic diarrhoea.

## O22- PREVALENCE AND RISK FACTOR ANALYSIS OF FELINE HAEMOPLASMA INFECTION IN NEW ZEALAND DOMESTIC CATS

*Dittmer KE<sup>1</sup>, Jenkins KS<sup>1</sup>, Kwan E<sup>1</sup>, Marshall JC<sup>1</sup>, Tasker S<sup>2</sup>*

*1 Institute of Veterinary, Animal and Biomedical Sciences, Massey University, Palmerston North, New Zealand, 2 School of Veterinary Sciences, University of Bristol, Langford, United Kingdom. K.E.Dittmer@massey.ac.nz*

**Introduction:** The aim of this study was to evaluate feline haemoplasma prevalence and possible risk factors for infection in New Zealand cats.

**Materials and Methods:** Species specific real-time polymerase chain reaction (qPCR) assays were performed on DNA extracted from 200 feline blood samples submitted to a diagnostic laboratory for routine haematology over a 12 month period. All 200 blood samples were also tested for retroviral infection using the IDEXX SNAP Feline Triple test.

**Results:** Of the 200 samples, 62 cats (31%) were positive for haemoplasma DNA; 49 (24.5%) for '*Candidatus Mycoplasma haemominutum*' (CMhm), 15 (7.5 %) for *Mycoplasma haemofelis* (Mhf), and 9 (4.5%) for '*Candidatus Mycoplasma turicensis*' (CMt). Twelve of the positive cats had dual infections; 11 CMhm/Mhf and one CMhm/CMt. All samples were adequately positive for the internal control (feline 28S rDNA) by qPCR. Of the 200 samples, 20 cats (10%) were FIV positive, 11 cats (5.5%) were FeLV positive. Multivariate logistic regression, indicated that positive FIV status (odds ratio (OR) 10.16), male gender (OR 5.04) and non-pedigree breed (OR 3.03) were significantly ( $P < 0.05$ ) associated with haemoplasma infection.

**Discussion:** The results of this study demonstrate that New Zealand feline haemoplasma prevalence is similar to previous overseas studies, with CMhm being the most common infection.

## **O23- PATHOGENESIS AND TRANSMISSIBILITY OF HIGHLY AND LOW PATHOGENIC AVIAN INFLUENZA VIRUS INFECTION IN COMMON QUAIL (*Coturnix coturnix*)**

*Kateri Bertran<sup>1</sup>, Roser Dolz<sup>1</sup>, Núria Busquets<sup>1</sup>, Virginia Gamino<sup>2</sup>, Júlia Vergara-Alert<sup>1</sup>, Aida Jeanette Chaves<sup>1</sup>, Antonio Ramis<sup>1,3</sup>, Francesc Xavier Abad<sup>1</sup>, Ursula Höfle<sup>2</sup>, Natàlia Majó<sup>1,3</sup>*

*1 Centre de Recerca en Sanitat Animal (CRESA), Bellaterra, Spain. 2 Universitat Autònoma de Barcelona, Bellaterra, Spain. 3 Instituto de Investigación en Recursos Cinegéticos, Ciudad Real, Spain. natalia.majo@cresa.uab.cat*

**Introduction:** In the present study, an experimental infection with different avian influenza viruses (AIV) was carried out in common quails (*Coturnix coturnix*) to elucidate its epidemiological role in the ecology of this viral infection.

**Materials and Methods:** Quails were intranasally infected with two highly pathogenic AIV (HPAIV) (subtypes H7N1 and H5N1) and one low pathogenic AIV (LPAIV) (subtype H7N2). Clinical signs were daily recorded and samples were obtained to quantify viral load by real time RT-PCR (RRT-PCR). Birds of each infected group were euthanized at different days post-infection (dpi) and tissue samples were obtained for histopathological and immunohistochemical (IHC) studies.

**Results:** Severe neurological signs and mortality were observed in both HPAIV groups. Presence of viral antigen and microscopic lesions in tissues, especially brain and pancreas, was observed in HPAIV infected birds. On the contrary, neither clinical signs nor histopathological findings were observed in LPAIV infected quails. Significant and long-term viral shedding was confirmed by RRT-PCR in all infected groups.

**Discussion1:** The present study demonstrates that common quails play a major role in the AI epidemiology, not only for their high susceptibility, but also for the associated viral shed

## **O24- TISSUE TROPISM AND PATHOLOGY OF NATURAL INFLUENZA VIRUS INFECTION IN BLACK-HEADED GULLS (CHROICOCEPHALUS RIDIBUNDUS)**

*Ursula Höfle<sup>1, 2</sup>, Marco van de Bildt<sup>2</sup>, Lonneke Leijten<sup>2</sup>, Josanne H. Verhagen<sup>2</sup>, Ron A. M.Fouchier<sup>2</sup>, Albert Osterhaus<sup>2</sup>, Thijs Kuiken<sup>2</sup>*

*1 Instituto de Investigación en Recursos Cinegéticos IREC (CSIC-UCLM-JCCM), Ciudad Real, Spain. Ursula.hofle@uclm.es, 2 Department of Virology, Erasmus Medical Center, Rotterdam, The Netherlands.*

**Introduction:** Black-headed gulls (*Chroicocephalus ridibundus*) are a suitable model to unravel the epidemiology of low pathogenic avian influenza virus (LPAIV) infection in wild waterbirds because they are a common colony-breeding species in which LPAIV infection is limited mainly to the H13 and H16 subtypes. However, the sites of virus replication and associated lesions are poorly understood.

**Material and methods:** We performed virological and pathological analyses on tissues of black-headed gulls naturally infected with LPAIV.

**Results:** We found that 24 of 111 black-headed gulls collected from breeding colonies were infected with LPAIV (10 X H16N3, 1 X H13N8, 13 X undetermined), based on virus and viral genome detection in pharyngeal and cloacal swabs. Of these 24 gulls, 15 expressed virus antigen in their tissues. Virus antigen expression was limited to epithelial cells of intestine and cloacal bursa. No histological lesions were detected in association with virus antigen expression.

**Discussion & Conclusion:** Our findings show that LPAIV in black-headed gulls is mainly a superficial intestinal tract infection in absence of detectable lesions. These findings imply that LPAIV in black-headed gulls has adapted to fecal-oral transmission with minimal pathogenicity to its host.

## O25- PATHOLOGIC AND IMMUNOHISTOCHEMICAL FINDINGS IN EYES OF FLAVIVIRUS INFECTED GAME BIRDS

*Gamino Virginia<sup>1</sup>, Gutiérrez-Guzmán A.Valeria<sup>1</sup>, Escribano-Romero Estela<sup>2</sup>, Blázquez Ana-Belén<sup>2</sup>, Saiz Juan-Carlos<sup>2</sup>, and Höfle Ursula<sup>1</sup>*

*1 Instituto de Investigación en Recursos Cinegéticos IREC (CSIC-UCLM-JCCM), Ciudad Real, Spain. 2 Departamento de Biotecnología, INIA, Madrid, Spain.  
[Virginia.gamino@uclm.es](mailto:Virginia.gamino@uclm.es)*

**Introduction:** Flaviviruses such as West Nile virus (WNV) and Bagaza virus (BagV) have shown to be pathogenic for game birds such as red-legged partridges (*Alectoris rufa*) and common pheasants (*Phasianus colchicus*). WNV frequently produces photophobia in raptors and BagV infected birds show apparent blindness. Using immunohistochemistry and histology we studied ocular lesions and antigen distribution in red-legged partridges experimentally infected with WNV and in red-legged partridges and common pheasants naturally infected with BagV.

**Material and methods:** Cross sections of eyes from euthanized or dead birds were examined microscopically. A polyclonal antibody against the envelope protein of WNV was used for antigen detection.

**Results:** In both infections, inflammatory infiltrates were present in different parts of the eye, although pectenitis was only present in birds infected with BagV. In WNV infected partridges, viral antigen was detected in endothelial cells throughout the eye and in the rods and cones layer of the retina. BagV antigen was present in the endothelial cells of the pecten (only in partridges) and in different cells of the retina.

**Discussion & Conclusion:** This is the first time that ocular lesions caused by WNV are described in gallinaceous birds. Detection of BagV antigen in the retina may be responsible for the apparent blindness observed.

**O27- PROLIFERATIVE KIDNEY DISEASE – AN EMERGING DISEASE INFLUENCED BY GLOBAL WARMING?**

*Schmidt-Posthaus, Heike<sup>1</sup>, Bettge, Kathrin<sup>2</sup>, Sattler, Ursula<sup>1</sup>, Wahli, Thomas<sup>1</sup>*

*1Centre for Fish and Wildlife Health, University of Bern, Switzerland. 2Aqua-Sana, Switzerland. heike.schmidt@vetsuisse.unibe.ch*

**Introduction:** Proliferative kidney disease (PKD) is an emerging temperature related disease of salmonids caused by *Tetracapsuloides bryosalmonae*. In young-of-the-year (YOY) high mortality occurs when water temperature exceeds 15°C.

**Material and Methods:** Since 2000, more than 8'000 YOY brown trout have been sampled in rivers across Switzerland. Necropsies, histopathology, immunohistochemistry and PCR were performed to diagnose PKD or other infectious diseases. Additionally, experimental infection studies in rainbow trout at 12 and 18°C were performed to evaluate temperature dependent development of *T. bryosalmonae* and associated pathology.

**Results:** In more than 40% of sites, *T. bryosalmonae* infected trout were found, the majority below an altitude of 800m. In experimental infections cumulative mortality at 12°C remained at 10%, but was over 90% at 18°C. *T. bryosalmonae* infection caused a severe granulomatous and necrotising nephritis with vasculitis with slower development of lesions and smaller parasite numbers at 12°C compared to 18°C. Fish surviving the infection fully recovered at both temperatures, but recovery was delayed at 12°C. Additionally, re-infections with associated renal pathology in 1+ trout did occur if animals were immunocompromised by stress or concurrent disease.

**Conclusions:** Development of pathological lesions and mortality due to PKD infection is temperature dependent. The average increase in water temperature recorded over the past decade could therefore lead to increased mortalities in wild and farmed trout in Europe.



**O28- NEW CONTRIBUTIONS TO THE STUDY OF  
ENTEROENDOCRINE SYSTEM IN TURBOT (*Psetta maxima*)  
FOLLOWING INFECTION WITH *Enteromyxum scophthalmi***

*Losada AP<sup>1</sup>, Bermúdez R<sup>1</sup>, Ronza P<sup>1</sup>, Quiroga MI<sup>1</sup>, Di Giancamillo A<sup>2</sup>, Domeneghini C<sup>2</sup>*

*1University of Santiago de Compostela, Spain. 2University of Milano, Italy.  
anapaula.losada@rai.usc.es*

**Introduction:** *Enteromyxum scophthalmi* is an intestinal myxosporean parasite responsible for serious outbreaks in turbot *Psetta maxima* (L.) culture. The disease affects the digestive tract, provokes severe necrotizing enteritis, emaciation and high rates of mortality. The aim of this study was to characterize the response of turbot enteroendocrine system against *E. scophthalmi* infection.

**Materials and Methods:** Immunohistochemistry was applied to sections of the gastrointestinal tract of uninfected and *E. scophthalmi*-infected turbot to describe the presence of bombesin (BOM), gastrin (GAS), glucagon (GLUC), leu-enkephalin (LEU), met-enkephalin (MET), pituitary adenylate cyclase-activating polypeptide (PACAP), pancreatic polypeptide (PPY) and somatostatin (SOM).

**Results:** The occurrence of *E. scophthalmi* in the turbot gastrointestinal tract significantly increased the number of endocrine cells immunoreactive to GAS, LEU and SOM. Moreover, BOM, GLUC and PPY immunoreactive cells were less numerous in the intestine of the parasitized turbot. Scarce immunoreactivity to BOM, GLUC, NPY, PACAP and SOM was observed in nerve fibres or neurones of the myenteric plexus of control and infected fish.

**Discussion and Conclusion:** The results indicate that *E. scophthalmi* infection in turbot induced changes in the enteroendocrine system, which may influence gut motility, electrolyte secretion, digestive processes and development of immune response.

This work was funded with the Projects AGL2009-13282-C02-02 and IT2009-0036 of the Spanish Ministry of Science and Innovation.

## **O29- RED MARK SYNDROME IN RAINBOW TROUT (*O. mykiss*) FARMED IN ITALY: ANATOMOHISTOPATHOLOGICAL INVESTIGATIONS.**

*Marco Galeotti<sup>1</sup>, Donatella Volpatti<sup>1</sup>, Beraldo Paola<sup>1</sup>, Barbara Brunetti<sup>2</sup>, Galletti Elena<sup>1</sup>, S.W. Feist<sup>3</sup>.*

*1Dipartimento di Scienze degli Alimenti, Università di Udine, 2Dipartimento di Scienze Mediche Veterinarie, Università di Bologna, 3CEFAS Weymouth Laboratory, UK. email: marco.galeotti@uniud.it*

**Introduction:** The Red Mark Syndrome (RMS) is a dermatitis affecting farmed rainbow trout (*O. mykiss*), firstly described in Scotland in 2003. Recently some sporadic outbreaks of RMS have been signaled also in Italy, where the disease affects adult fish reared at temperatures lower than 15°C. The etiology is still under investigation, although recently a rickettsia-like organism (RLO) has been associated with the skin lesions.

**Materials and Methods:** The purpose of this paper is to document some Italian episodes of disease involving, from May to December 2011, 5 farms located in northern Italy, with morbidity ranging between 10 and 15%. Samples of skin and internal organs of 10 trouts per farm were fixed in 4% buffered formalin/Bouin for histology and in 2% glutaraldehyde for TEM.

**Results:** Macroscopically the skin lesions were classified as follows: morphotype I, flat and scarcely extended lesions, non-hemorrhagic and without desquamation; morphotype II, larger lesions, slightly raised, with varying degrees of redness and centrally ulcerated; morphotype III, very wide lesions, hemorrhagic and markedly ulcerated. The inflammatory lesions, in brief, are characterized by the recruitment of a severe cellular infiltrate, consisting predominantly of lymphocytes, plasma cells and macrophages. The dynamic of the lesion development suggests an origin at the hypodermis level and a subsequent progression towards the dermis and epidermis, with the involvement of muscular tissue. In addition to the description of the lesions, some aspects of the etiology of the disease will be discussed.

**Discussion & Conclusion:** This is the first reported case of Red Mark Syndrome in Italy. The histological lesions can be defined: diffuse deep dermatitis with panniculitis and myositis. The spleen impressions smears show in the cytoplasm of macrophages structure morula-like ascribable to Rickettsia-like organisms.

Key-words: Red Mark Syndrome; rainbow trout; skin lesions; RLO; flogosis

### **O30- EXPRESSION OF TNF-ALPHA IN TELEOST FISH: AN IMMUNOHISTOCHEMICAL STUDY**

*Ronza P, Losada AP, Coscelli GA, Failde LD, Sancho AR, de Azevedo AM, Bermúdez R, Quiroga MI*

*University of Santiago de Compostela, Spain paolo.ronza@usc.es*

**Introduction:** Tumor necrosis factor-alpha (TNF- $\alpha$ ) is a powerful proinflammatory cytokine released by several immune cells during infection or tissue damage and is involved in a diverse range of inflammatory, infectious and malignant conditions. TNF- $\alpha$  is conserved in all vertebrate classes and has been identified, cloned and characterized in several bony fish species by molecular techniques. Nevertheless, there is very scarce information about its expression by immunohistochemistry.

**Materials and Methods:** We performed and optimized immunohistochemical assays with a commercial anti TNF- $\alpha$  polyclonal antibody in histological sections of different organs of freshwater and marine commercially-important teleost species.

**Results:** TNF- $\alpha$  immunoreaction was observed mainly in macrophage-like cells and/or melanomacrophages centres (MMCs), especially in the spleen, in all the studied species. In the digestive tract, eosinophilic granular cells (EGCs), rodlet cells and enteroendocrine cells were positive in some species. Moreover, reactivity was detected in nervous structures, as neuronal bodies in the thymus and myenteric plexus, as well as in endothelial structures.

**Discussion:** TNF- $\alpha$  immunohistochemistry was achieved in different commercially-important teleost species with results consistent with literature reports in higher vertebrates, staining mainly in cells involved in immune response. So, this marker can be a useful tool in ichthyopathology.

This work was funded by project AGL2009-13282-C02-02 of the Spanish Ministry of Science and Innovation. Ronza P is the recipient of a predoctoral grant from University of Santiago de Compostela.

**O31- EARLY LESIONS IN NON-HUMAN PRIMATES FOLLOWING AEROSOL EXPOSURE TO MYCOBACTERIUM TUBERCULOSIS.**

*E.L.Rayner, G.A.Hall, G.R.Pearson, M.Dennis, S.Sharpe*

*Health Protection Agency, Wiltshire, UK. emma.rayner@hpa.org.uk*

**Introduction:** The non-human primate provides an excellent model for human *M.tuberculosis* infection but little is known about development of early pulmonary lesions.

**Materials and Methods:** As part of a study to compare early events following aerosol challenge in rhesus macaques with the delivered doses, pathological examination and advanced imaging techniques, 10 animals were challenged with three doses (700, 70 and 7 CFU) of *M.tuberculosis*; tissues were examined histopathologically at two and three weeks post challenge.

**Results:** Granulomas at increasing stages of development were observed microscopically in the lungs, including intra-pulmonary lymphatics and hilar lymph nodes in animals in the high and mid dose groups at two and three weeks post challenge. In the low dose group, only small lesions were detected in the lung and hilar lymph nodes of one animal at three weeks post challenge; in the remaining two animals in this group, lesions were found in either lung or hilar lymph node. Lesion severity increased with increasing challenge dose and time post challenge. Acid fast bacilli were demonstrated in the lung and lymph nodes in all high and mid dose animals, and the lymph nodes of two low dose animals.

**Conclusion:** Study of early lesion development in this species is important in the understanding of early pathogenesis which may influence the design of future vaccine studies.

### **O32- HISTOPATHOLOGICAL DETECTION OF SUBCLINICAL LEPTOSPIROSIS IN FREE-RANGING IBERIAN LYNXES (LYNX PARDINUS)**

*M<sup>a</sup> Angeles Jimenez, Belen Sánchez, Laura Peña.*

*Dept. of Animal Medicine and Surgery, Veterinary Faculty of the Complutense University of Madrid. mariadji@vet.ucm.es*

**Introduction:** Leptospirosis is a zoonotic disease with worldwide distribution. Free-ranging carnivores are known reservoirs and there is concern about the exposure to infection of endangered species. The Iberian lynx is a critically endangered felid located in Southwestern Spain. In this study, renal lesions possibly associated with leptospirosis were characterized and the impact of the disease on this species was evaluated.

**Materials and Methods:** Formalin fixed tissue samples from 40 free-ranging and captive Iberian lynxes were examined. Consistent histologic lesions were processed for immunohistochemical (IHC) detection of *Leptospira* spp.

**Results:** Eight free-ranging lynxes had multifocal renal interstitial infiltrates at the cortico-medullary junction of plasma cells, lymphocytes and macrophages, changes consistent with leptospirosis. IHC positive spirochetes were detected in the lumens of proximal tubules in 6 animals. Only one animal evidenced widespread renal infection. The captive population was spared.

**Discussion:** Results indicated widespread exposure of free-ranging Iberian lynxes to this agent. Lesions were mild and chronic, consistent with subclinical disease. The presence of spirochetes in proximal tubules indicated potential bacterial excretion and the possibility of the Iberian lynx being a reservoir in addition to rarely exhibiting characteristics of an accidental host. Further studies on leptospiral pathogenicity in the Iberian lynx should be conducted in order to elucidate the impact of this disease and risk for conservation efforts.

**O33- RESPIRATORY DISEASES IN CHAMOIS (*Rupicapra rupicapra*)**

*Scaglione FE, Gelmetti D, Grande D, Chiappino L, Sereno A, Ferroglio E, Bollo E*

*University of Turin, Italy, [enrico.bollo@unito.it](mailto:enrico.bollo@unito.it)*

**Introduction:** Respiratory diseases in chamois may have viral, bacterial or parasitic etiology. An inter-specific infection, due to interaction between wild and domestic ruminants, is often recognized.

**Materials and Methods:** Seventy-five Chamois (*Rupicapra rupicapra*) from north-west Italy were referred for the necropsy to the Department of Animal Pathology of the University of Turin (Italy). Samples from lungs were collected for histological and immunohistochemical evaluations.

**Results:** Lesions were represented by edema (41 animals), haemorrhages (37), emphysema (35), hyperemia (34), atelectasis (17), thickening of alveolar septa (16), and thinning of alveolar septa (1). The inflammatory infiltrate was predominantly neutrophilic (29 cases); lymphocytes (22 cases), macrophages (20 cases), monocytes (5 cases), plasmacells (5 cases) and eosinophils (4 cases) were also detected. The bronchial epithelium showed loss of epithelium in 29 animals, proliferation in 25, and flattening in 6. The content of the airways was represented by inflammatory exudate (20 cases), mucous secretion (13), haemorrhages (5), and parasites (4). Other findings were represented by activated lymphoid follicles (48 cases), parasites (17 cases), and necrosis (2 cases). Immunohistochemical examinations of 50 samples resulted positive in 6 cases for *Mycoplasma bovis*.

**Conclusion:** All the samples showed lesions of variable degree. Some lesions were the probable cause of death of the examined animals. This study is in accordance with data from literature demonstrating that pulmonary diseases are leading cause of death in chamois.

### **O34- COMPARISON OF TEMPORAL AND SPATIAL DYNAMICS OF SEASONAL H3N2, PANDEMIC H1N1 AND HIGHLY PATHOGENIC AVIAN INFLUENZA H5N1 VIRUS INFECTIONS IN FERRETS**

*van den Brand J, Stittelaar K, van Amerongen G, Reperant L, de Waal L, Osterhaus A, Kuiken T*

*Department of Virology, Erasmus Medical Centre. j.vandenbrand@erasmusmc.nl*

**Introduction:** Humans may be infected by different influenza A viruses which differ in presentation from mild upper respiratory tract disease to severe and sometimes fatal pneumonia. Differences in spatial and temporal dynamics of these infections are poorly understood.

**Material and Methods:** Ferrets were inoculated with seasonal H3N2, pandemic H1N1 (pH1N1), and highly pathogenic avian H5N1 influenza virus, we performed detailed virological and pathological analyses from 0.5 to 14 days post inoculation (dpi), and we described clinical signs and hematological parameters.

**Results:** H3N2 infection was restricted to the nose and peaked at 1 dpi. pH1N1 infection also peaked at 1 dpi, with similar levels throughout the respiratory tract. H5N1 infection occurred predominantly in the alveoli, where it peaked from 1 to 3 dpi. Associated lesions followed the spatial distribution of the virus infection with their severity peaking between 1 and 6 days later. Neutrophil and monocyte counts in peripheral blood correlated with inflammatory cell influx in the alveoli.

**Discussion:** This study shows that seasonal, pandemic, and zoonotic influenza viruses differ strongly in the spatial and temporal dynamics of infection in the respiratory tract and extra-respiratory tissues of ferrets.

### **O35- NEW INSIGHTS ON THE IMPORTANCE OF RODENT POPULATION IN A ZOO ECOSYSTEM IN THE PATHOLOGY AND SPREAD OF CALODIUM HEPATICUM IN PRIMATES**

*Correia J<sup>1</sup>, Crespo A<sup>1</sup>, Noiva R<sup>1</sup>, Pissarra H<sup>1</sup>, Fernandes T<sup>2</sup>, Bernardino R<sup>2</sup>, Afonso F<sup>1</sup>, Lapão N<sup>2</sup>, Vaz Y<sup>1</sup>, Carvalho L<sup>1</sup>, Peleteiro C<sup>1</sup>.*

*1CIISA, Faculdade de Medicina Veterinária – Universidade Técnica de Lisboa, 2Jardim Zoológico de Lisboa. jcorreia@fmv.utl.pt*

**Introduction:** Calodium hepaticum infection is a wide spread zoonosis that affects primates including humans producing severe, sometimes lethal, hepatic lesions. The authors describe an infection in 4 non-human primates from Lisbon's Zoo and the infection prevalence on 100 rodents captured on-site.

**Material and Methods:** Necropsy exams were done in 1 Saguinus midas midas, 1 Saguinus bicolor and 2 Callimico goeldii. The hepatic lesions were assessed by histopathological evaluation. 50 Rattus norvegicus and 50 Mus musculus were captured and submitted to a parasitological necropsy, searching for parasites in liver and feces.

**Results:** The primate's necropsy identified hepatic lesions with parasites (adults and eggs), associated with necrosis and granulomatous inflammation. The infection prevalence on the analyzed rodents was 42 % in rat and 22 % in mouse.

**Discussion & Conclusion:** Calodium hepaticum can infect Saguinus midas midas and Callimico goeldii. Rodent-borne Calodium hepaticum infection in Saguinus can cause their death. Rodent-borne disease in captive animals is relevant. Fecal samples from primates and rat population, infected with Calodium hepaticum were negative for eggs in both flotation and sedimentation methods. This shows the limited application of these methods regarding the diagnosis of Calodium hepaticum infection.



### **O36- ASYMMETRICAL CAMPOMELIC DYSPLASIA-LIKE SYNDROME IN A COLONY OF COMMON MARMOSETS (CALLITHRIX JACCHUS)**

*Bosseler Leslie<sup>1</sup>, Cornillie Pieter<sup>1</sup>, Saunders Jimmy<sup>1</sup>, Bakker Jaco<sup>2</sup>, Langermans Jan<sup>2</sup>, Casteleyn Christophe<sup>3</sup>, Decostere Annemie<sup>1</sup>, Chiers Koen<sup>1</sup>*

*1Faculty of Veterinary Medicine, Ghent University, Belgium, 2Biomedical Primate Research Centre, Rijswijk, The Netherlands, 3Faculty of Pharmaceutical, Biochemical and Veterinary Sciences, University of Antwerp, Belgium. Koen.Chiers@UGent.be*

**Introduction:** In a closed colony of Common Marmosets, several animals presented bowing of the long bones. Affected animals showed no pain, discomfort or altered behavior, but could not entirely stretch their lower limbs.

**Materials and methods:** A group of 57 animals was clinically examined. Forty-one animals were euthanized for unrelated reasons. The bones of half of those euthanized animals were examined after maceration of the skeleton. The remaining living animals were monitored clinically and radiographically.

**Results:** One of the 16 living animals showed severe progressive diaphyseal bowing of the long bones from the age of 9 months onwards. Of the 41 euthanized animals, 7 showed similar abnormalities. Not all bones were affected equally, resulting in asymmetry of the condition. No other skeletal deformities or clinical illnesses were present. A hereditary pattern could not be found based on pedigree analysis.

**Discussion and conclusion:** The condition was diagnosed as an asymmetrical campomelic dysplasia-like syndrome. Only one similar case has previously been reported in a rhesus macaque (*Macaca mulatta*). The differential diagnosis of this unknown syndrome includes metabolic bone diseases and growth dysplasias. However, since no other clinical abnormalities were detected, a congenital skeletal dysplasia seems most likely.

### **O38- POSSIBLE ROLE OF PERIVASCULAR LESIONAL TYPES IN THE NEUROPATHOGENESIS OF VISNA/MAEDI ENCEPHALITIS LESIONS.**

*Polledo L, González J, Benavides J, Martínez-Fernández B, Pérez V, Ferreras MC, García Marín JF.*

*Campus de Vegazana S/N Facultad de Veterinaria. Universidad de León.*

**Introduction:** The aim of this work was the study of the CNS perivascular spaces in the neurological form of Visna/maedi disease (VM) in relation to the possible role in the virus neuroinvasion and in the development of the previously described types of lesion.

**Materials and Methods:** CNS sections from 22 sheep with VM encephalitis were examined. Immunohistochemistry was used for the detection of VM antigen and T-lymphocytes (CD3+, CD4+, CD8+), B-cells and macrophages.

**Results:** Sheep presented lymphocytic (n=9) or hystiocytic lesions (n=13). In lymphocytic lesions consisting on mono/bilayer perivascular cuffs with predominance of CD8+ T-cells, the viral antigen was located in perivascular spaces but rarely in the neuropil, but in more severe lesions with multilayer perivascular cuffs, sparse antigen was detected and perivascular sleeves were formed by CD4+/CD8+ T-cells in similar proportion. In hystiocytic lesions, vessels were mainly surrounded by macrophages, but also by T-cells and B-cells, with abundant viral antigen.

**Discussion:** The presence of VM antigen located in mono/bilayer perivascular cuffs might reflect initial stages of viral neuroinvasion, where viral replication may be controlled by an effective perivascular lymphocytic inflammatory response (limited presence of antigen). Then, this may also lead to severe lymphocytic or hystiocytic infiltration and might induce the recruitment and differentiation of more monocytes that would enable continuous viral replication. The present study reinforces and clarifies the prior model of development of nervous VM lesion.

**O39- SHATTERING THE MYTH OF RABBIT RESISTANCE TO PRION INFECTION.**

*F Chianini<sup>1</sup>, N Fernández-Borges<sup>2</sup>, E Vidal<sup>3</sup>, B Pintado<sup>4</sup>, S Hamilton<sup>1</sup>, SL Eaton<sup>1</sup>, J Finlayson<sup>1</sup>, Y Pang<sup>1</sup>, MP Dagleish<sup>1</sup>, J Castilla<sup>2</sup>*

*1 Moredun Research Institute, Scotland, UK. 2 CIC bioGUNE, Spain 3 CReSA, UAB-IRTA, Spain. 7 CNB, Spain Francesca.chianini@moredun.ac.uk*

**Introduction:** The ability of prions to infect some species and not others is mainly ruled by the transmission barrier. This unexplained phenomenon led to the belief that certain species were not susceptible to Transmissible spongiform encephalopathies (TSEs), and represented a minor risk to human health. Using the Protein Misfolding Cyclic Amplification (PMCA) technique, we were able to overcome the species barrier in rabbits, which have been classified as TSE resistant for four decades.

**Material and Methods:** Rabbit brain homogenate, either unseeded or seeded in vitro with disease related prions obtained from different species, was subjected to serial rounds of PMCA. De novo rabbit prions produced in vitro from unseeded material were tested for infectivity in rabbits.

**Results:** One of three intra-cerebrally challenged animals succumbed to disease at 766 days displaying all the characteristics of a TSE, thereby demonstrating that leporids are not resistant to prion infection. Material from the brain of this rabbit resulted in a 100% attack rate after its inoculation in transgenic mice over-expressing rabbit PrP. Furthermore, transmissibility to rabbits has been confirmed after intra-cerebral challenge (experiment ongoing).

**Discussion:** Despite rabbits no longer being able to be classified as resistant to TSEs an outbreak of 'mad rabbit disease' is unlikely.

**O40- GENE AND PROTEIN PATTERNS OF SIX SCRAPIE RELATED MARKERS IN THE CNS OF NATURALLY INFECTED SHEEP**

*Filali Hicham<sup>1</sup>, Vidal Enric<sup>2</sup>, Bolea Rosa<sup>1</sup>, Márquez Mercedes<sup>2</sup>, Marco Paula<sup>2</sup>, Vargas Antonia<sup>1</sup>, Pumarola Martí<sup>2</sup>, Martín-Burrie Inmaculada<sup>3</sup>, Badiola Juan J<sup>1</sup>*

*1Centro de Investigación en Encefalopatías y Enfermedades Transmisibles Emergentes. Facultad de Veterinaria, Universidad de Zaragoza. Zaragoza, Spain.. 2PRIOCAT Laboratory, UAB-IRTA, Campus de la Universitat Autònoma de Barcelona, Barcelona, Spain. 3Laboratorio de Genética Bioquímica (LAGENBIO), Facultad de Veterinaria, Universidad de Zaragoza, Zaragoza, Spain. hicham@unizar.es*

**Introduction:** The pathogenesis of prion diseases is still poorly understood, and the molecular mechanisms of these diseases are far to be clear.

**Materials and Methods:** We presented here the gene expression profiles and protein distribution of six differentially regulated genes (CAPN6, COL1A2, COL3A1, GALA1, MTNR1B and MT2) during early and terminal stages of the scrapie disease in five different brain areas, using Real Time PCR and Immunohistochemistry.

**Results:** Profiles of the gene expression were generally similar in the central nervous system areas and the changes were more important in clinical than in preclinical sheep. The expression of CAPN6 protein was increased in different areas of clinical and preclinical brains, mainly in the spinal cord, the distribution of the neuropeptide GALA1 was noticed in the glial cells from cerebellar cortex of scrapie animals and the increase of MT2 was in agreement with previously reported works. Finally, the down-regulation of MTNR1B was specially marked in the Purkinje cells.

**Conclusion:** This gene and protein distribution study reveals CAPN6, GALA1, MTNR1B and MT2 as good potential targets for pathogenesis of prion diseases.

## **O41- A PORCINE MODEL OF HAEMATOGENOUS BRAIN INFECTION WITH STAPHYLOCOCCUS AUREUS**

*Astrup Lærke<sup>1</sup>, Agerholm Jørgen<sup>1</sup>, Nielsen Ole<sup>1</sup>, Jensen Henrik<sup>1</sup>, Leifsson Páll<sup>1</sup>, Iburg Tine<sup>2</sup>.*

*1Faculty of Health and Medical Sciences, University of Copenhagen, Denmark  
boye@life.ku.dk 2National Veterinary Institute, Uppsala, Sweden*

**Introduction:** Staphylococcus aureus (S.aureus) is a common cause of sepsis and brain abscesses in man and a frequent cause of porcine pyaemia. Here we present a porcine model of haematogenous S. aureus-induced brain infection.

**Materials and Methods:** Four pigs had two intravenous catheters inserted surgically, one in a. carotis communis and one in v. jugularis externa. All pigs received 106 CFU/kg body weight S. aureus through the arterial catheter. Bacteria were either suspended in isotonic saline infused at constant flow for 60 minutes (two pigs) or given as a bolus injection of autologous thromboemboli (two pigs). The venous catheter was used for blood sampling before, during and after inoculation. The pigs were euthanized either 24 or 48 hours after inoculation. The brains were collected and examined histologically.

**Results:** We describe unifocal suppurative encephalitis 48 hours after inoculation with autologous S. aureus thromboemboli. The other pigs developed mild diffuse cerebral oedema. The blood analyses showed a short period of bacteraemia.

**Conclusion:** Our pilot study proves it possible to establish embolic infection in the porcine brain through the normal circulatory pathway, when autologous thromboemboli are used. This was hitherto thought impossible due to the presence of rete mirabilis in this species.

## **O42- TOXICOPATHOLOGICAL CHARACTERIZATION OF GOAT AS ANIMAL MODEL OF BOVINE CEREBELLAR CORTICAL DEGENERATION INDUCED BY *Solanum bonariense***

*Verdes JM<sup>1</sup>, Dehl V<sup>1</sup>, Borteiro C<sup>1</sup>, Dura L<sup>1</sup>, Gimeno EJ<sup>2</sup>, Guidi MG<sup>2</sup>, Guerrero F<sup>3</sup>, Fidalgo LE<sup>3</sup>, Moraña A<sup>1</sup>.*

*1 University of the Republic (UdelaR), Montevideo, Uruguay, 2National University of La Plata, Argentina, 3 University of Santiago de Compostela, Lugo, Spain, jmverdes@fvet.edu.uy*

**Introduction:** *Solanum bonariense* (S.b.) ingestion causes cerebellar degeneration in cattle. Here, we report the toxicopathological characterization of experimental S.b. poisoning in goats.

**Material and Methods:** Three goats were used; two received dry leaves equivalent to 0.75% of Body Weight/day, until the onset of cerebellar signs, and other as a control. At necropsy, samples were taken from cerebellum, other regions of CNS, liver, kidney, heart, lung, and spleen, fixed in 10% formalin, or in 2.5% glutaraldehyde. Paraffin-embedded sections were stained with HE, and Lectin histochemistry (LHQ) using 9 lectins was carried out. Epon-embedded sections were examined in a Transmission Electron Microscope.

**Results:** The toxic dose was 0.495 kg dry leaves/kg BW. At necropsy, there were no significant gross lesions in poisoned goats. In cerebellum, perikaryal vacuolation and Purkinje cells loss were confirmed. Purkinje cells stained strongly with WGA, sWGA, ConA, and reacted weak to clear to UEA-I, RCA-I, DBA, SBA, PNA, BS-I.

**Conclusions:** We confirmed the toxicity of S.b. for goats, characterizing their pathological changes, resulting similar to cerebellar degeneration of cattle. LHQ pattern was similar to those detected in others plant induced  $\alpha$ -mannosidosis, but in our case there is vacuolization only in Purkinje cells.

### **O43- SPONGY DEGENERATION OF THE CEREBELLAR NUCLEI WITH ATAXIA IN MALINOIS PUPPIES**

*Högler Sandra<sup>1</sup>, Kleiter Miriam<sup>2</sup>, Leschnik Michael<sup>2</sup>, Kneissl Sibylle<sup>2</sup>, Url Angelika<sup>1</sup>*

*1Department of Pathobiology, 2Department for Companion Animals and Horses, University of Veterinary Medicine Vienna, Austria, sandra.hoegler@vetmeduni.ac.at*

**Introduction:** Purebred dogs show a high incidence of hereditary degenerative diseases of the central nervous system. The records of Malinois puppies with spongy degeneration of the cerebellar nuclei were analysed in a retrospective study.

**Materials and Methods:** Thirteen puppies of both sexes from 5 different litters (1995-2009) of phenotypically normal parents were reinvestigated regarding clinical signs, neuroimaging, histopathological changes and pedigree data.

**Results:** All animals showed signs of cerebellar dysfunction starting at the age of four to seven weeks and resulting in euthanasia by the age of 13 weeks. Computed tomography and magnetic resonance imaging did not reveal any abnormalities of the brain. At gross examination brain and spinal cord were normal too. Histologically, marked to severe bilateral symmetrical vacuolization of the neuropil of the cerebellar nuclei was evident in all animals. To a lesser extent vacuoles were also found in the cerebellar granule cell layer and white matter of the cerebellar folia. In some animals scattered vacuoles in white and gray matter were seen throughout medulla, pons and midbrain. Pedigree analysis could trace back all litters to one sire.

**Conclusion:** The histopathological lesions present in Malinois puppies can be distinguished clearly from classic cerebellar cortical abiotrophies. Analysis of pedigree data and segregation frequency support the hypothesis of an autosomal recessive hereditary disorder.

#### **O44- CHARACTERIZATION OF THE IMMUNE CELL INFILTRATE IN THE INTESTINE OF HORSES WITH INFLAMMATORY BOWEL DISEASE**

*Olofsson Karin<sup>1</sup>, Press Charles McL<sup>2</sup>, Lindberg Ronny<sup>1</sup>*

*1Swedish University of Agricultural Sciences, Uppsala, Sweden and 2Norwegian School of Veterinary Sciences, Oslo, Norway*

**Introduction:** Equine eosinophilic gastroenteritis (EEG) and equine granulomatous enteritis (EGE) are two distinct patho-anatomical variants of chronic idiopathic inflammatory bowel disease in horses. The inflammatory cell infiltrates of the intestine are insufficiently characterized in both entities. The present study was performed on the jejunal mucosa and compares phenotypical features of immune cell infiltrates in EEG and EGE with those of the immune cell population of healthy horses.

**Materials and Methods:** Jejunal tissue specimens of 10 horses with a diagnosis of EEG or EGE at necropsy, and of 5 healthy slaughtered horses, were used after histological assessment. Tissue slides were immunolabelled for CD3, CD79 $\alpha$ , FoxP3 and MHCII, applying indirect immunohistochemical techniques. For quantification of immunolabelling, a blinded study was performed. The compartmentalization and relative area of immunolabelling were determined using the computer software NIS-Elements Br (Nikon).

**Results:** Tissue specimens of healthy horses were free of intestinal inflammation and those from cases of EEG or EGE had lesions typical for the specific diagnosis. The quantification of immunolabelling is in progress and results will be presented on the poster.

**Discussion:** This study tests whether there is a difference between immunophenotype of intestinal immune cell populations in EEG and EGE. Results from the study will be discussed on the poster.



## **O45- EFFECT OF COATED CALCIUM BUTYRATE ON SOY PROTEIN CONCENTRATE ASSOCIATED INTESTINAL DAMAGE IN CALVES.**

*Wegge Beatrice, Saey Veronique, Ducatelle Richard and Chiers Koen*

*Faculty of Veterinary Medicine, Ghent University, Belgium. Beatrice.wegge@ugent.be*

**Introduction:** We previously showed that even low concentrations of soy protein concentrate replacing milk protein induces changes in intestinal mucosal morphology. The aim of our study was to examine the morphological intestinal changes in calves given a low antigenic soy protein concentrate together with coated calcium butyrate.

**Materials and methods:** Holstein calves were given different diets during 12 days. GroupC received cow milk. GroupS received standard milk replacer and groupM modified milk replacer containing 8% soy protein concentrate (SPC). Additionally, three groups were fed with 8% SPC supplemented with an increasing concentration of coated calcium butyrate (CCB) (e.i. group M1, M2 and M3). Small and large intestinal samples were collected for measurement of villus length and width, crypt depth and muscularis thickness.

**Results:** GroupM had significantly decreased villus length and increased width compared to C and S. CCB increased the villus length compared to group M. The increase was correlated to the amount of CCB in the diet. Crypts were significantly deeper in M compared with S and C. CCB decreased the crypt depth in a dose dependent way. The tunica muscularis was significantly thicker in groupM compared to groupC and S.

**Conclusion:** CCB restored intestinal morphology almost to the level of the calves fed with cow's milk.

**O46- INTESTINAL ADENOCARCINOMA IN A HERD OF FARMED SIKA DEER (CERVUS NIPPON). A NOVEL SYNDROME.**

*Kelly Pamela<sup>1</sup>, Toolan Donal<sup>2</sup>, Jahns Hanne<sup>1</sup>*

*1 School of Veterinary Medicine, Dublin, Ireland, 2 Regional Veterinary Laboratories, Kilkenny, Ireland Hanne.Jahns@ucd.ie*

**Introduction:** Intestinal adenocarcinoma is common in sheep in New Zealand and in cattle on bracken infested pastures with contemporaneous bovine papillomavirus infection. It occurs sporadically in other animal species. This report concerns multiple cases of a novel intestinal adenocarcinoma in a herd of farmed Sika deer.

**Material and Methods:** Sika deer hinds (150) and their off-spring were grazed on bracken infested terrain. The herd was inbred; the last animal was introduced 15 years ago. Seventy nine cases of intestinal adenocarcinoma were identified over an 8-year-period, 29 on post mortem examination of adult deer with intermittent diarrhoea and weight loss and a further 50 on examination of intestines of culled deer at slaughter.

**Results:** Lesions were typically multifocal in affected deer and were present in the caecum and proximal colon. These were characterised macroscopically by localised, pale, firm, poorly circumscribed thickenings of the intestinal wall and ranged from mild plaque-like mucosal lesions to marked circumferential thickenings causing strictures. Histologically, tubular, mucinous and mixed types of adenocarcinoma were often co-localised with hypertrophy of tunica muscularis and myenteric plexi, scirrhous reactions, granulomatous lymphadenitis and occasional vasculitis.

**Discussion and conclusion:** This is the first description of intestinal adenocarcinoma in deer. Future investigations will be aimed at possible aetiological factors involved in the condition.

**O47- INTESTINAL LEIOMYOSITIS AND CHRONIC INTESTINAL PSEUDO-OBSTRUCTION IN A BICHON MALTESE DOG.**

*Galindo-Cardiel J<sup>1,2</sup>, Soto S<sup>1,3</sup>, Lloret A<sup>1</sup>, Marco A<sup>1</sup>*

*1 Universitat Autònoma de Barcelona (UAB), Bellaterra, Spain. 2. Worldpathol S.L., Zaragoza, Spain. 3 IMBA (Institute of Molecular Biotechnology), Dr. Bohr-Gasse , 1030, Viena, Austria*

**Introduction:** A non-neutered 12 years-old male Bichon Maltese affected by a non-responsive, persistent paralytic ileus was submitted to UAB Veterinary Teaching Hospital. No evidence of intestinal obstruction or Key-Gaskell syndrome was observed.

**Material and Methods:** Severely affected ileocecal valve was removed by enterotomy. Ileal and yeyunal tru-cut biopsies were also obtained. Intestinal samples were submitted to the Pathology Unit for diagnosis. A complete histopathological evaluation by HE was performed. In order to characterize the lesion, Masson Trichrome, PAS, and Gram stains were done. Immunohistochemistries for detection of CD3, CD79, MAC 387, Lys, SMA, NSE and canine IgG and IgA are currently in process.

**Results:** An intense diffuse inflammatory infiltration, composed of high amounts of lymphocytes, plasmacytes and few macrophages and neutrophils, was observed in the serosa and longitudinal and circular muscular layers of all samples. Multifocal myocytolysis and inter-myocyte edema were also observed. Myenteric ganglia presented neuronal tumefaction with intracytoplasmic vacuoles and mild lymphocytic plasmacytic perineuronal infiltrates. Severe edema and lymphangiectasia were also observed in the mucosa and submucosa, with scattered ulcerations with associated microhaemorrhages affecting the mucosal layer. Low number of multinucleated giant cells and foamy macrophages were detected in the serosa.

**Discussion & conclusions:** Intestinal leiomyositis as cause of chronic intestinal pseudo-obstruction was diagnosed in the basis of the clinical outcome and the microscopic evaluation. The etiopathogenesis of this rare condition in dogs is unknown. The results of this work can contribute to the understanding of this process. Differential diagnosis will be discussed in the basis of pathological characterization.

**O48- SLIMMING SYNDROME IN SHEEP. FROM VACCINE ADVERSE REACTION TO SEVERE ANAEMIA AND SKINNY ANIMALS**

*Acín C., Bolea R., Marín B., Fernández de Luco D., García L., Garza M., Sarasa R., Pitarch J.L., Hedman C., Vargas A., Badiola J.J.*

*Department of Animal Pathology. Veterinary Faculty. University of Zaragoza.*

**Introduction:** During the last 3 years it has been observed a slimming syndrome affecting adult sheep. It started with the description of a neurological syndrome, probably associated to the massive vaccination of bluetongue during 2008-2009. After that, punctual but consistent outbreaks of “sudden death”, slimming, miscarriage, wool loss, were detected through different flocks in the Aragón region. The objective of the present study has been the analysis of the different casuistry detected in order to clarify the relevance of current procedures that are carried out in sheep animal health.

**Materials and Methods:** A total of 63 adult sheep from 12 flocks has been investigated. Epidemiological, haematological and histopathological studies have been developed.

**Results:** All the animals showed problems related with caquexia or neurological signs. 24 out of 39 showed anaemia (poikilocytosis and Heinz bodies; haemolytic; thrombocytopenia, babesia). Proteinuria was also a common finding. Histopathological study revealed muscular and fat atrophy; verminous pneumonia; interstitial nephritis and glomerulonephritis; eosinophilic and lymphoplasmacytic enteritis and multifocal hepatitis.

**Discussion:** Some of the haematological disturbances here presented have been associated in the literature with hepatic oxidative processes or chronic glomerular disturbances. Lesions guide us to a multifactorial syndrome where handling, feeding and animal health seems to be the three determinant factors.

## **O49- ULTRASTRUCTURAL MITOCHONDRIAL ALTERATIONS IN EQUINE MYOPATHIES OF UNKNOWN ORIGIN**

*Van Driessche Karolien, Ducatelle Richard, Chiers Koen, Van Coster Rudy, van der Kolk Han*

*Department of Veterinary Pathology, Ghent University, Belgium, karolien.vandriessche@ugent.be*

**Introduction:** The purpose of this present study was to examine mitochondrial ultrastructure in equine cases of myopathy. Here, we report the aberrant mitochondrial structure in several patients of various breed and age, diagnosed with myopathy of unknown origin.

**Material and Methods:** From patients diagnosed with myopathy of unknown etiology and clinically healthy horses muscle biopsy was performed. A Bergström needle was introduced in the vastus lateralis of the musculus quadriceps femoris. The muscle samples were taken in vivo or within fifteen minutes after necropsy. The samples were fixed in paraformaldehyde (1%) and glutaraldehyde (2, 5%) in cacodylate buffer and embedded in epoxy resin medium for transmission electron microscopy. From all horses vastus lateralis samples were also snap frozen and kept at -80°C.

**Results:** Ultrastructural examination revealed various mitochondrial changes. In five patients the mitochondria had a remarkably different morphology in comparison to the control group, varying from long and slender mitochondria with an onion shaped appearance on transverse section to extremely large mitochondria with excessively branched cristae.

**Discussion & Conclusion:** Very little is known about the aberrant mitochondrial ultrastructure in veterinary medicine, especially in horses. This study provided us with several case reports of mitochondrial ultrastructural changes in horses diagnosed with myopathy of unknown origin. Further biochemical studies will be performed on muscle biopsies from these patients.

**O50- FOCUS ON HEART AND KIDNEY PATHOLOGY IN DIFFERENT COMBINATIONS OF FcγR-DEFICIENT MICE**

Salvatori Daniela<sup>1</sup>, Bergmann Wilhelmina<sup>2</sup>, Grinwis Guy<sup>2</sup>, Verbeek J. Sjeff<sup>1</sup>

<sup>1</sup> Leiden University Medical Center, <sup>2</sup> Veterinary Faculty, Utrecht. The Netherlands.  
W.Bergamnn@uu.nl

**Introduction:** The receptor family for the Fc part of Immunoglobulin G (FcγR) consist of three activating receptors, FcγRI, FcγRIII and FcγRIV, counterbalanced by one inhibiting receptor, FcγRIIb. Mice deficient for FcγRIIb on mixed 129 / C57BL/6 background are susceptible for the development of lupus like disease. Lupus arises as a consequence of the loss of immunological tolerance resulting in the production of Antinuclear (auto) antibodies (ANA) which trigger chronic inflammation.

**Materials and methods:** To understand the contribution of the different activating FcγR to the development of lupus we analysed the phenotype of FcγRII<sup>-/-</sup>, FcγRII<sup>-/-</sup>RIII<sup>-/-</sup>, RII<sup>-/-</sup> FcγRIII<sup>-/-</sup> RI<sup>-/-</sup> and FcγR<sup>-/-</sup> mouse lines.

**Results:** All mice deficient for FcγRIIb developed with high incidence high ANA titres with age. However, FcγRII<sup>-/-</sup> and FcγRIII<sup>-/-</sup>RII<sup>-/-</sup> RI<sup>-/-</sup> mice developed proliferative lupus nephritis, systemic vasculitis, myocarditis, severe valvulopathies and severe lymphoid hyperplasia in secondary lymphoid organs whereas the FcγRII<sup>-/-</sup> RIII<sup>-/-</sup> line developed milder lesions without increased mortality.

**Conclusion:** The hyperactive phenotype of FcγRIIB KO mice confirms its important role in the negative regulation of activating Fc receptors on effector cells. The severe phenotype of the triple KO suggests that the role of the activating FcγR is redundant and that the presence of a single activating FcγR, FcγRIV, is sufficient to drive immune complex mediated chronic inflammation resulting in increased mortality.

## **O51- ASSESSMENT OF COLONY FORMING CAPACITY OF THE CANINE HAIR FOLLICLE UNDER TWO DIFFERENT CULTURE CONDITIONS**

*Wiener DJ, Suter M, Welle MM*

*Institute for Animal Pathology, Vetsuisse-Faculty, University of Bern, Switzerland, dominique.wiener@vetsuisse.unibe.ch*

**Introduction:** Hair growth is dependent on the coordination of the hair cycle phases and a functional stem cell (SC) compartment. We assess the growth and differentiation potential of colonies derived from different anatomic locations of the hair follicle (HF) to define the location of follicular SCs in dogs.

**Materials and Methods:** Colony forming capacity of the different HF locations (upper isthmus, lower isthmus, inferior portion) is assessed by microdissection of HFs. The proliferating or differentiating capacity of the colonies is assessed by immunofluorescence for Ki67, a marker for cell proliferation and for involucrin, a marker for differentiation. The experiments are conducted in two different media (cFAD, CELLnTEC 09) selected for their ability to promote SCs.

**Results:** Colonies derived from the inferior portion exceed the colonies derived from isthmus parts in number and size. However, the colonies derived from the inferior portion are mainly involucrin positive representing transient amplifying cells whereas the colonies growing from isthmus cells consist mainly of proliferating SCs. The CELLnTEC medium is superior to the cFAD medium in regard to the promotion of SC colonies.

**Discussion & Conclusion:** The colonies derived from the isthmus part consist mainly of proliferating SCs, whereas transient amplifying cells are derived from the inferior portion. To enhance growth of proliferating SCs, the medium from CELLnTEC is better adapted than cFAD medium.





# POSTER



## **P1- INSULIN-LIKE GROWTH FACTOR-1 RECEPTOR (IGF-1R) EXPRESSION CORRELATES WITH PROGNOSIS IN DOGS WITH MAMMARY CARCINOMA**

*Nguyen Frédérique, Godard Tiffanie, Jaillardon Laëtitia, Morio Floriane, Ibisch Catherine, Abadie Jérôme, Siliart Brigitte*

*Oniris, Nantes, France, frederique.nguyen@oniris-nantes.fr*

**Introduction:** In canine mammary carcinomas (CMCs), expression of Insulin-like Growth Factor-1 Receptor (IGF-1R) has been associated with the histological subtype, grade, estrogen and progesterone receptor expression levels. In the era of selective tyrosine kinase inhibitors, we wanted to precise to what extent CMCs would benefit from an IGF-1R inhibition-based therapy.

**Materials and Methods:** Retrospective study of 100 canine mammary carcinomas (53 carcinomas in situ and 47 invasive carcinomas) treated surgically, with a 2-year follow-up. IGF-1R expression was determined by immunohistochemistry (clone G11, Roche Diagnostics) and scored following the same guidelines as HER2 in breast cancer.

**Results:** IGF-1R overexpression (immunohistochemical score 3+) was more common in carcinomas in situ (14/53 cases, 26%) than in invasive carcinomas (1/47, 2%). Strong IGF-1R expression (score 2+) was common in both carcinomas in situ (24/53, 45%) and invasive carcinomas (24/47, 51%). IGF-1R expression level had no prognostic value for carcinomas in situ, regarding disease-free and specific survival. In invasive carcinomas, strong IGF-1R expression (scores 2+ and 3+) was associated with higher metastatic risk ( $p=0.01$ ), shorter disease-free survival ( $p=0.04$ ), and shorter overall survival ( $p=0.0011$ ) than IGF-1R scores 0 and 1+ (log-rank test).

**Conclusion:** The most aggressive invasive mammary carcinomas in bitches, i.e., those associated with recurrence, metastasis, and shorter survival, show strong IGF-1R expression and are candidates for selective IGF-1R inhibition.

## **P2- DETECTION OF PROGESTERONE RECEPTOR BY qPCR ANALYSIS FROM FORMALIN-FIXED PARAFFIN EMBEDDED CANINE MAMMARY TISSUES.**

*Guil-Luna S<sup>1</sup>, Stenvang J<sup>2</sup>, Brünner N<sup>2</sup>, Sánchez-Céspedes R<sup>1</sup>, Millán Y<sup>1</sup>, Gómez-Laguna J<sup>1</sup>, Martín de las Mulas J<sup>1</sup>.*

*1University of Córdoba, Córdoba, Spain, v22gulus@uco.es*

**Introduction:** Genome amplification from formalin fixed paraffin embedded (FFPE) material by real time polymerase chain reaction (qPCR) is a valuable tool to identify biomarkers in several human cancers. Moreover, reverse transcriptase (RT-qPCR) allows amplifying mRNA targets in tissue samples. The aim of this work was to standardize a method for the detection of progesterone receptor, a prognostic biomarker in breast cancer, from canine mammary FFPE tumors.

**Materials and Methods:** Extraction of RNA was performed using a column-based RNeasy kit (Qiagen) and the purity was determined spectrophotometrically from the ratio of absorption at 260/280nm. For RT-qPCR reactions an one-step SYBR Green based protocol was applied. The primers were designed specifically to target the coding regions of the canine progesterone gene and canine HPTR1 and RPL32 were employed as housekeeping control genes.

**Results:** The RNA extraction procedure showed an efficient extraction and adequate purity of RNA. Furthermore, the RT-qPCR demonstrated that mRNA of canine progesterone receptor was successfully amplified from FFPE canine mammary tumors.

**Discussion & Conclusion:** The results of this study show the potential of RT-qPCR for genome amplification from canine FFPE tissues, becoming a reliable tool for biomarkers research in canine mammary tumors. The use of housekeeping genes is essential in order to guarantee the homogeneity of the results. Acknowledgements: AGL2011-25553

### **P3- ALTERED P120 CTN EXPRESSION IN CANINE MAMMARY CARCINOMAS IS ASSOCIATED WITH POOR SURVIVAL**

*Pereira D<sup>1</sup>, Alves A<sup>1</sup>, Paredes J<sup>2,3</sup>, Schmitt F<sup>2,3</sup>, Gama A<sup>1</sup>*

*1 University of Trás-os-Montes and Alto Douro, CECAV, Vila Real, 2 IPATIMUP, Porto; 3 Faculty of Medicine of the University of Porto, Porto, Portugal.  
agama@utad.pt*

**Introduction:** Cell-to-cell adhesion mediated by cadherins plays an important role in tumour invasion and progression. In canine mammary carcinomas (CMC), E-cadherin and its catenin partner's expression are frequently downregulated. In the present study, we aimed to investigate if p120 catenin (ctn) expression is associated with known clinicopathological parameters, as well as its relation with E-cadherin and  $\beta$ -catenin expression and survival.

**Materials and methods:** p120 ctn, E-cadherin and  $\beta$ -catenin expression was evaluated in 108 CMC by immunohistochemistry. Immunoreactivity was scored according to the subcellular localisation in normal or reduced membrane, cytoplasmic and negative expression. Statistical analysis was performed using SPSS 11.5.

**Results** Most neoplastic tissues showed a reduced membrane (48.5%) or a cytoplasmic staining pattern (24.2%) of p120 expression. A cytoplasmic or negative expression pattern was significantly associated with an infiltrative growth, vascular invasion, high histological grade and reduced/loss of E-cadherin/ $\beta$ -catenin membrane expression. In addition, p120 cytoplasmic or negative expression was also associated with low survival rates.

**Discussion and conclusions:** With the present study, we observed that loss of p120 ctn or its accumulation in cytoplasm is associated with aggressive tumour features, as well as with poor prognosis, which suggest p120 ctn as a potential prognostic factor in canine mammary cancer.

#### **P4- IMMUNOHISTOCHEMICAL STUDY OF TRANSFORMING GROWTH FACTOR BETA-1 (TGF BETA-1) EXPRESSION IN CANINE MAMMARY GLAND TUMORS.**

*Movassaghi Ahmad Reza, Rezaee-Oghazi Massoud, Maleki Mohsen.*

*Faculty of Veterinary Medicine, Ferdowsi University of Mashhad, Mashhad, Iran.  
massoud.rezaee@yahoo.com*

**Introduction:** Mammary tumors are an important health problem in female dogs which constitute the most common neoplasm in this population. Transforming Growth Factor Beta (TGF Beta) family are believed to have both tumor suppressing and enhancing activities. In this study we purpose to investigate the expression of TGF Beta-1 in canine mammary tumors using Immunohistochemistry.

**Materials and Methods:** 21 samples of canine mammary gland tumors included in this study, which had been confirmed histopathologically. Mouse ovary and canine normal mammary gland tissues used as positive and negative controls, respectively. Immunohistochemistry was done on formalin-fixed, paraffin-embdded samples with Avidin-Biotin Complex method (ABC) in which Horse Radish Peroxidase (HRP) and DAB used for developing positive signals. Images analysed using the software “Image J” v1.43 (U.S. National Institutes of Health, Bethesda, MD, U.S.A.)

**Results:** Immunohistochemistry results revealed that 4 (19.04%) of tumor samples showed weak immunoreactivity, 10 (47.61%) with moderate and 7 (33.33%) with strong immunoreactivity for TGF beta-1.

**Conclusion:** These results show that canine mammary gland tumors express TGF beta-1 in different extent and it could be used as a therapeutic target in future.

## **P5- IMMUNOHISTOCHEMICAL EXPRESSION OF RANK (RECEPTOR ACTIVATOR OF NUCLEAR FACTOR KAPPA B) IN CANINE MAMMARY CARCINOMAS.**

*Guil-Luna S, Sánchez-Céspedes R, Millán Y, Martín de las Mulas J.*

*University of Córdoba, Córdoba, Spain, v22gulus@uco.es*

**Introduction:** Receptor activator of nuclear factor kappa B (RANK) and its ligand represent the key regulators of bone metabolism. As well as on bone cells, RANK expression has been detected in other tissues including human breast cancer. Recent studies highlight a potential role for RANK on the proliferation of human breast cancer. To our knowledge, there are no previous studies investigating RANK expression in primary canine mammary tumours.

**Materials and Methods:** Twenty two cases of primary canine mammary carcinomas were evaluated by immunohistochemistry for RANK expression (14 complex, 5 carcinomas in benign tumour and 3 simple carcinomas).

**Results:** Two expression patterns of RANK were found: a diffuse and moderate pattern mostly exhibited by neoplastic epithelial cells and some myoepithelial cells foci, and a strong staining in scattered neoplastic epithelial cells. When the histological type of tumours was analyzed, the highest RANK expression was seen in simple carcinomas (100%) followed by complex (57%) and carcinomas in benign tumours (40%). The same was observed when the histological grade was taken into account: grade III (100% positive): grade II (83%) and grade I (50%).

**Discussion & Conclusion:** Although further studies are necessary, our results suggest that RANK expression might play a role in the pathogenesis of canine mammary tumours and may be related to histological type and grade.

Acknowledgements: AGL2011-25553.

## **P6- HISTOPATHOLOGICAL AND IMMUNOHISTOCHEMICAL STUDY OF CANINE MAMMARY SARCOMAS**

*Dolka I<sup>1</sup>, Sapieryński R<sup>1</sup>, Król M<sup>2</sup>*

*1Department of Pathology and Veterinary Diagnostic, 2Department of Physiological Sciences, Warsaw University of Life Sciences, Poland, izabella\_dolka@sggw.pl*

**Introduction:** Canine mammary sarcomas (CMS) appear to be very rare but these types are more frequent recognized than in women. The knowledge about CMS is still limited. The aim of this study is estimate prevalence of CMS, their histopathological and immunohistochemical characteristics.

**Materials and Methods:** Data from 15 years were analyzed. Tissue samples were evaluated by H-E. 16 cases were evaluated by immunohistochemistry (IHC) for Vim, CK,  $\alpha$ -SMA, Des, p63, Ki67, p53, ER $\alpha$ , PR. They were graded as low and high according degree of differentiation, presence of necrosis.

**Results:** The CMS were recognized in 4.2% (32) of all canine mammary tumors – CMT. It was 5.2% of all malignant CMT. The ratio of sarcomas to carcinomas CMT was 1:18. Osteosarcomas, fibrosarcomas, liposarcomas were most common types recognized. Mean age of bitches was 11 years. All 16 CMS were positive for Vim, 37.5% cases for  $\alpha$ -SMA, 6.3% for Des. CK, p63, ER $\alpha$  expression was not observed. Only Vim correlated with sarcomas type. Ki67 and p53 expression were frequently detected in high grade CMS, however only Ki67 showed a positive correlation with grade. 56% and 25% cases were immunoreactive for p53 and PR, respectively.

**Conclusion:** Prospective determination Ki67 may be useful in CMS grading. Our results expand knowledge about CMS. IHC certainly facilitates the diagnosis of these rare CMT.



**P7- HEPCIDIN EXPRESSION IN CANINE AND FELINE MAMMARY TUMORS**

*Marques O, Canadas A, Rêma A, Faria F, Simão J, Gärtner F, Martins da Silva B, Porto G and Lopes C*

*Institute of Biomedical Sciences Abel Salazar (ICBAS), University of Porto, Portugal, oamarques@icbas.up.pt*

**Introduction:** Iron is an essential element involved in oxygen transport and in the activity of vital enzymes. Since it is critical for cell proliferation and given that neoplastic cells have higher requirements for iron, several authors presented evidences linking iron with mammalian carcinogenesis. The expression of hepcidin, a key regulator of iron metabolism, was assessed in canine and feline mammary tumors.

**Materials and Methods:** Hepcidin expression was evaluated by immunohistochemistry in 21 canine and 20 feline tissue microarray tumor samples. Normal human liver was used as a positive control. Perls' Prussian blue staining was done to assess hemosiderin deposits.

**Results:** Most tumor samples showed cytoplasmic staining for hepcidin (62,5% in the dog and 90% in the cat). Additionally, luminal and nuclear immunoreactivity was also found in 62,5% and 25,0% of canine, and in 80,0% and 55,0% of feline samples, respectively. Perls' positivity was observed in 80,95% of canine and in 45,45% of feline samples, mostly in inflammatory stromal cells. Tumor cells with hemosiderin deposits were also found in 47,62% of canine and 31,82% of feline tumors.

**Conclusion:** We describe for the first time the expression of hepcidin in canine and feline mammary tumors. These results have profound implications on the knowledge of iron's role in mammalian carcinogenesis, particularly in the breast.

## **P8- IMMUNOHISTOCHEMICAL EXPRESSION OF MATRIX METALLOPROTEINASE 2 (MMP-2) IN FELINE FIBROADENOMATOUS CHANGE**

*Millán Yolanda<sup>1</sup>, De Maria Raffaella<sup>2</sup>, Maniscalco Lorella<sup>2</sup>, Iussich Selina<sup>2</sup>, Sánchez-Céspedes Raquel<sup>1</sup>, Guil-Luna Silvia<sup>1</sup>, Martín de las Mulas Juana<sup>1</sup>.*

*1-Edificio de Sanidad Animal, Campus de Rabanales, Cordoba University, 2-Departement of Animal Pathology, University of Turin, Turin, Italy.*

**Introduction:** Growth factors and hormones modulate matrix metalloproteinase 2 (MMP-2) expression at the intracellular and extracellular levels. Feline fibroadenomatous change (FFAC) is a non-neoplastic, progesterone-responsive condition characterized by rapid proliferation of mammary stroma and duct epithelium. The aim of this work was analyze the tissue-specific and cell-specific distribution patterns of MMP-2 in the different cellular compartments of FFAC in comparison to PR, GH and IGF-I status.

**Material and Methods:** Nineteen cases of FFAC were retrieved from histoarchives. Immunostainings were performed using the avidin-biotin peroxidase complex (ABC) method.

**Results:** Eighty four percent of cases expressed MMP-2 in the specialized stroma of FFAC lobules either exclusively (4) or with epithelial expression (12,  $p=0.0361$ ). Fibroblasts (100%) and extracellular matrix (56%) were positive. Immunoreactivity was homogeneous throughout the lesion as were PR and GH reactions, found in all cases. On the contrary, IGF-I was expressed in the same cases as MMP-2 but at the site of ductal budding exclusively. The simultaneous expression of MMP-2, GH and IGF-I in the stromal was seen in 42% cases.

**Discussion and conclusion:** These results suggest that MMP-2 participates in the proliferation of stromal compartment of FFAC together with GH and IGF-I under the influence of progesterone.

Acknowledgements: AGL2011-25553

## **P9- CYCLOOXYGENASE-2 EXPRESSION IN FELINE MAMMARY CARCINOMAS AND ADJACENT MAMMARY GLAND**

*Seixas F<sup>1</sup>, Silva S<sup>1</sup>, Pires MA<sup>1</sup>, Lopes C<sup>2</sup>*

*1-CECAV-UTAD; 2- ICBAS-UP, Portugal.*

**Introduction:** The cyclooxygenase-2 (COX-2) expression has been documented in many epithelial tumours in humans and animals. In mammary tumors of the bitch COX-2 overexpression is associated with poor prognosis. The purpose of this study was to assess the expression of COX-2 in feline mammary carcinomas and adjacent mammary gland.

**Material and Methods:** We analysed 45 primary feline mammary carcinomas and adjacent mammary gland obtained from the UTAD's Pathology Laboratory. Normal mammary tissue from queens devoid of mammary tumours was used as control. Cox-2 immunohistochemistry was performed by the modified avidin-biotin-peroxidase complex method.

**Results:** Non-neoplastic mammary gland adjacent to carcinoma showed moderate to strong membranous immunoreactivity, in most cases weaker than that observed in the carcinoma. Moderate to strong expression was also observed in control gland. Most carcinomas showed moderate or strong positivity, membranous, cytoplasmic, and occasionally perinuclear. Immunoreactivity associated with stage and invasion but not with ulceration, histological grade, vascular invasion or metastasis. However, most high grade, and metastatic carcinomas showed strong expression. In most cases carcinoma in situ immunoreactivity was similar to that observed in invasive carcinomas.

**Discussion & Conclusion:** Non-neoplastic mammary gland consistently expressed Cox-2. The Cox-2 internalization can be an early event in mammary tumorigenesis. Our results highlight the need for further studies to verify the real importance of COX-2 in the pathophysiology of mammary tissue.

## **P10- MOLECULAR CLASSIFICATION OF PRIMARY MAMMARY TUMORS AND METASTASIS IN CAT**

*Soares, M. <sup>1</sup>, Correia J. <sup>1</sup>, Murta A. <sup>2</sup>, Carvalho S. <sup>1</sup>, Ferreira F. <sup>1</sup>*

*1CIISA and 2Hospital Escolar, Faculdade de Medicina Veterinária, UTLisbon, Portugal. mariajsoares@gmail.com*

**Introduction:** Molecular classification of Human Breast Cancer is routinely performed to support therapeutic decisions. In Feline Mammary Tumours (FMT) recent studies pointed out the importance of its molecular classification as a tool to design new targets for chemo immunotherapy protocols.

**Material and Methods:** Two mammary carcinomas from two different queens and, respective regional and distant metastasis were evaluated by immunohistochemistry for HER2 (A0485, DAKO), Progesterone (PGR – 1A6, Ventana) and Estrogen (ER – SP1, Ventana) receptor expression levels. Additionally, the mitotic index (Ki-67, clone MM1, Novocastra) and the cytokeratin (AE1/AE3, DAKO) markers were also analyzed.

**Results:** In the first case, an anaplastic mammary carcinoma with a high malignancy grade (III) was positive for HER2 and cytokeratins staining in all collected tissue tumor samples. The primary mass and regional lymph nodes were similarly positive for PGR while the distant metastasis displayed a negative status. Both primary tumor and metastasis were negative to ER immunostaining. A tubulopapillary carcinoma was the classification of the second FMT case, also with high malignancy grade (III) and positive for HER2, PGR and cytokeratins but showing negative labelling for ER in all samples.

**Conclusion:** Although more studies are needed, the confirmation of a conservative molecular profiling of HER2 status between primary and metastatic tumors, is critical, in order to improve therapeutic protocols.

**P11- AN ANAPLASTIC MAMMARY CARCINOMA IN A CAT**

Soares M., Correia J., Ferreira A., Ferreira F.

CIISA, Faculdade de Medicina Veterinária, UTLisbon, Portugal. jcorreia@fmv.utl.pt

**Introduction:** In cats, the anaplastic mammary carcinoma was never reported, while in dogs is the most malignant one. Histologically, the neoplastic cells are often individualized or grouped in small nests characterized by severe anisokaryosis and anisocytosis, mitoses and multinucleated cells.

**Material and Methods:** A shorthair queen, spayed, 9 years old, presenting a large solid mammary mass was euthanized. Tumor and metastasis samples were collected to histological analysis and immunohistochemistry evaluation of HER2, estrogen and progesterone receptors, Ki-67 and cytokeratins.

**Results:** The mammary mass was classified as anaplastic mammary carcinoma, with a high malignancy grade (III). Metastatic lesions were present in the follow organs: lung, adrenal and pituitary glands, forelimb muscle, pancreas, brain, axillary and inguinal (superficial and profound) lymph nodes. The primary mass and the metastatic lesions showed positive staining for cytokeratins and HER2.

**Conclusion:** To our knowledge this is the first report of an anaplastic mammary carcinoma in a female cat. The immunohistochemical characterization allows us to confirm the epithelial nature of the tumour and the HER2 positivity, which could be correlated with the extreme aggressiveness.

**P12- A MALE CAT SQUAMOUS CELL MAMMARY CARCINOMA**

*Soares M.<sup>1</sup>, Correia J<sup>1</sup>, Bom R.<sup>2</sup>, Carvalho S.<sup>1</sup>, Ferreira F.<sup>1</sup>*

*1CIISA and 2Hospital Escolar, Faculdade de Medicina Veterinária, UTLisbon, Portugal*

**Introduction:** Feline mammary tumours (FMT) are usually very aggressive, with poor prognosis and a short survival period. As in Humans, male Cat breast carcinoma is very rare (< 1%).

**Material and Methods:** An adult male cat presenting a solid mammary mass was submitted to mastectomy. The tumor and lymph nodes were evaluated and classified according to the World Health Organization criteria. Expression of HER2, Estrogen and Progesterone receptors, Ki-67 and cytokeratin markers was evaluated by immunohistochemistry.

**Results:** The FMT was classified as a squamous cell carcinoma type with a high malignancy grade (III). The neoplasia was highly invasive with vascular infiltration and necrotic areas, showing HER2 and progesterone positivity. Microscopic metastatic lesions of the regional lymph node revealed the same histological rearrangement as the primary tumour.

**Conclusion:** To our knowledge this is the first report of a squamous cell mammary carcinoma in a male cat. The molecular classification of the FMT is still not well defined but recent studies demonstrate that HER2 is an important biological marker in Feline Oncology.

**P13- A METASTATIC LIPID-RICH CARCINOMA OF THE MAMMARY GLAND IN A CAT**

*Gal AF, Tăbăran F, Taulescu M, Bolfă P, Cătoi C.*

*University of Cluj-Napoca, Romania, adrianfloringal@yahoo.com*

**Introduction:** Our paper reports a lipid-rich mammary gland carcinoma in a cat with the gross, microscopic and immunohistochemical description of the tumor.

**Methods:** A 13-year-old intact adult female, mixed-breed cat was presented by the owner to the Faculty of Veterinary Medicine Cluj-Napoca, Romania. A complete necropsy examination was performed in our laboratory. The tissue samples were collected and processed by paraffin technique for further histological, histochemical and immunohistochemical examination.

**Results:** During the necropsy examination, a subcutaneous mass was discovered on the chest. Several variably sized, well-demarcated neoplasms were noted in the right axillary lymph node, right thoracic wall, pleura, lungs, liver, spleen and kidney. Histologically, the cells frequently formed tubuloacinar structures. The morphology of the described tumor showed features of a poorly differentiated mammary carcinoma. Numerous tumoral cells were large and polygonal, with abundant cytoplasm that showed foam-like cytoplasm. The tumoral cells contained either multiple small or large and solitary vacuoles that pushed the nucleus to the periphery of the cell. Intracytoplasmic vacuoles of the neoplastic cells were positive for Oil-Red-O and negatively with Periodic Acid-Schiff. As for immunohistochemistry, nonvacuolated and vacuolated neoplastic cells were positive for cytokeratin and negative for vimentin.

**Discussion&Conclusion:** Histochemical and immunohistochemical analysis support a diagnosis of lipid-rich mammary carcinoma. This is the second reliable record of a lipid-rich mammary

## **P14- IMMUNOHISTOCHEMICAL EVALUATION OF Ki-67, MMP-9 AND CD3+ LYMPHOCYTES IN FELINE BREAST CANCER – CORRELATION WITH CLASSIFICATION STANDARDS**

*Machado GF, Schweigert A, Melo GD, Picciuto R*

*UNESP – Univ Estadual Paulista, College of Veterinary Medicine, Araçatuba-SP, Brazil, giselem@fmva.unesp.br*

**Introduction:** Breast cancer represents the third most common tumor type in cats. Whereas numerous studies focused on prognostic markers, especially regarding post surgical life, there is still no consensus when using the WHO morphological classification or the tumor histological grading.

**Material and Methods:** 30 samples of feline breast cancer were evaluated according to the WHO classification (tubulopapilar, solid and cribriform carcinomas), and also according to the histological grading (I, II, and III) on the basis of three main features: tubule formation, nuclear pleomorphism, and mitotic count. Further MMP-9, Ki-67 and CD3+ T lymphocytes were evaluated by immunohistochemistry as possible prognostic markers.

**Results:** The CD3+ cells amount changed among the morphological groups, as well as among the histological grading. The latter classification also showed significant differences in MMP-9 staining (more intense in grades II and III), and a tendency of significance in Ki-67 staining (higher in grade III). Using the histological grading, we also observed a positive correlation between all the three immunohistochemical markers.

**Discussion and Conclusion:** The histological grading was the best classification for detect differences among the analyzed tumors. The higher the proliferative index (Ki-67) was, the greater the rate of degradation of extracellular matrix (increased labeling for MMP-9), as well as the larger amount of CD3+ T cells.



**P15- DOG'S NEOPLASIA IN PORTUGAL- A THREE YEARS DESCRIPTIVE STUDY.**

*Santos S<sup>1</sup>, Castel-Branco M<sup>1</sup>, Faisca P<sup>1,2</sup>*

*IFMV-ULHT-CICV, Lisbon – Portugal, sarasantos.med.vet@gmail.com, 2DNAtech*

**Introduction:** The present study was conducted to study dog's neoplastic lesions distribution by means of sex, age, breed, body size, and affected system using the World Health Organization (WHO) Histological Classification of Tumors of Domestic Species, in specimens received at DNAtech laboratory- Portugal.

**Materials and Methods:** A retrospective longitudinal study was applied on canine samples submitted to histological examination between 2008 and 2010. Data analysis was done with SPSS 20 software. Correlation between variables was analyzed using Cramer's V coefficient.

**Results:** Among 2678 cases, 78.4% were neoplastic lesions. From these, 36.2% were malignant and females had higher prevalence of tumors than males. The mean age of neoplastic lesions was 8.9 years with a standard deviation of 3.4 years and the majority of tumors belonged to mongrel and Poodle dogs. Of this universe, 25.6% were mesenchymal tumors of the skin and soft tissues, 25% were from the mammary gland, 23.2% were epithelial and melanocytic tumors of the skin, 13% were of the digestive apparatus, 7.0% were of the genital system, 2.3% were hematopoietic tumors, 1% were bone and joint tumors and 2% were classified into other systems and groups (respiratory, urinary, endocrine and ocular and otic tumors).

**Discussion & Conclusion:** These results pretend to contribute to the epidemiological study of canine oncology in Portugal, and to be a further step in the creation of a national oncologic registry.

## **P16- CARDIAC VALVE MYXOSARCOMA WITH THROMBOSIS OF THE RIGHT CORONARY ARTERY IN A DOG**

*Karlstam Erika, Bernodt Karin and Hård af Segerstad Carl.*

*National Veterinary Institute, Department of pathology and wildlife diseases, Uppsala, Sweden. erika.karlstam@sva.se*

**Introduction:** Myxoid mesenchymal neoplasms of the cardiac valves are uncommon, usually benign tumours in dogs. The malignant form, myxosarcoma, has rarely been described in this species. Moreover, coronary artery obstruction by aseptic thrombi, causing myocardial infarcts, are also uncommon in dogs.

This poster describes a myxosarcoma of the aortic valve leaflets with subsequent thrombosis of the right coronary artery, cardiac intramural infarcts and metastases.

**Materials and Methods:** A female dog, Golden Retriever, 11 years old, suddenly collapsed and died without any previous symptoms. A full necropsy was carried out.

**Results:** Located in close apposition to the aortic valve, causing obstruction of the aortic outflow tract, was a multinodular, cauliflower like, myxomatous neoplasm measuring approximately 3 cm in diameter. The right coronary artery was obliterated by a 2,5 centimeter long thrombus, composed of neoplastic tissue and fibrin. In the right ventricular free wall, multiple small metastases emanating from the valvular myxosarcoma were found. There was also patchy intramural fibrosis, compatible with minor chronic infarcts.

**Discussion and conclusion:** The death of the dog was caused by acute and chronic cardiac infarcts due to thrombosis of the right coronary artery. This report highlights the possibility of acute coronary artery obstruction causing sudden death in dogs with aortic valve tumours.

**P17- GLOMUS TUMOR IN THE CARPUS OF A DOG**

*Ortega J<sup>1</sup>, Sanchis F<sup>1</sup>, Rosell J<sup>1</sup>, Bolta D<sup>2</sup>, Clemente F<sup>1</sup>, Barragan A<sup>1</sup> y Viana D<sup>1</sup>.*

*1School of Veterinary Medicine, University CEU-UCH, Valencia, Spain2CV Bolta, Valencia, Spain. jortega@uch.ceu.es*

**Introduction:** The glomus tumor is an extremely rare neoplasm arising from the glomus body cells, located at the arteriovenous anastomosis, which regulate the temperature.

**Materials and Methods:** A 2 cm in diameter round mass was observed in the right carpus of a 6 year old male Schnauzer. The mass was ulcerated and painful on palpation. A punch biopsy was submitted to the Pathology Service at the University CEU-UCH.

**Results:** Histologically, the neoplasia was non-encapsulated, poorly circumscribed and infiltrative. Neoplastic cells were round to spindle, with round to oval nuclei and they were surrounding blood vessels and associated to nerve branches. Immunohistochemistry showed that neoplastic cells were strongly positive for vimentin and pan-actin.

**Discussion & Conclusion:** Based on the histological features of the neoplastic cells, the association to blood vessels and nerve branches and the immunohistochemical results, the neoplasm was diagnosed as a glomus tumor. This neoplasia showed some features of malignancy based on the classification for glomus tumor in human medicine, (i.e. infiltration, spindle cell component, etc.). However, after 1 month of prednisolone treatment, the mass decreased in size up to 1 cm, and it was completely removed without evidence of infiltration. This case suggests that further studies are necessary to know the histologic features and clinical behavior of glomus tumors in veterinary medicine.

## **P18- CO-OCCURRENCE OF HEMANGIOPERICYTOMA AND HEMANGIOSARCOMA IN A DOG**

*Sabbagh A, Tavasoli A, Rostami A, Tamimi N, Dehghan M.M*

*University of Tehran. Iran.*

**Introduction:** Hemangiosarcoma and hemangiopericytoma are soft tissue sarcomas with variable occurrence in dogs with the latter being less common.

**Methods and materials:** Scarlet a 13-year-old female terrier was referred to the small animal teaching hospital in Tehran, with two masses in the left sub-pelvic region which had increased in size during the last six months. Two separate solid, painless lumps were palpated under the skin. Radiology and ultrasonography indicated a soft tissue mass with significant vascularization. Diagnosis was combined with surgical removal as excisional biopsy and pathologic sections were prepared with H&E stain and IHC markers.

**Results:** In sections with H&E stain one mass was diagnosed as Hemangiosarcoma while the other was Hemangiopericytoma. IHC markers were positive for vimentin and negative for S100 in both of them. Hemangiopericytoma was characterized by the presence of perivascular whorls of fusiform cells that were separated by variable amounts of collagenous stroma. Hemangiosarcoma characterization was based on presence of neoplastic cells, ranging from spindle shaped to ovoid and the forming of vascular clefts in the tumor.

**Discussion:** This tumor should be differentiated from neurofibroma, meningioma, schwannoma because of their common histological features and IHC marker such as actin, vimentin and S100 were useful.

## **P19- GASTRIC HELICOBACTERIOSE AND EARLY GASTRIC CARCINOMA IN DOG: COINCIDENCE OR CONSEQUENCE?**

*Romero, D.C ; Sá ,L.R.M.*

*Laboratory of Gastroenterology, Department of Pathology, University of São Paulo, Brazil,debor.romero@usp.br*

**Introduction:** Gastric *Helicobacter* spp infection has been described associated with gastritis, peptic ulcers and gastric tumors in human for many years, but there are few reports describing *Helicobacter* infection and gastric polyps or carcinomas in domestic dogs. The aim of this report is describe and discuss a case of *Helicobacter* infection and early gastric carcinoma in a dog.

**Materials and Methods:** Six years, female, Pit Bull dog died due to coagulation disturbance and was complete necropsied. Fragments of stomach were collected and fixed for microscopic analysis.

**Results:** At gross, pyloric antrum of the stomach revealed a 150 mm diameter whitish, dome -shaped, sessile, soft nodule with smooth to irregular surface that projected into the lumen gastric mucosal. Microscopically, the nodule was characterized by focus of early gastric tubular carcinoma adjacent to hyperplastic polyp at low-power view of gastric mucosa. The antrum mucosa showed high intensity of spirochete *Helicobacter* spp organisms which were localized mixed in the superficial mucus and within the lumen of gastric glands.

**Discussion and Conclusion:** The gastric nodule was a gross finding and histopathology diagnosis was based on criterion of WHO classification in veterinary. The authors discussed against and in favor of gastric helicobacteriose and cancer in dogs and humans and concluded that more efforts were necessary to attempt the role of *Helicobacter* infection in gastric lesions of dogs.

## **P20- VISCERAL MAST CELL TUMOUR WITH HEPATOCELLULAR EMERIPOLESIS IN A YORKSHIRE TERRIER**

*Cuesta-Garcia Nerea, Lamm Catherine.*

*Veterinary Diagnostic Services, University of Glasgow, Glasgow, UK  
n.cuesta-garcia.1@research.gla.ac.uk*

**Introduction:** Emperipolesis is the process of one cell penetrating the cytoplasm of another without damage to either cell. This process is widely described in the human literature, predominantly related with non-neoplastic haematopoietic syndromes, but also in some neoplasms. In animals, it has been described in megakaryocytes engulfing normal or neoplastic haematopoietic cells. Hepatocellular emperipolesis has been described associated with neoplastic lymphocytes in cats.

**Materials and Methods:** An 8 year old Yorkshire Terrier was presented for post mortem examination. A complete necropsy was performed. Selected tissues were fixed in 10 % buffered formalin, sectioned and routinely processed for histopathologic examination.

**Results:** On gross examination, a multinodular, 6x6x10 cm, white to tan in colour, firm mass was found adherent to the mesentery and adjacent to the small intestine. Mesenteric lymph nodes were markedly enlarged and there were additional small nodules scattered throughout the mesentery. The liver was enlarged with a pebble-stone like surface. On histology, the mass was characterized as a mast cell tumour. Metastatic mast cells were present within the lymph nodes, mesentery and liver. Emperipolesis of neoplastic mast cells was evident in numerous hepatocytes.

**Conclusion:** Neoplastic mast cells have been described to invade the cytoplasm of epithelial cells (epitheliotropism) in a cat. However, to the author's knowledge, this is the first case documenting hepatocellular emperipolesis of neoplastic mast cells in a dog.

## P21- MAST CELLS AND THEIR RELATIONSHIP TO ANGIOGENESIS AND PROGNOSIS IN CANINE MELANOCYTIC TUMORS

*Cuitiño ML, Guido N, Massone A, Idiart J*

*I Becaria CIC, Bs. As. University of La Plata, Argentina, mccuitino@fcv.unlp.edu.ar.*

**Introduction:** It has been suggested that mast cells play a role in tumor progression through different mechanisms such as promoting angiogenesis. To date, only one study has analyzed the role of mast cells in angiogenesis and prognosis in canine melanocytic tumors (MTs).

**Materials and Methods:** A total of 30 cutaneous and 16 oral MTs were stained with toluidine blue and mast cell density (MCD) was determined within the tumor and at tumor periphery. Microvessel density (MVD) was determined by immunohistochemistry.

**Results:** MCD and MVD were not correlated in either cutaneous or oral MTs. In cutaneous MTs, mean MCD was  $37 \pm 8$  (SE) in dogs that were alive at 1 year post-diagnosis and  $16 \pm 4$  (SE) in dogs that died within 1 year of diagnosis ( $p=0.635$ ). In oral MTs, mean MCD was  $12 \pm 5$  (SE) in dogs alive at 1 year post-diagnosis and  $37 \pm 25$  (SE) in dogs that died within 1 year of diagnosis ( $p=0.706$ ). MCD at tumor periphery was higher than MCD within the tumor but it did not differ significantly between the survival groups in either cutaneous or oral MTs ( $45 \pm 9$  vs  $45 \pm 14$ ;  $p=0.970$  and  $53 \pm 16$  vs  $32 \pm 11$ ;  $p=0.280$ , respectively).

**Conclusion:** According to these results, mast cells in canine MTs are not clearly related to angiogenesis and they seem to have no prognostic significance for these tumors.

## **P22- EIGHTEEN MONTHS FOLLOW UP OF CASES OF MELANOMA VACCINATION – TUMORS FENOTYPE AND POST VACCINATION INFLAMMATORY REACTION**

*Henriques Joaquim<sup>1,2</sup>, Felisberto Ricardo<sup>1</sup>, Faisca Pedro<sup>2,3</sup>, Araújo Manuela<sup>4</sup>,  
Carvalho Tania<sup>5</sup>, Peleteiro Maria<sup>6</sup>*

*1) Oncovet, Lisbon, Portugal, 2) Centre for Research in Veterinary Sciences (CICV)/  
FMV – ULHT, Lisbon, Portugal, 3) DNAtch, Lisbon, Portugal, 4) INNO, Braga,  
Portugal, 5) VETPAT, Lisbon, Portugal, 6) Interdisciplinary Research Centre on  
Animal Health, (CIISA)/FMV/UTL, Lisbon, Portugal, mcpelet@fmv.utl.pt*

**Introduction:** A DNA based vaccine for canine melanoma was developed by Merial USA. It contains a gene encoding human tyrosinase which stimulates an immune response against canine tyrosinase in melanoma cells. The follow up of various vaccinated animals has been accomplished.

**Materials and Methods:** A total of fourteen dogs and one cat were vaccinated, eleven of which received the full first stage treatment of four doses of the product. Immunohistochemistry for Melan A was performed in twelve cases. For lesions that developed after the end of the vaccination, lymphocyte markers (CD3 and Pax5) were also done.

**Results:** Five out of the fourteen dogs died, three due to causes unrelated to the melanoma. Seven of the survivors developed lymph node metastases, but the disease did not progress further. Most tumors were amelanotic melanomas, 80% oral and 20% digital. Marking with Melan A was variable, but never strong (+++++) in the cases of lower overall survival. In biopsies of the lesions that developed after vaccination in one dog, T lymphocytes were much more numerous than B cells.

**Discussion & Conclusion:** The degree of Melan A marking may have a role in foreseeing the response of melanomas to immunotherapy and mobilization of T cells appears to be important in recurring lesions after vaccination.



## **P23- DYSEMBRYOPLASTIC NEUROEPITHELIAL TUMOR IN A FRENCH BULLDOG**

*Bacci Barbara, Bowman Chloe, Long Sam*

*Faculty of Veterinary Science, University of Melbourne. bbacci@unimelb.edu.au*

**Introduction:** Dysembryoplastic neuroepithelial tumor (DNET) is a mixed glioneuronal tumour which is most commonly seen in the temporal lobe of young adults. Due to its mixed nature WHO histological classification of brain tumors included it into the group of neuronal and glial-neuronal mixed tumors. Cortical dysplasia is frequently reported in the vicinity of DNETs, suggesting that the tumors may have a malformative basis of origin.

**Materials and Methods:** A 12 year old male French bulldog presented for a two-day history of generalized tonic-clonic seizure activity, and a longer history of intervertebral disc disease. Neurological examination revealed a mild spinal ataxia in both hindlimbs. The dog was euthanased without further diagnostic tests being pursued. A full postmortem examination was performed, tissues were processed and stained with Haematoxylin and Eosin (HE). Immunohistochemistry was performed with GFAP, Vimentin, NeuN, S100, Synaptophysin,  $\alpha$ SMA, CD3, CD79, ChromograninA, EMA, Progesteron Receptor (PR), CD34.

**Results:** In the cortex of the right olfactory lobe there was a mass composed of oligodendrocyte-like cells –OLCs (S100-positive, GFAP-negative) embedded in a mucinous matrix and admixed with dysplastic neurons (NeuN-positive) and reactive astrocytes (GFAP-positive). At the periphery of the neoplasm OLCs were arranged along white matter tracts and adjacent cortical neurons showed loss of architecture and polarity (cortical dysplasia). The mass extended in the septum where neoplastic cells exhibited marked pleomorphism and angiocentric arrangement.

**Discussion:** The morphological and immunohistochemical features in this dog were reminiscent of human DNET. Due to the paucity of veterinary literature and its heterogeneous cellular composition, DENT can present difficulties in diagnosis and requires differentiation from other glial neoplasms.

## **P24- FELINE CUTANEOUS NERVE SHEATH TUMOURS (CNSTs): HISTOLOGICAL FEATURES AND IMMUNOHISTOCHEMICAL EVALUATIONS.**

*Mandara MT<sup>1</sup>, Fabriani E<sup>1</sup>, Pavone S<sup>1</sup>, Pumarola M<sup>2</sup>*

*1Faculty of Veterinary Medicine, University of Perugia, Italy,; 2Facultat de Veterinària, Universitat Autònoma de Barcelona, Spain. mandara@unipg.it*

**Introduction:** Feline CNSTs are commonly underestimated. We define histomorphological and immunohistochemical features useful in the differential diagnosis with the most common mesenchymal tumours.

**Materials and Methods:** Twenty-six CNSTs were examined. Antoni type A and B patterns, cellular polymorphism, cellular type, nucleoli, mitotic index (MI), collagen, mucopolysaccharidic material, necrosis, inflammatory cells, and metaplasia were considered. Immunohistochemistry (IHC) was performed for S-100, vimentin, NSE, GFAP, laminin, SMA, PGP 9.5, NGFR, and Ki67.

**Results:** All the CNSTs showed Antoni type A. In the malignant tumours (MCNSTs) polymorphism and MI were higher than in the benign tumours (BCNSTs). Necrosis was observed in three cases, osseous/chondroid metaplasia was found in two cases. Vimentin was expressed in all the tumours, S-100 did in 17 cases (81.8% of BPNSTs, 57.14% of MPNSTs). 25 tumours expressed NSE and 24 cases expressed laminin. 50% of tumours expressed GFAP. Five tumours showed a rhabdomyoblastic differentiation. PGP 9.5 expression was detected in 24 cases, NGFR expression in eleven cases. Twenty tumours expressed Ki67.

**Conclusions:** Morphological criteria of human and domestic animal classification of PNSTs are recognizable in feline CNSTs. In the absence of S-100 expression, a concurrent expression of vimentin, NSE and laminin supports the diagnosis of CNSTs. Data on the diagnostic relevance of PGP 9.5 and NGFR-expression in feline CNSTs were not conclusive.

**P25- NEUROENDOCRINE CARCINOMA IN THE NASAL CAVITY OF A CAT.**

*Resende Luís<sup>1</sup>, Pereira Hugo<sup>1,2</sup>, Godinho Ana<sup>1</sup>, Carvalho Inês<sup>3</sup>, Melo Marta<sup>3</sup>, Anagua Marly<sup>1</sup>, Faisca Pedro<sup>1</sup>*

*1 FMV – ULHT, CICV, Lisbon – Portugal. 2 Hospital Veterinário do Restelo. 3 DNAtch pedrofaisca@ulusofona.pt*

**Introduction:** A 4 years old, neutered male, domestic short hair cat presented, with a history of non-responsive rapid progressive chronic rhinitis with exophthalmia of the right eye, depression and tremors.

**Material and Methods:** A CT-Scan was schedule and revealed a soft tissue mass extending from the caudal aspect of the right nasal cavity to the right frontal lobe of the encephalon.

**Results:** On necropsy a non-encapsulated, pinkish-white, friable, soft tissue mass was observed fulfilling the right nasal cavity, and extending to the right olfactory bulb, with lysis of the palatine and ethmoid bone. On histopathology a non-encapsulated mass was observed, presenting a proliferation of medium size columnar cells organized in sheets and nests separated by a fine fibrovascular stroma. Peripheral palisading of tumor cells was multifocally observed. The cells had a granular eosinophilic cytoplasm and a round, central to eccentric dense nuclei. The mitotic figures were rare, but necrosis, mineralization and bone lysis were evident. Paraffin-embedded sections showed strong positive cytoplasmic cytokeratin and NSE staining, while immunostaining for vimentin and S-100 was negative.

**Conclusion:** These results were consistent with a nasal neuroendocrine carcinoma. The major differential diagnosis is esthesioneuroblastoma, however the distinct granular cytoplasm of the neoplastic cells and the absence of prominent rosette formation associated with the immunostaining favors neuroendocrine carcinoma.

## P26- CANINE SEMINOMAS – DIFFERENTIATION INTO CLASSICAL AND SPERMATOCYITICAL SEMINOMAS

*Hohšteter M<sup>1</sup>, Artuković B<sup>1</sup>, Ćorić M<sup>2</sup>, Severin K<sup>1</sup>, Gudan Kurilj A<sup>1</sup>, Beck A<sup>1</sup>, Sabočanec R<sup>1</sup>, Šoštarić-Zuckermann IC<sup>1</sup>, Grabarević Ž<sup>1</sup>*

*1Veterinary Faculty, University of Zagreb, Croatia, 2Clinical Health Center Zagreb, Croatia. hohi@vef.hr*

**Introduction:** Seminomas are one of the most common dog testicular tumors. In humans, seminomas are classified into classical (CS), which are c-KIT positive and malignant, and spermatocytical (SS) which are c-KIT negative and benign. Despite the fact that almost all canine seminomas have benign behaviour, there are few references which discuss the possibility of their differentiation into CS and SS. The aim of our study was to determine incidence of canine testicular neoplasia and confirm assumption that canine seminomas can be classified into CS and SS.

**Material and Methods:** Histopathological and immunohistochemical (c-KIT) analysis of 59 biopsied dog testicles was performed.

**Results:** A total of 57 (96.61%) tumors were found. Diagnosed tumors were (listed in order of decreasing frequency): seminomas, Sertoli cell tumors, mixed tumors, Leydig cell tumors, undifferentiated intratubular germ cell neoplasia, peripheral nerve sheath tumor and teratoma. c-KIT was expressed in 26.32% of all tumors with higher expression in germ cell tumors. c-KIT was positive in 40.09% of seminomas, 44.44% of mixed seminomatous tumors and only diagnosed teratoma.

**Discussion & Conclusion:** Different c-KIT expression in seminomas confirmed that canine seminomas can be classified into two groups: more prevalent c-KIT negative SS and less prevalent c-KIT positive CS.

**P27- A CASE OF SCROTAL LEIOMYOSARCOMA IN A DOG**

*Laloy Eve, Chateau-Joubert Sophie, El Mrini Meryem, Rakotovao Farasoa, Carlus Marine, Reyes-Gomez Edouard, Delfosse Vincent, Cordonnier Nathalie.*

*National Veterinary School of Alfort, France, elaloy@vet-alfort.fr*

**Introduction:** Scrotal smooth muscle tumors are uncommon tumors in man. They arise from the tunica dartos of the scrotum. They have not been reported in animals.

**Materials and Methods:** A 6-year-old male Sharpei dog presented with a single 1-cm-in-diameter mass arising from the left scrotum. Surgical excision was performed and the nodule was fixed in 10% neutral buffered formalin, processed routinely and embedded in paraffin wax. Sections were stained with haematoxylin and eosin (HE). Several sections were subject to immunohistochemistry (IHC).

**Results:** The neoplasm was well circumscribed but unencapsulated. It showed multifocal contiguity with the dartos smooth muscle bundles. It was made of short interlacing bundles of plump spindle cells within minimal collagenous stroma. The neoplastic cells had abundant eosinophilic cytoplasm and oval to elongated nuclei. Moderate anisokaryosis and anisocytosis were seen. There were 7 mitotic figures per 10 high power fields (40x). Small focal areas of necrosis were present. The neoplastic cells were positive for vimentin and smooth-muscle actin while they were negative for melanA, glial fibrillary acidic protein (GFAP) and S100. A few cells were positive for desmin.

**Discussion & Conclusion:** The histological and immunohistochemical findings were most consistent with a scrotal leiomyosarcoma. This is the first report of scrotal leiomyosarcoma in a dog.

## **P28- MESOTELIOMAS OF THE TUNICA VAGINALIS TESTIS IN THE DOG: AN UNCOMMON NEOPLASM WITH MALIGNANT BEHAVIOUR**

*Ramírez GA<sup>1</sup>, Suárez-Bonnet A<sup>2</sup>, Espinosa-de-los-Monteros A<sup>2</sup>, Altimira J<sup>1</sup>, Vilafranca M<sup>1</sup>. [gramirez@histoweb.com](mailto:gramirez@histoweb.com)*

*IHISTOVET Lab., 2Las Palmas de Gran Canaria University, Spain.*

**Introduction:** Mesotheliomas of the tunica vaginalis testis are extremely rare. The aim of this work is to describe the clinical, histological and immunohistochemical features as well as the clinical outcome of this neoplasm in the dog.

**Material and Methods:** Our records were reviewed for dogs with a diagnosis of testicular mesotelioma made between 1995 and 2011. Clinical histories and follow-up information were obtained from referring clinicians. Diagnoses were confirmed by re-review of paraffin-embedded specimens. Immunohistochemistry was also performed with a panel of antibodies including cytokeratins, vimentin and CEA.

**Results:** Cases were presented as swelling of the scrotum. Ultrasonography revealed heterogeneous and irregular masses with a mixed echogenicity; anechoic effusion surrounding the affected testicles (hydrocele) was also common. Gross examination often revealed firm, polypoid or papillary, yellow to white masses with a solid cut surface. The tunica vaginalis was thickened, studded with nodules of varying size, and diffusely calcified in one case. Invasion of spermatic cord was commonly seen. Microscopically, tumors presented epithelial features with papillary, tubulopapillary, or solid patterns and consistently expressed cytokeratins and vimentin. Postoperative recovery was always uneventful but worsening of general health condition was reported in a period less than 7 months. Necropsy, when performed, confirmed abdominal metastatic disease.

**Conclusion:** Mesothelioma of the tunica vaginalis testis in the dog is a rare malignant neoplasm with an aggressive behaviour and poor outcome.

## **P29- ENDOMETRIAL ADENOCARCINOMA IN A CAT WITH ABDOMINAL MESTASTASIS – CASE REPORT**

*Pires MA<sup>1</sup>, Saraiva AL<sup>1,2</sup>, Vilhena H<sup>2,3</sup>, Miranda S<sup>2,3</sup>, Fonseca F<sup>3</sup>, Moreira P<sup>3</sup>, Alves AM<sup>3</sup>, Paiva R<sup>4</sup>, Payan-Carreira R<sup>1</sup>*

*ICECAV-ECAV-UTAD, Vila Real, Portugal, ,2EUVG, Coimbra, Portugal,3HVBV, Águeda, Portugal, 4SMVB, São Pedro do Sul, Portugal,apires@utad.pt*

**Introduction:** Uterine adenocarcinomas are considered rare tumours in animals except for rabbit and cows. Still, our recent work found that feline endometrial adenocarcinoma (FEA) might be more frequent than reported, which might be associated with absence of routine examination of ovariohysterectomy (OVH) surgical specimens.

**Material and Methods:** A ten-year old shorthair queen was presented due to anorexia and abdominal pain. Abdominal ultrasonography (US) evidenced pyometra and peritonitis. The female was under prolonged progesterone-based contraception. During OVH, co-existence of uterine rupture was found and the excised organs were sent to histopathology examination.

**Results:** Gross examination showed distinct diameters of the uterine horns and a continuity defect in the cranial portion of the left horn. A papillary serous adenocarcinoma of the endometrium was diagnosed, with deep wall invasion and breakthrough the myometrium and serosa. The animal was presented 4 weeks later with clinical signs of ascites. Abdominal US showed a liver mass and ascites, and cytology was suggestive of metastatic disease. 3 weeks later, euthanasia was requested by owners. Permission for necropsy was denied.

**Discussion & Conclusion:** This case reports a FEA with peritoneal carcinomatosis associated with abdominal spread of the tumour by anatomical contiguity and tumour cell implantation.

## **P29 bis- IMMUNOHISTOCHEMICAL EXPRESSION OF CYCLOOXYGENASE-2 (COX-2) IN FELINE ENDOMETRIAL ADENOCARCINOMAS: A PRELIMINARY STUDY**

*Saraiva AL<sup>L2</sup>, Gärtner F<sup>3,4</sup>, Payan-Carreira R<sup>2</sup>, Rema A<sup>3</sup>, Lourenço LM<sup>5</sup>, Pires MA<sup>2</sup> IEUVG, Coimbra, Portugal, analaurasaraiva@gmail.com 2CECAV-ECAV-UTAD, Vila Real, Portugal 3ICBAS-UP, Porto, Portugal 4IPATIMUP, Porto, Portugal 5UTAD, Vila Real, Portugal*

**Introduction:** Evidence for the association of COX-2 and tumorigenesis has been established and its presence shown in several canine and feline tumours. This study aims to characterize COX-2 expression in feline endometrial adenocarcinomas (FEA) in comparison with normal endometrium.

**Materials and Methods:** 34 samples of FEA were identified on conventional haematoxylin and eosin-stained sections. 9 samples of normal feline uterus during estrogenic and 7 samples during progestagenic phase were used as controls. Immunolabelling was performed by the indirect avidin-biotin-peroxidase immunohistochemistry method, using the antibody against COX-2 (clone SP21; Neomarkers & LabVision Corporation™; 1:75).

**Results:** FEA were morphologically classified as papillary serous, clear cell and “in situ” carcinomas. COX-2 score was high in glandular epithelial cells of normal uterus, in superficial epithelium of estrogenic uterus and in 5 cases of progestagenic uterus. This labeling occurred preferentially on the apical cell membrane. 24 tumours expressed a high score of COX-2 expression. In neoplastic cells, the labeling was found in the entire membrane, cytoplasm and nuclear envelope area.

**Discussion and Conclusion:** Loss of compartmentalization of COX-2 expression in most FEA may reflect the involvement of this enzyme in feline endometrial carcinogenesis. Further studies must be performed to accurate our results and to achieve potential clinical impact.



### **P30- EXPRESSION OF CELL CYCLE REGULATORS, 14-3-3 $\sigma$ AND P53 PROTEINS, AND VIMENTIN IN CANINE TRANSITIONAL CELL CARCINOMA OF THE URINARY BLADDER**

*Suárez-Bonnet A, Herráez P, Quesada O, Andrada M, Jaber R, Espinosa de los Monteros A.*

*Universidad de Las Palmas de Gran Canaria. Facultad de Veterinaria.  
asuarez@becarios.ulpgc.es*

**Introduction:** Canine TCC shows striking similarity to human bladder cancer, however little is known of the molecules implicated in canine TCC. The aims of our study was to dilucidate if there are alterations in the expression of molecules especially intricated in cancer development as the tumor suppressors p53 and 14-3-3 $\sigma$  and also vimentin.

**Material and Methods:** Nineteen canine bladder tumours cases and 2 normal bladder tissues were retrieved from our tissue archives. All samples had been fixed in 10% neutral buffered formalin and embedded in paraffin wax. Monoclonal antibodies against 14-3-3 $\sigma$ , p53 and vimentin and the EnVision™ immunohistochemical technique were employed. The reactions observed were semiquantitatively analyzed.

**Results:** Expression of 14-3-3 $\sigma$  was decreased in 53% of cases, p53 protein was over-expressed in 26% of cases and vimentin was neo-expressed in 21% of cases. Vascular invasion was observed in three cases and showed moderate to strong staining of both 14-3-3 $\sigma$  and vimentin.

**Discussion & Conclusion:** The pattern of expression of 14-3-3 $\sigma$  indicates a probable role in the carcinogenesis and invasion mechanisms of canine TCC. The expression of vimentin in infiltrative cells reflexes the acquisition of an epithelial-mesenchimal transition that could lead to greater likelihood of metastasis. Finally, p53 appears to contribute to develop TCC with high frequency than previously thought.

**P31- SALIVARY GLAND CARCINOSARCOMA IN A DOG**

*Osińska Barbara, Dolka Izabella*

*Warsaw University of Life Sciences-SGGW, Warsaw, Poland, osinskab@op.pl*

**Introduction:** Carcinosarcoma of salivary gland is very rare and aggressive tumor of dogs and human.

**Materials and Methods:** A deformation of the submandibular salivary gland from a 7 year old, male dog, dachshund. The surgical specimen was fixed in 10% buffered formaldehyde and embedded in the paraffin wax, sectioned and stained with the use of H&E. The periodic acid Schiff's (PAS) reaction and immunohistochemical methods were as follows: cytokeratin, vimentin, S-100 protein, P-63, F-8, Ki-67.

**Results:** The microscopic investigation revealed cells round and fusiform as well as nuclear pleomorphism and prominent nucleoli existence. The focal necrosis and elements of chondrosarcoma and osteosarcoma were also observed. The immunohistochemical staining for cytokeratin, vimentin, S-100 protein, P-63, F-8 and Ki-67 in some tumor cells were positive of a different degree.

**Conclusion:** The tumor was recognized as salivary gland carcinosarcoma.

### **P32- ASSESSMENT OF EGFR AND HER-2 EXPRESSION AND KRAS-STATUS IN CANINE GASTRIC TUMORS**

*Bettini G<sup>1</sup>, Casadei Gardini A<sup>2</sup>, Terragni R<sup>3</sup>, Capelli L<sup>2</sup>, Morini M<sup>1</sup>, Sabattini S<sup>1</sup>, Vignoli M<sup>3</sup>, Saunders JH<sup>4</sup>, Ulivi P<sup>2</sup>*

*1 DSMVet, University of Bologna; 2 IRST, Meldola; 3 CVO, Sasso Marconi – Italy; 4 DMI, Ghent University, Belgium. giuliano.bettini@unibo.it*

**Introduction:** Epidermal growth factor receptor (EGFR or HER1) and its homolog c-erbB-2 (HER2) are tyrosine-kinase-receptors related to prognosis and response to therapy overexpressed in several human and animal cancers. KRAS mediates the transduction of signals between EGFR and the nucleus, and KRAS mutations has been identified as predictors of resistance to anti-EGFR drugs. In human oncology the importance of HER1-2/KRAS signaling pathway in gastric cancer is established, and accurate HER testing is considered necessary. On the contrary, this pathway has never been investigated in canine gastric tumors.

**Materials and Methods:** A total of 16 canine gastric tumors (4 adenomas and 12 carcinomas) were retrospectively studied by immunohistochemistry (EGFR and HER-2) and 9 cases (2 adenomas and 7 carcinomas) underwent Direct Sequencing for KRAS analysis.

**Results:** EGFR was mildly expressed (1+) in 2 carcinomas and overexpressed in 50% of adenomas. HER-2 was overexpressed (2+, 3+) in all cases; KRAS was always wild type.

**Discussion:** HER2 is overexpressed in canine gastric tumors; in contrast, EGFR overexpression is mostly limited to adenomas. EGFR/HER2 expression in gastric adenomas suggests their possible progression to carcinomas. Testing and therapeutic targeting of HER2 may be promising in canine gastric cancer, and advocates to consider the dog a suitable model for human gastric cancer.

### **P33- ASSESSING INTERACTIONS BETWEEN CANINE BCL-2 FAMILY PROTEINS IN YEAST (*Saccharomyces cerevisiae*)**

*de Brot S, Guscetti F. Institute of Veterinary Pathology, University of Zurich.  
simonedebrot@yahoo.de*

**Introduction:** Yeast can be used for functional studies of Bcl-2 protein family members. Upon overexpression of human pro-apoptotic proteins such as Bak or Bax, they display an apoptosis-like type of cell death which can be prevented by concomitant overexpression of anti-apoptotic members such as Bcl-2. In the present study, we set up a test system in the yeast to explore interactions between canine Bcl-2 family proteins.

**Materials and Methods:** Previously generated cDNAs for the anti-apoptotic proteins Bcl-xL, Bcl-w and Mcl-1 and the pro-apoptotic molecules Bak and Bax were subcloned into pESC yeast expression plasmids. All plasmids were transformed into BY4743 cells to yield yeasts able to express individual or pairs of pro- and anti-apoptotic proteins. Cell death was measured using a clonogenic assay. Protein expression was confirmed by Western blot analysis and immunofluorescence.

**Results:** The canine pro-apoptotic Bcl-2 family proteins Bak and Bax induced clonogenic cell death when expressed in yeast, while anti-apoptotic proteins Bcl-xL, Bcl-w and Mcl-1 did not. Furthermore, each anti-apoptotic protein abrogated the effect of the pro-apoptotic molecules.

**Discussion and Conclusion:** Interactions between Bcl-2 family members of canine origin can be reproduced in this test system, including the interplay between Bax/Bak and Bcl-w that has not been previously reported in yeasts. Potential future applications of this system include functional studies of BH3-only proteins, functional screens of tumour cell cDNA libraries and testing anti-tumour drugs targeting apoptosis.

### **P34- PATHOLOGY AND CLINICAL DATA INTEGRATED IN ARTIFICIAL NEURAL NETWORKS FOR PROVIDING PROGNOSTIC IN CANCER**

*Gaita L., Militaru M.*

*University of Agronomic Sciences and Veterinary Medicine of Bucharest, Romania,  
clinica@ortovet.ro*

**Introduction:** One of the oldest – and yet most actual – medical challenges is the prediction of the most probable outcome of a disease in a given patient, based on the clinical and pathology information and a therapy scenario.

**Materials and Methods:** A model based on Artificial Neural Networks (ANN) was designed and programmed. The input data (over 120 parameters) include histology type and grade of tumours, morphometry and fractal dimension of microscopic images of lesions, clinical and para-clinical data, quality of life, and treatment. The key output is life expectation for dogs and cats with cancer, but many input parameters can be turned into unknowns and the network asked to provide an estimate.

**Results:** The ANN was tested on a smaller set of 27 criteria and 39 cases of cancer in dogs to develop appropriate architecture and learning strategies. Robustness and predictive performance were confirmed. As previously reported, we also found overfitting/overtraining to be the most serious pitfall that needs to be addressed. The complete model is growing and learning.

**Discussion & Conclusion:** ANN are one very promising way to respond to the growing interest for Evidence Based Medicine methods applied in veterinary practice. ANN provide a lean approach for integrating in the current diagnostic and prognostic procedures some new or still ‘exotic’ pathology information, like fractal dimensions of histology images.

### **P35- PATHOLOGIC AND IMMUNOHISTOCHEMICAL FEATURES OF A TUBULOPAPILLARY CARCINOMA IN A MARE**

*Perez-Ecija Alejandro, Mendoza Francisco, Estepa José.*

*Veterinary Faculty. University of Cordoba, Córdoba. Spain.v02peecr@uco.es.*

**Introduction:** Mammary tumors are extremely rare in equine pathology. Due to its uncommon appearance, this kind of tumor is not well studied and there is a lack of information related to its immunohistochemical features.

**Materials and Methods:** A 15 years old mare, Andalussian breed, was euthanized due to a slow growing painful mass compromising both mammary glands. The animal presented a serous secretion from one teat but no other symptom was recorded.

**Results:** At necropsy both mammary glands were almost completely substituted by a yellowish solid to granular growth with a rubbery consistence. The tumor did not invade the abdominal muscles but expanded through the adjacent subcutaneous planes. Nodules with this same appearance were observed in the lungs, tracheobronchial lymph nodes and superficial inguinal lymph nodes. Microscopically the tumor was consistent with a highly aggressive tubulopapillary carcinoma with widespread metastasis and local invasion. An immunohistochemical study was developed in order to characterize the tumor, its metastases and the surrounding reaction using antibodies against vimentin, CD3, CD79, HLA, cytokeratins and Ki67.

**Discussion & Conclusion:** Here we present the study of a highly aggressive tubulopapillary carcinoma in a mare with widespread metastasis. With the detailed immunohistochemical study description of this type of tumor we intend to establish the methodological approach to this rare equine pathology.

### **P36- VERRUCOUS HEMANGIOMA WITH PSEUDOCARCINOMATOUS EPIDERMAL HYPERPLASIA IN A HORSE**

*Perez-Ecija Alejandro, Estepa Jose, Barranco Inmaculada, Rodriguez-Gomez Irene, Mendoza Francisco, Gomez-Laguna Jaime.*

*Veterinary Faculty. University of Cordoba, Córdoba. Spain.v02peecr@uco.es.*

**Introduction:** Verrucous haemangiomas are a rare variant of equine skin tumours not well described in the literature. These tumours are characterized by a plaque-like, dark, hyperkeratotic appearance; a slow growth and a typical location in the distal limbs.

**Materials and Methods:** An eight years old Andalusian gelding was presented to the Veterinary Teaching Hospital with a unilateral insidious lesion on the plantar aspect of the right hindlimb pastern. The lesion presented an evolution of two years, with persistent episodes of progression and involution without a seasonal pattern.

**Results:** Macroscopically, the mass showed a warty, papillomatous and verrucous surface with a brown colour due to hyperpigmentation and focal ulcerations. A punch biopsy revealed a nodular mass expanding from the dermis-epidermis junction to the deep dermis. The microscopic and immunohistochemical findings lead to the final diagnosis of a verrucous haemangioma. A striking pseudocarcinomatous epidermal hyperplasia with presence of squamous eddies was also observed in this animal, what could have lead to a misdiagnosis.

**Discussion & Conclusion:** Here we describe a verrucous haemangioma in an adult gelding with striking epidermal changes, confirmed by immunohistochemistry. The concomitant dermal neoplasia and epidermal pseudocarcinomatous hyperplasia with squamous eddies emphasize the necessity of a careful evaluation of dermal masses in horses in order to recognize the primary process.

### **P37- CONGENITAL ASCITES DUE TO HEPATOBLASTOMA WITH EXTENSIVE PERITONEAL IMPLANTATION METASTASES IN A PREMATURE EQUIN FETUS.**

*de Vries C<sup>1</sup>, Rocha PRD<sup>2</sup>, Vanhaesebrouck E<sup>1</sup>, Govaere J<sup>1</sup>, Hoogewijs M<sup>1</sup>, Bosseler L<sup>1</sup>, Chiers K<sup>1</sup>, Ducatelle R<sup>1</sup>,*

*1Ghent University, Belgium, 2University of Turin, Italy, pauloricardo.dellarmelinarocha@unito.it*

**Introduction:** Only 11 cases of equine hepatoblastoma have been reported. This work reports the first case of equine hepatoblastoma with extensive peritoneal metastases and ascites, without involvement of other organs, in animals.

**Materials and Methods:** At 317 days of gestation, extreme force was necessary to extract a dead, female, Belgian Warmblood filly. The foal was submitted to a full necropsy, including histopathological and immunohistochemical examination.

**Results:** Necropsy revealed an irregular, bulging, solitary mass (25 cm in diameter) in the right liver lobe and obvious ascites. Metastases were present in the left liver lobe, peritoneum and on serosal surfaces of stomach, diaphragm, spleen and intestine. Histopathology revealed a densely cellular neoplasm. Embryonal epithelial cells were arranged in sheets and nests in a loosely arranged fibrous stroma. The polygonal tumor cells were 15-18 µm in diameter, had a scant, eosinophilic cytoplasm, a single, round, central, basophilic nucleus with finely stippled normochromatic chromatin and a single basophilic nucleolus. There was mild anisocytosis and anisokaryosis. Mitotic figures were rare. The neoplastic cells stained diffusely positive for alpha-feto protein (AFP) and multifocally positive for pancytokeratin and Low-Molecular-Weight cytokeratin.

**Conclusion:** Peritoneal metastases of hepatoblastoma without involvement of other organs suggests an unusual peritoneal spread of hepatoblastoma, which has never been described in animals before.



### **P38- TELOMERASE ACTIVITY AND TELOMERE LENGTH IN CATTLE INFECTED WITH BOVINE LEUKEMIA VIRUS (BLV)**

*Szczotka M., Kuzmak J.*

*National Veterinary Research Institute, Pulawy, Poland, szczotka@piwet.pulawy.*

**Introduction:** The bovine leukemia virus (BLV), a member of the Deltaretroviridae family is a causative agent of bovine leukemia. Telomerase is a telomere – synthesizing reverse transcriptase, that can compensate for the loss of telomere associated with cell division. Telomerase activity is expressed in most human tumor tissues, but not in normal tissues, except those of the germline ( ovaries/testes ).

**Materials and Methods:** Telomerase activity was determined with the use of PCR-ELISA method in blood sera, lymphatic organ cells and dendritic cells generated from lymphatic tissues of BLV infected cattle. Telomere length was estimated with the use of flow cytometry. Human tumor cell lines: HeLa, Jurkat and 1301 were used as positive control.

**Results:** Telomerase activity was detected in all samples collected from leukemic animals. Very high relative telomerase activities (RTA>86) were found in dendritic cells, sera of cattle with lymphocytosis (RTA=79) and in FLK-BLV cell line (fetal lamb kidney cells persistently infected with BLV=RTA=93). Telomeres were much shortened in samples of leukemic animals.

**Discussion & Conclusion:** High telomerase activity and shortened telomeres almost always correlate with disease severity in lymphoproliferative disorders. Measurement of telomere length and telomerase activity might be useful to monitor disease condition, and as well prognostic marker and therapeutic target in therapy of tumors.

### **P39- MORPHOPATHOLOGICAL STUDY OF NATURALLY OCCURRING VULVAR AND VAGINAL SQUAMOUS CELL CARCINOMA IN CATTLE**

*Motaghypisheh M, Shirian S,*

*Department of Pathology, %Khodakaram-Tafti A, School of Veterinary Medicine, Shiraz University, Shiraz, Iran, tafti@shirazu.ac.ir*

**Introduction:** Vulvar and vaginal carcinomas, including squamous cell carcinomas (SCC) are rare in all species, with the exception of solar-induced SCCs of sheep and cattle in tropical countries. The objective of this study is to describe the morphopathological characteristics of naturally- occurring SCC in the vulva and vagina of cattle in Iran.

**Materials and Methods:** In this study, 9 female Holstein cattle, aged between 4-9 years-old, affected with SCC of the vulva and vagina were examined clinicopathologically. After local or epidural anaesthesia, the masses were removed surgically. Samples of the masses were fixed in 10% neutral-buffered formalin, processed routinely, and stained with haematoxylin and eosin.

**Results:** Gross appearances of the tumors were variable from nodular, round, oval to cauliflower-like masses protruding from the surface, and varied in size from 2 x 2 x 3 to 6 x 6 x 10 cm in dimension. Histopathologically, variable malignancy from well to poorly differentiated SCCs which invaded into the subepithelial tissues were diagnosed. Seven tumors had no remarkable keratin pearls. No evidence of metastasis to regional lymph nodes was observed.

**Discussion & Conclusion:** There are several factors associated with the development of a SCC, including breed, prolonged exposure to ultraviolet light, lack of pigment within the epidermis, and lack of hair at the affected sites. It seems SCC of vulva and vagina is locally invasive without metastasis to the regional or distant lymph nodes. Therefore, surgical excision at an early stage of the disease can lead to a fair prognosis.

## **P40- ASSOCIATION OF BPV-2 INFECTION AND BOVINE URINARY BLADDER TUMORS FROM NORTH CENTRAL REGION OF ROMANIA**

*Taulescu Marian, Valentin Balteanu, Gal Adrian, Bolfă Pompei, Laura Farcas, Gabi Borza, Andras Nagy, Flaviu Tabaran, Bogdan Sevastre, Cătoi Cornel.*

*Faculty of Veterinary Medicine, Cluj-Napoca, Romania, taulescumarian@yahoo.com*

**Introduction :** In cows, urinary bladder tumors are often associated with chronic Pteridium spp intoxication and Bovine papillomavirus type 2 (BPV-2) infection. The objective of this work consisted in evaluation of BPV-2 infection in cows with urinary bladder tumors and naturally exposed to Bracken fern from North Central region of Romania where chronic enzootic hematuria is endemic.

**Material and methods :** For this study, 400 slaughtered cows originating from hill-mountain area of Maramures, Mures and Bistrita-Nasaud counties were examined. Gross, histological, immunohistochemical (pan-CK, CD31, vimentin and CD3) and polymerase chain reaction (PCR) analysis for BPV-1, 2 and 4 types were performed.

**Results :** Gross, 18 urinary bladders lesions were divided as diffuse thickening and irregular mucosa (3), solitary or multiple papillary growths (10) and red-brown nodules (5). Pan-CK expression was found in 2 squamous carcinomas, one infiltrative adenocarcinoma, 4 non-invasive papillary carcinomas, two invasive papillary carcinomas and 5 polyps. Vimentin and CD31 were positive in four haemangioma and one lymphangioma. Furthermore haemorrhages and mononuclear cells (CD3+) infiltrate were identified in all cases. Through PCR, BPV-2 infection was indentified in 12 cases. BPV-1 and BPV-4 was not detected.

**Conclusions :** Finally, we can conclude that BPV-2 infection has an important role in urinary bladder carcinogenesis in cows from this region of Romania.

**P41- RUMINAL LEIOMYOSARCOMA AND NATURALLY OCCURRING *Calicophoron daubneyi* INFECTION IN A COW**

<sup>1</sup>Ferreras M C, <sup>1</sup>Pérez V, <sup>1</sup>González-Lanza M C, <sup>1</sup>Benavides J, <sup>2</sup>Mezo M, <sup>1</sup>Fuertes M, <sup>2</sup>González-Warleta M, <sup>1</sup>Delgado L, <sup>1</sup>Martínez-Ibeas A, <sup>1</sup>Manga-González M Y.

*1*Instituto de Ganadería de Montaña CSIC-ULE, Dpt de Sanidad Animal, Facultad de Veterinaria, Universidad de León, Campus de Vegazana s/n, 24071 León.  
*2*Centro de Investigaciones Agrarias de Mabegondo, 15318 Mabegondo, A Coruña, [mcfere@unileon.es](mailto:mcfere@unileon.es)

**Introduction:** Malignant tumours of the forestomachs have been considered as very rare. In ruminants no cases of connective malignant neoplasms have been reported to date.

**Material and Methods:** Between June 2010 and July 2011, a total of 656 slaughtered calves from different herds in the Castilla y León region (Spain) were examined for the presence of trematode flukes in the forestomachs. In a 15-year-old cow a tumour was observed in the rumen.

**Results:** An ulcerated and pedunculated yellowish solitary mass was observed projecting into the ruminal lumen. Histologically, pleomorphic spindle cells arranged in fascicles, stained in red with Masson's trichrome was seen. Anisokaryosis, scattered mitosis and giant cells were also observed. The tumour cells eroded the epithelium and were occupying the lamina propria-submucosa. The internal muscular layer was disrupted. Immunohistochemically, this tumour show features of smooth muscle differentiation. A few flukes of *C. daubneyi* were detected in ruminal atrio.

**Discussion & Conclusion:** With all the above findings, a diagnosis of ruminal leiomyosarcoma coexisting with paramphistomosis was confirmed. To author's knowledge, this seems to be the first report of ruminal leiomyosarcoma in cattle.

This work was supported by grant LE023A10-2 from Junta de Castilla y León.

## **P42- COEXISTENCE OF SEVERAL PRIMARY TUMORS IN AN ADULT GOAT**

*Moreno B, Jirón, W, Marcuello P, Badiola JJ, Marín B.*

*Centro de Investigación en Encefalopatías y Enfermedades Transmisibles Emergentes. Facultad de Veterinaria. Zaragoza. bmoreno@unizar.es*

**Introduction:** Tumors in goats are rarely reported and the coexistence of multiple tumors in the same animal even less often. This work describes the pathological characteristics of several primary tumors in a goat.

**Material and methods:** An aged goat which died with a history of depression and anorexia for two days was necropsied.

**Results:** In the liver, several whitish nodules, from 1 to 5 cm in diameter, were observed. Similar lesions, but of smaller size, were found in the peritoneal cavity and diaphragm. A round nodule with a pinkish cut surface, approximately 5 cm in diameter, was found in the cranial mediastinum. In the brain multifocal blood cavities, 1 to 3 mm in diameter, were detected in the meninges.

Microscopically, liver lesions corresponded with a cholangiocarcinoma. Peritoneal lesions were similar to those described in the liver but with more fibrosis. The mediastinal lesion corresponded with a thymoma, with ovoid to fusiform cells densely grouped mixed with well differentiated lymphoid cells. In the meninges, blood cavities lined by fine endothelial cells and hemangiomas characterized by irregular vascular channels lined by plump cells with certain atypia were observed.

**Discussion and Conclusion:** In goats, cholangiocarcinomas have been sporadically reported but no implants on the peritoneum have been described. Thymomas, as usually cited in goats, was an incidental finding. Vascular tumors are rarely mentioned and no hemangiomas in brain have been previously reported.

### **P43- PRECISION CUT LUNG SLICES TO STUDY THE PATHOGENESIS OF OVINE PULMONARY ADENOCARCINOMA**

*Alleaume Charline<sup>1,2</sup>, Dagleish Mark<sup>1</sup>, Cousens Chris<sup>1</sup>*

*1Moredu Research Institute, Edinburgh, Scotland, UK, 2Ecole Nationale Vétérinaire d'Alfort, Maisons-Alfort, France, char.all@hotmail.fr*

**Introduction:** Ovine pulmonary adenocarcinoma (OPA), induced by Jaagsiekte Sheep Retrovirus (JSRV), is a significant disease in sheep and a model for human lung cancer. The objective of this work was to validate a new in vitro model to study tumoural cell transformation using precision cut lung slices (PCLS).

**Materials and Methods:** PCLS were experimentally infected with JSRV and immunohistochemistry was performed 16 and 20 days post-infection. Natural and experimental OPA cases were used as positive control material. The immunohistochemical targets were the JSRV protein (SU), tumourigenesis signaling molecules (P-Akt, P-Erk1/2, P-PDK1, Hsp90), cell typing markers (SPC, DC LAMP, Cytokeratin) and a proliferation marker (Ki67).

**Results:** Immunolabelling of SU, P-Akt, Hsp90, SPC and DC LAMP was successful in OPA from in vivo material and in JSRV-infected cells in PCLS. P-Erk1/2 was observed only in OPA tissue. P-PDK1 was not detected in OPA tissue. Labelling of Ki67 was abundant in JRSV-infected PCLS but sparse in in vivo generated OPA tissues.

**Discussion & Conclusion:** The detection of viral protein by immunohistochemistry demonstrated infection and replication of the JRSV in PCLS. The detection of similar cell markers and signalling molecules of tumoural transformation, in both the JSRV-infected PCLS and in vivo generated OPA, supported the validation of the PCLS system as a new in vitro model suitable to study tumourigenesis of OPA.

#### **P44- PATHOLOGICAL AND AETIOLOGICAL STUDIES IN SHEEP EXHIBITING EXTRA-THORACIC METASTASIS OF OVINE PULMONARY ADENOCARCINOMA (JAAGSIEKTE)**

*Minguijón E<sup>1</sup>, González L<sup>2</sup>, De Las Heras M<sup>3</sup>, Gómez N<sup>1</sup>, García-Goti M<sup>4</sup>, Juste RA<sup>1</sup>, Moreno B<sup>3</sup>*

*INEIKER- Instituto Vasco de Investigación y Desarrollo Agrario, Derio, Spain, 2Animal Health and Veterinary Laboratories Agency, Penicuik, UK, 3Universidad de Zaragoza, Zaragoza, Spain and 4Eroski, Elorrio, Spain. lasher@unizar.es*

**Introduction:** Metastases to regional lymph nodes have been reported with frequencies varying up to 25% of Ovine pulmonary adenocarcinoma (OPA) cases but the occurrence of distant metastases has been scarcely reported and are considered rare (De Las Heras et al., 2003).

**Materials and methods:** Within the period 1984-2004 seven sheep submitted for post-mortem examination were diagnosed as cases of pulmonary adenocarcinoma with extra-thoracic metastasis and included in the study. Routine histopathology and immunohistochemistry with an antiserum raised against Jaagsiekte retrovirus (JSRV; kindly provided by Dr. Miller; U. of Washington) was performed. JSRV long terminal repeat-targeted polymerase chain reaction (PCR) was used to detect proviral sequences.

**Results:** Extra-thoracic metastases were found in the liver, kidneys, skeletal muscle, digestive tract, spleen, skin and adrenal glands. Thoracic metastases involved the chest wall, regional lymph nodes, diaphragm and heart. Immunohistochemistry and PCR allowed detection of JSRV-related protein and nucleic acid in the extra-thoracic tumours of all seven cases.

**Dicussion and conclusion:** It is concluded that such metastasis constitute a pathological event of ovine pulmonary adenocarcinoma and confirms the malignant character of this virus-induced neoplasia.

Funded by INIA (RTA02-003-C2), EU (QLK2-CT-2001-02380) and the Basque Government.

**P45- OCURRENCE OF PAPILLARY ADENOCARCINOMA OF ETHMOID OLFATORY MUCOSA IN SHEEP.**

*Tavasoly Abbas, Taghipour-bazargani Taghi, Kamyabi-moghaddam Zahra, Bagheri Farnoosh*

*Department of Pathology, faculty of Veterinary medicine, University of Tehran, Tehran, Iran.*

**Introduction:** Enzootic intranasal tumors of sheep occur widely throughout the world. The tumors of the nasal cavity and paranasal sinuses generally have a low incidence, being frequently reported in dogs. The morphological forms of these neoplasms in animals are similar to human forms. The tumors of the nasal cavity and paranasal sinuses are associated with chronic irritations produced by the polluted environment, and in incipient lesions and also retroviruses in sheep. This is the first Case report from Iran.

**Material and method:** The sheep with history of clinical signs such as asthma, dyspnea, was referred to the veterinary hospital of Tehran university. During the clinical examination, unilateral obstruction of the nasal cavity was highly remarkable. Unfortunately affected animal died during this examination.

**Results:** At necropsy, a tumor mass was found in nasal cavity (ethmoid). Grossly, this neoplasm was white to gray discoloration with rubbery to hard consistency and approximately 6 cm in diameter. Microscopically gross pattern of tumor was papillary type. Neoplastic epithelial cells had hyperchromatic nuclei with severe invasion to stroma which destruction of ethmoidal bone. Mitotic figure were low and no evidence of metastasis in other organ.

**Discussion:** There is ample evidence that type D-like retroviruses are implicated in causing the tumors in both sheep and goats. Endemic ethmoid tumors also observed in cattle, horse and pig.



**P46- SPONTANEOUS TUMOURS OBSERVED IN CYNOMOLGUS MONKEYS (MACACA FASCICULARIS) DURING A 20-YEAR PERIOD (1992-2012)**

*J.Kaspareit, S.Friderichs-Gromoll, E.Buse, G. Habermann*

*Covance Laboratories, Germany, Joachim.kaspareit@covance.com*

**Introduction:** A lot of information is available in the literature about the tumours of commonly used laboratory animal species (rat, mouse and hamster). In contrast there are only few reports available about tumours of laboratory primate species. Up to the end of 2011 only about 40 neoplasms in cynomolgus monkeys were published.

**Material and methods:** Animals were from different toxicity studies (control and dosed animals) conducted between 1992 and 2012. They were purchased from breeders in China and Mauritius or from our own colony. A complete necropsy was performed on all animals. Organ samples were fixed in 10% buffered formalin, embedded in paraffin wax, sectioned at a nominal thickness of 5 mm and stained with H.E.

**Results:** Tumours were observed in 62 animals (which accounts for less than 1 % of all necropsies). The great majority of tumours observed was benign (48 benign vs 14 malignant tumours) with 22 found in males and 40 in females. Most of the tumours (36) of the cynomolgus monkeys were seen in only three organ systems (endocrine, respiratory and female genital). The histopathological and immunohistochemical features of the neoplasms will be described.

**Discussion & Conclusion:** With the present report we extend the current knowledge about the tumour spectrum of cynomolgus monkeys by describing the tumour incidences and types observed in our colony during the past 20 years.

**P47- ROLE OF LKB1 AND BRAF IN UV INDUCED MELANOMAS IN MICE**

*Suarez C, Martin-Caballero J, Recio JA and Flores JM*

*IDepartamento de Medicina y Cirugía Animal. Facultad de Veterinaria. Universidad Complutense. Madrid. España. jflores@vet.ucm.es*

**Introduction:** Mutationally activated BRAF is observed in 70% of human melanoma and the role of LKB1 in melanoma is supported by the existence of naturally occurring mutants identified in human samples. Moreover, preliminary data indicates that LKB1 haploinsufficiency sensitizes to UVB induced skin cancer.

**Material and Methods:** To study the role of BRAF and LKB1 in melanoma development and its role in UV irradiation, we have generated a animal model crossing Tyr::CreERT2 mice with the Lkb1lox/lox and then the resulting mouse will be crossed with BRafCA/CA, and the different genotypes of mice were analyzed. With 4-OH-tamoxifen (OHT) will induce the expression of the CRE recombinase and the Lkb1 gene will be excised. Tumor development will be evaluated after UV irradiation. Samples were routinely processed after necropsy. Immunohistochemistry was performed using: anti-Tyrosinase, anti-Cre, and anti-S100 antibodies.

**Results y conclusion:** Higher skin tumors incidence was observed in OHT+UVB-treated Tyr::CreERT2; BRafCA/CA; Lkb1flox/flox with differences between the genotypes of mice. Most of the tumors developed were pigmented skin tumors Mixoid melanoma and spindle-cell melanoma were the histological types more frequently observed and confirmed by anti-tyrosinase and S-100 immunostaining. These results pointed that the presence of LKB1 seems to be important to trigger the oncogenic role of BRAF in development of skin melanomas.

**P48- COOPERATION BETWEEN P21 CIP<sup>o</sup>/WAF1 AND P27 KIP2 IN CELLULAR SENEESCENCE IN TUMORS.**

*García-Fernández RA, García-Palencia P, Suárez C, Sánchez MA, Sánchez B<sup>1</sup>, Martín-Caballero J y Flores JM*

*1Departamento de Medicina y Cirugía Animal. Facultad de Veterinaria. UCM. Madrid.*

**Introduction:** This work was focused in analyze the potential involvement of *cdkn1a* and *cdkn1b* loci, which encode for the tumor suppressor proteins p21 y p27 respectively, in the cellular senescence of spontaneous tumors and hyperplasias generated in a double KO model.

**Material and Methods:** Samples of hyperplasias and tumors (benign and malignant), were analyzed in p21-null mice, p27-null mice, p21/p27 double knockout mice and wild type mice in a genetic background BL/6. We assessed the immunoexpression of H2A.X), Ki67 and p53.γphospho histone H2A.X)

**Results and Conclusion:** When H2A.X, hyperplasias and bening tumors inγassessed cellular senescence using double deficient mice showed significant differences when compared with the rest H2A.X were obtained in malignantlyof the groups. The lowest values of neoplasias, with no differences among groups. To validate the results obtained in tumor senescence we analyzed the cellular proliferation using Ki67. In all studied groups, a positive correlation was shown between the low proliferative index obtained in hyperplasias and benign neoplasias, and the high levels observed in malignant tumors. p53 immunoexpression demonstrates no differences among pre-tumoral lesions and neoplasias. These results point out the contribution of p21 and p27 to the establishment of cellular senescence and the subsequent reduction of the malignant transformation.

**P49- B CATHENIN IN MICE: EXPRESSION IN NORMAL UROTHELIUM AND IN CHEMICALLY INDUCED PRE-NEOPLASTIC AND NEOPLASTIC LESIONS.**

*Vasconcelos-Nóbrega C<sup>1</sup>, Costa C<sup>2</sup>, Vala H<sup>1,3</sup>, Colaço A<sup>4</sup>, Santos L<sup>2,5</sup>, Lopes C<sup>6</sup>, Oliveira PA<sup>4</sup>*

*1- ESAV, IPV, Viseu; 2-Health Faculty, UFP, Porto; 3 – CI&DETS. IPV, Viseu; 4 – CECAV, UTAD, Vila Real; 5 – IPO, Porto; 6 – ICBAS-UP, Pathology and Molecular Immunology, Porto. Portugal. cnobrega@esav.ipv.pt*

**Introduction:** Catenins are adhesion molecules that link cadherin molecules to cytoskeleton. The association of catenins to cadherins is a key step in the function of intact adhesion complexes, and alterations in catenin molecules can lead to the disruption of cell-cell adhesion, resulting in tumour aggressiveness and invasiveness in neoplastic disease.

**Material and methods:** Urothelial lesions were chemically induced by BBN in ICR mice, and evaluated by immunohistochemistry to determine the staining pattern of  $\beta$ -catenin.

**Results:** In normal urothelium, 70% of  $\beta$ -catenin expression was at the cellular membrane level. In simple hyperplasia, the same pattern was observed in 66.67% of lesions. Nodular hyperplasia was observed only once with a membrane pattern. In dysplasia a 100% cytoplasmic pattern was seen. Invasive carcinoma showed an heterogeneous pattern with areas where the membrane, cytoplasm or nucleus were stained. On squamous metaplasia, the staining pattern was confined to the membrane, however, with heterogeneous immunoreactivity.

**Conclusions:**  $\beta$ -catenin is a good marker of the progression of bladder tumours chemically induced in mice by BBN.

**P50- HEPATOCELLULAR ADENOCARCINOMA IN A RACING PIGEON – CASE REPORT**

*Szweda M, Babińska I, Paździor K<sup>1</sup>, Gesek M<sup>1</sup>*

*Department of Pathophysiology, Forensic Veterinary Medicine and Administration,  
1Faculty of Veterinary Medicine, University of Warmia and Mazury, Olsztyn, Poland,  
magdalena.szweda@uwm.edu.pl*

**Introduction:** Hepatocellular carcinoma is a malicious primary epithelial hepatic tumour, originating from hepatocytes. Histologically, it usually has a trabecular structure and a high mitotic rate; individual cells can be well or poorly differentiated.

**Material and Methods:** Macroscopic examination was performed of a male racing pigeon at the age of 8-month-old, which died after showing symptoms of no appetite and considerably weakness. An autopsy revealed ascites and an enlarged liver with light foci and tumours. Specimens of the changed liver were taken for microscopic examination (HE, PAS).

**Results:** Microscopic examination revealed the presence of infiltrative neoplastic tissue originating from hepatic cells. The parenchyma of the tumour had a lobular-trabecular structure. Extensive necrotic foci were observed. The results of microscopic examinations of the pigeon's liver enabled the diagnosis of moderately differentiated hepatocellular adenocarcinoma.

**Discussion & Conclusion:** No description of hepatocellular adenocarcinoma in a racing pigeon has been found in the available literature. The cause of this spontaneous primary liver cancer in birds is unknown.

## **P51- SUSCEPTIBILITY TO SCRAPIE AND DISEASE PHENOTYPE IN SHEEP: CROSS-Prnp GENOTYPE TRANSMISSIONS WITH NATURAL SOURCES**

*González L<sup>1</sup>, Jeffrey M<sup>1</sup>, Dagleish MP<sup>2</sup>, Chianini F<sup>2</sup>*

*1Animal Health and Veterinary Laboratories Agency, Edinburgh, UK 2Moredun Research Institute, Edinburgh, UK lorenzo.gonzalez@ahvla.gsi.gov.uk*

**Introduction:** The sheep Prnp genotype influences the susceptibility to scrapie. While some studies suggest that it can also determine aspects of the disease phenotype, others indicate that the infecting strain also plays a role.

**Materials and Methods:** Either of two different natural scrapie sources, AAS from AA136 Suffolk and VVC from VV136 Cheviot sheep, were inoculated into AA136, VA136 and VV136 sheep recipients (n=52), which were killed once they reached clinical end point. Brain samples were examined by immunohistochemistry (IHC) and Western blotting (WB).

**Results:** The IHC profile of disease-associated PrP (PrPd) accumulation in the brain of recipient sheep was highly consistent upon codon 136 homologous and semi-homologous transmission and highly variable upon heterologous transmission (VVC to AA136 and AAS to VV136). Sheep of the same Prnp genotype could exhibit different survival times and PrPd profiles depending on the source of infection. A correlation was observed between IHC and WB profiles. Additional polymorphisms at codons 112 or 141 of AA136 recipients resulted in a delayed appearance of disease or even in protection from infection.

**Discussion & Conclusion:** The scrapie phenotype in sheep results from a complex interaction between source, donor and recipient factors, and the Prnp genotype does not explain the variability observed upon heterologous transmissions, arguing for other genetic factors to be involved.

**P52- THE PATHOGENESIS AND DISEASE PHENOTYPE OF SCRAPIE IS NOT AFFECTED BY THE DOSE OR ROUTE OF INOCULATION**

*Pitarch JL<sup>1</sup>, Jeffrey M<sup>2</sup>, Thurson L<sup>2</sup>, Martin S<sup>2</sup>, Acín C<sup>1</sup>, González L<sup>2</sup>*

*1University of Zaragoza, Spain 2Animal Health and Veterinary Laboratories Agency, Edinburgh, UK lorenzo.gonzalez@ahvla.gsi.gov.uk*

**Introduction:** The pathogenesis of scrapie, including the route of neuroinvasion, might be dependant on the route of infection and survival time on the infectious dose.

**Materials and Methods:** Cheviot sheep of the VRQ/VRQ Prnp genotype were inoculated with a scrapie brain pool by the oral (1g, n=55; 5g, n=48) or the conjunctival (1g, n=35) route. Groups of sheep were killed sequentially during the preclinical period and 57 animals were left to develop clinical disease. Lymphoreticular system (LRS) tissues and central nervous system (CNS) samples were examined by immunohistochemistry with R145 prion protein (PrP) antibody.

**Results:** Disease-associated PrP (PrPd) started to accumulate at 28 days post-infection (dpi; oral) or 86 dpi (conjunctival). Initial PrPd accumulation always involved the Peyer's patches and LRS tissues of the head. Regardless of route or dose, first PrPd deposits in the CNS appeared at 111 dpi, always in the same neuroanatomical areas. Clinical signs were evident by ~175 (oral) or ~200 (conjunctival) dpi. At this stage, the phenotype of PrPd accumulation in the CNS was identical in all sheep.

**Discussion & Conclusion:** VRQ/VRQ sheep dosed with scrapie showed consistent pathogenetical and disease phenotype features regardless of dose and route of inoculation, suggesting early recirculation of the infectious agent and common pathways of neuroinvasion.

**P53- DETECTION OF PrPSc IN SKIN OF NATURAL SCRAPIE INFECTED SHEEP.**

*Garza MC, Acín C., Monzón M., Bolea R., Badiola J.J., Monleón, E.*

*Centro de Investigación en Encefalopatías y Enfermedades Transmisibles Emergentes. University of Zaragoza. Spain. mcgarza@unizar.es*

**Introduction:** The transmissible spongiform encephalopathies (TSEs) are a group of fatal neurodegenerative diseases whose hallmark is the pathological prion protein (PrPSc) deposition in the central nervous system. In recent years, there have been reported descriptions of PrPSc in different organs, suggesting that distribution of this protein in the organism of individuals suffering a TSE may be much larger than considered so far. The aim of this study is determine the dissemination of PrPSc in skin of natural scrapie infected sheep.

**Materials and Methods:** Samples of skin from 16 scrapie infected sheep in clinical phase and 4 negative scrapie animals were collected and analyzed for PrPSc detection by immunohistochemistry (IHC) and ELISA.

**Results:** Four animals were positives by IHQ, one by ELISA and one by both techniques. All of the IHQ positive showed PrPSc deposits associated with the peripheral nervous system. In the unique animal positive by both techniques, a new pattern of immunostaining was observed. In this case, PrPSc was detected at the epidermis, reaching until granular layer.

**Discussion & Conclusion:** The implication of skin in the pathogenesis of scrapie seems to be higher than has been considered up to now and may play a role in the spread of contagious scrapie in the field. PrPSc location at epidermis could be a via of excretion through the normal regeneration process.



**P54- EXPERIMENTAL SHEEP-BOVINE SPONGIFORM ENCEPHALOPATHY IN PIGS**

*Hedman Carlos<sup>1</sup>, Marín Belén<sup>1</sup>, Corbière Fabien<sup>4</sup>, Filali Hicham<sup>1</sup>, Márquez Merce<sup>3</sup>, Vidal Enric<sup>3</sup>, Vázquez Francisco<sup>2</sup>, Romero Antonio<sup>2</sup>, Pitarch José L.<sup>1</sup>, Garza Ma Carmen<sup>1</sup>, Sarasa Rocío<sup>1</sup>, Jirón William<sup>1</sup>, Hernandez Rodrigo<sup>1</sup>, Acín Cristina<sup>1</sup>, Monzón Marta<sup>1</sup>, Pumarola Martí<sup>3</sup>, Badiola Juan J<sup>1</sup>, Andreoletti Olivier<sup>4</sup>, Bolea Rosa<sup>1</sup>*

*1Centro de Investigación en Encefalopatías Espongiformes Transmisibles Emergentes. Facultad de Veterinaria. Universidad de Zaragoza, Zaragoza, Spain. 2Hospital Veterinario. Universidad de Zaragoza, Zaragoza Spain. 3PRIOCAT Laboratory UAB-IRTA, Campus de la Universitat Autònoma de Barcelona, Barcelona, Spain. 4Institut National de la Recherche Agronomique Toulouse, France. . rbolea@unizar.es*

**Introduction:** The importance to study the susceptibility of swine to transmissible spongiform encephalopathies (TSE) grows when in the European Union raises the possibility of lifting the ban on feeding pigs and poultry with animal meal.

**Material and Methods:** 7 pigs were inoculated intracerebrally using 0.5 ml of inoculum from an experimental BSE in sheep brain. Animals were under clinical observation. Western blot, histopathology and immunohistochemistry were performed to confirm the presence of the TSE agent.

**Results:** 21 months later, a challenged pig showed clinical signs compatible with the disease. Vacuolar changes were observed and several pattern of immunopositivity were identified in different regions of the brain.

**Discussion:** The preliminary results confirms that the experimental susceptibility of pigs to BSE and the pathogenicity of the BSE agent could be enhanced after its passage in sheep, as previously demonstrated in a mice model.

**P54 bis- A POSSIBLE ROLE OF P-GLYCOPROTEIN IN BSE**

*Van der Heyden Sara<sup>1</sup>, Wegge Beatrice<sup>2</sup>, Dobby Alexandre<sup>1</sup>, Ducatelle Richard<sup>2</sup>, Roels Stefan<sup>1</sup>*

*1. The Veterinary and Agrochemical Research Centre (CODA-CERVA), Brussels, Belgium 2. Department of Pathology, Bacteriology and Avian Diseases, Faculty of Veterinary Medicine, Ghent University, Belgium. Presenting author: Stefan.Roels@coda-cerva.be*

**Introduction:** P-glycoprotein (P-gp) is a key-player in the blood-brain barrier. One of its major roles is acting as an efflux pump for endogenous and exogenous substrates to protect the brain. P-gp reduction may diminish this protective barrier and lead to increased exposure to possible toxic compounds. Bovine spongiform encephalopathy (BSE) is a fatal neurodegenerative disease of cattle known as 'mad cow disease'. So far the susceptibility to this prion disease is not determined. As hypothesized in human Creutzfeldt-Jakob disease (CJD), decrease of cerebrovascular P-gp may be involved in the pathogenesis of BSE in cattle.

**Materials and Methods:** Immunohistochemistry was performed using antibody C219 on formalin fixed samples of the obex of 10 BSE negative animals (BSE-) and 10 BSE positive animals with clear histopathological lesions (BSE+). Quantification of P-gp positivity was performed on 5 randomly chosen localizations in each obex with an automatic image analyzing system (LAS V3.8, Leica Microsystems) measuring the area percentage of tissue occupied by the labeled cells.

**Results:** P-gp positive area was significantly higher in BSE+ animals compared to BSE- animals ( $p < 0.05$ ).

**Conclusion:** In contrast to CJD in humans, there seems to be higher P-gp expression in BSE+ animals. The reason for this is unclear. Further investigation is necessary.

## **P55- VISNA/MAEDI: AN EXPERIMENTAL STUDY ON THE DISTRIBUTION OF TWO VIRAL STRAINS WITH MARKED TISSUE TROPISM USING THE BONE MARROW ROUTE**

*Pinczowski P<sup>1</sup>, San José L<sup>2</sup>, Gimeno M<sup>1</sup>, Pérez M<sup>1</sup>, Insausti N<sup>1</sup>, de Andrés D<sup>2</sup>, Badiola JJ<sup>1</sup>, Amorena B<sup>2</sup>, Reina R<sup>2</sup>, Luján L<sup>1</sup>*

*1University of Zaragoza & 2Agrobiotechnology Institute (CSIC/UPNA) Navarra, Spain, Lluís.Lujan@unizar.es*

**Introduction:** Small ruminant lentiviruses (SRLV) infection causes lesions in target organs such as lungs, CNS, joints and mammary gland. Two ovine strains have been previously isolated from field cases in outbreaks where the neurological and articular presentations were the most relevant clinical forms. The objective of this work was to study the tropism of these strains in an experimental infection.

**Material and Methods:** Fifteen lambs, negative by ELISA and PCR for Visna/maedi, were distributed into two infected groups and one control group. Lambs were inoculated in the humeral bone marrow with 106TCID<sub>50</sub> of the neurological or the articular strain and reinfected 60 days later. Blood was tested weekly by SRLV ELISA and PCR-sequencing. Animals were killed at 134, 273 and 319 dpi and tissue samples studied.

**Results and Discussion:** Serology demonstrated infection in all animals with the exception of controls and one inoculated. The specific viral strain was observed circulating in blood from the corresponding group. Although SRLV strains used demonstrated a clear tropism for specific tissues, the presence of viral genome in target organs demonstrated that factors other to those attributed to the viral strain could have affected the tissue distribution. Determinants leading to specific tissue tropism remain unknown in most lentiviral infections.

**P56- MEDULLAR VISNA BY 697 STRAIN IN SHEEP: WIDER DISTRIBUTION THAN PREVIOUSLY THOUGHT**

*Pinczowski P<sup>1</sup>, Gimeno M<sup>1</sup>, Pérez M<sup>1</sup>, Insausti N<sup>1</sup>, Moreno B<sup>1</sup>, San José L<sup>2</sup>, Badiola JJ<sup>1</sup>, de Andrés D<sup>2</sup>, Amorena B<sup>2</sup>, Reina R<sup>2</sup>, Luján L<sup>1</sup>*

*1University of Zaragoza & 2Agrobiotechnology Institute (UPNA/CSIC) Mutilva, Navarra, Spain, Lluís.Lujan@unizar.es*

**Introduction:** Visna/maedi (VM) is a small ruminant lentivirus (SRLV) that produces lesions in target organ/tissues in sheep, such as the nervous system. In 2006 a new form of the disease affecting the spinal cord, caused by strain 697, was described in León, Spain. This work reports this neurological presentation associated to the same strain in another geographical area, distant from the original outbreak.

**Material and methods:** A SRLV/VM seropositive Rasa Aragonesa sheep showing severe posterior ataxia was studied by pathological and virological procedures.

**Results:** The thoracic spinal cord showed light-brown discoloured areas at the right ventral horn. Microscopically, the medulla showed focal extensive necrosis of the white and grey matter, intense gitter cell infiltrate and severe mononuclear cuffings. The ependyma was occluded by amorphous eosinophilic material. The leptomeninges showed marked lymphoplasmocytic infiltrate. The brain showed no significant lesions. Additionally, lesions compatible with VM were observed in lung. DNA from blood and spinal cord was amplified by PCR and sequenced, revealing the presence of a 697-related strain.

**Discussion and Conclusion:** The medullar form of VM is infrequent and, to date, it has only been described in León. These results demonstrate that this form is also found in other distant geographic locations and is caused by a neurological 697-like SRLV strain.

## **P57- EQUINE MULTINODULAR PULMONARY FIBROSIS: THE ROLE OF EHV-5 IN THE PATHOGENESIS OF AN EMERGING DISEASE**

*Leeming Gail, Kipar Anja, Hartley Catherine, Malbon Alexandra, Hetzel Udo, Stewart James P*

*University of Liverpool, Liverpool, UK. gail.leeming@liverpool.ac.uk*

**Introduction:** Equine Multinodular Pulmonary Fibrosis (EMPF) is a relatively recently described condition characterised by loss of functional pulmonary parenchyma due to extensive nodular to coalescing interstitial fibrosis. A strong association with Equine herpesvirus 5 (EHV-5) has been established; however the pathogenesis of the condition remains unclear.

**Materials and Methods:** A retrospective study of formalin-fixed, paraffin-embedded tissues from cases of EMPF from Europe and the USA was performed. The presence of EHV-5 DNA within lesions was demonstrated using RNA-in situ hybridisation, and immunohistology and electron microscopy were used to characterise the infected cells.

**Results:** Cases of EMPF were characterised histologically by multifocal to coalescing interstitial pulmonary fibrosis, with remaining alveoli lined by cuboidal epithelium (type II pneumocyte hyperplasia) and filled with inflammatory cells. EHV-5 antigen was identified within both type II pneumocytes and macrophages.

**Discussion:** EHV-5 (a gammaherpesvirus;  $\gamma$ HV) has been isolated from both healthy horses and those with respiratory signs, at highly variable rates.  $\gamma$ HV in other species have an association with pulmonary fibrosis and repeated injury of type II pneumocytes and macrophages leads to production of TGF- $\beta$ , which induces fibrosis (e.g. Epstein-Barr virus in human Idiopathic Pulmonary Fibrosis). Investigation of the role of TGF- $\beta$  in EMPF is ongoing to further characterise the pathogenesis of EHV-5 in this emerging disease.

## **P58- EQUINE HERPESVIRUS INFECTION IN A FOAL WITH BRONCHOINTERSTITIAL PNEUMONIA**

*Perez-Ecija Alejandro, Mendoza Francisco, Estepa José, Zafra Rafael, Bautista M<sup>a</sup> Jose, Perez José.*

*Veterinary Faculty. University of Cordoba, Córdoba. Spain.v02peecr@uco.es.*

**Introduction:** Bronchointerstitial pneumonia (BP) in foals is a rare disease with a controversial etiology. Traditionally, a viral agent has been suspected but the usual concurrent bacterial infections made difficult to elucidate its identity.

**Materials and Methods:** A 2-months old foal, Andalusian breed with a 2 days evolution history of profound dyspnea, tachypnea, tachycardia, increased capillary refill time and fever (39.1°C) was found dead by the owner and remitted for a pathologic study.

**Results:** At necropsy both lungs appear diffusely oedematous and reddish, non-collapsing and consolidated. In cranioventral areas a pyogranulomatous bronchopneumonia typical of *Rhodococcus* infection was recorded. In the surrounding parenchyma to these nodules and diffusely in the right lung, the most striking finding was the presence of a diffuse interstitial infiltrate of foamy macrophages and syncytial cells accompanied by bronchiolar and alveolar epithelium necrosis. Numerous foamy macrophages and syncytial cells presented large acidophilic intranuclear inclusion bodies. An immunohistochemical study using a caprine anti-Equid Herpesvirus 1 (EHV-1) polyclonal antibody resulted in strong immunostaining of those inclusion bodies.

**Discussion & Conclusion:** To the knowledge of the authors, this is the first description of EHV inclusion bodies in syncytial cells of a foal with bronchointerstitial pneumonia, reinforcing the role of this virus as a causative pathogen for this disease.

## **P59- INTERSTITIAL PNEUMONIA IN HORSES INFECTED WITH EQUINE INFECTIOUS ANEMIA VIRUS**

*Bolfa P<sup>1</sup>, Cadore JL<sup>2</sup>, Nolf M<sup>2</sup>, Catoi C<sup>1</sup>, Vidrighinescu R<sup>1</sup>, Taulescu M<sup>1</sup>, Nagy A<sup>1</sup>, Tabaran F<sup>1</sup>, Farcas L<sup>1</sup>, Leroux C<sup>3</sup>*

*1Pathology Department, University of Agricultural Sciences and Veterinary Medicine, Cluj-Napoca, Romania, 2VetAgro Sup, Lyon, France, 3UMR 754 “Rétrovirus et pathologie comparée”, Université Lyon 1, France. email:pompeibolfa@gmail.com*

**Introduction:** Interstitial lung pathology has been described in human and animal lentiviral diseases, such as HIV-1 infected human beings, feline immunodeficiency virus (FIV) infected cats, and Ovine progressive pneumonia/Maedi-Visna virus infected sheep. Our hypothesis was to check if besides already described alveolar thickening and hypercellularity there is a lung pathology in equine infectious anemia virus (EIAV) infected animals.

**Materials and Methods:** For our study, we used lung tissues from 80 EIAV serologically positive animals and 10 EIAV serologically negative equids (control group). Classical hematoxylin and eosin stain was performed on paraffin embedded tissues, followed by immunohistochemistry for AntiEIAV core protein – p26 monoclonal and  $\alpha$  smooth muscle actin ( $\alpha$ SMA).

**Results:** Our preliminary results show that 48 horses (60%) had different degrees of interstitial pneumonia (focally to diffuse). This was associated with the presence of the virus in most of the cases. In 6 cases there was a bronchiolocentric nature of the chronic inflammatory cell infiltrate.

**Discussion & Conclusion:** To our knowledge this is the first report of interstitial pneumonia in EIAV infected horses. Our results warrant further investigation regarding the association of EIAV to this type of interstitial lung pathology.

## **P60- BORNA DISEASE VIRUS INFECTION OF TNF-TRANSGENIC NEURONAL CULTURES PROMOTES ASTROGLIAL PROLIFERATION**

*Melo GD<sup>1</sup>, Brachthäuser L<sup>2</sup>, Ahlemeyer B<sup>3</sup>, Baumgart-Vogt B<sup>3</sup>, Herden C<sup>2</sup>*

*<sup>1</sup>College of Veterinary Medicine, UNESP – Univ Estadual Paulista, Araçatuba-SP, Brazil. <sup>2</sup>Institute of Veterinary Pathology and <sup>3</sup>Institute for Anatomy and Cell Biology -Division of Medical Cell Biology, Justus-Liebig-University Giessen, Giessen, Germany. [christiane.herden@vetmed.uni-giessen.de](mailto:christiane.herden@vetmed.uni-giessen.de)*

**Introduction:** Borna disease virus (BDV) is a neurotropic pathogen that causes a progressive non-suppurative meningoencephalitis and can trigger epileptic seizures in combination with neuronal TNF overexpression. Neuronal culture from TNF-transgenic mice can serve to elucidate the underlying neuropathological principles, but the kinetic of cell populations after BDV-infection must be evaluated first.

**Materials and Methods:** Neuronal cultures were prepared from cerebral cortex of TNF-transgenic newborn-mice and cultivated in Neurobasal Medium/B27. At the second day in vitro the cultures were infected with a mouse-adapted BDV-strain and immunofluorescence evaluation of neurons (MAP-2), astrocytes (GFAP) and oligodendrocytes (CNPase) was performed at four and seven days-post-infection (dpi).

**Results:** The cell population remained stable in the control cultures, with neurons around 90% and astrocytes 10%. In the BDV-infected cultures, the cell population changed remarkably, with significant astrocyte increase (47,1% at 4dpi; 57,6% at 7dpi) along with neuronal decrease (52,9% at 4dpi; 40,4% at 7dpi). Oligodendrocytes were below 1%. Notable neuronal cell death was not evident.

**Discussion and Conclusion:** BDV infection promotes astroglial proliferation under neuronal culture conditions, therefore increasing the need to understand not only neuronal but also astrocytic reaction patterns in case of virus infections that are able to cause epileptic seizures.



## **P61- DIFFERENTIAL EXPRESIÓN OF CITOKINES IN OVINE LUNG IN RESPONSE TO EXPERIMENTAL BOVINE RESPIRATORY SYNCYTIAL VIRUS**

*García A, Masot J, Gázquez A, Redondo E.*

*University of Extremadura, Caceres, Spain, angela@unex.es*

**Introduction:** The immunohistochemical expression and the lung extract concentrations of Interleukin-1 Beta (IL-1 $\beta$ ), Tumor Necrosis Factor Alpha (TNF $\alpha$ ) and Interleukin-8 (IL-8) in the lung of lambs experimentally infected with BRSV were investigated.

**Materials and Methods:** The lambs were randomly assigned to 2 groups: infected and uninfected controls. The inoculum in each lambs of the infected group was 20 ml saline solution containing  $1.5 \times 10^6$  TCID<sub>50</sub> Bovine Respiratory Syncytial Virus (BRSV, strain NMK-7) per mL. The control lambs were inoculated with 20 mL of sterile saline solution. The control and infected animals were slaughtered at 1, 3, 5, 7 and 15 days post-infection (dpi).

**Results:** These findings demonstrate a temporal association between pulmonary and IL-8 cytokines and lung pathology in lambs $\alpha$ expression of IL-1 $\beta$ , TNF- experimentally infected with BRSV.

**Discussion & Conclusion:** and IL-8 inflammatory $\alpha$ The results of this study suggest that IL-1 $\beta$ , TNF- cytokines may play an important role in enhancing the biological response of BRSV and contribute to the development of the pro-inflammatory response in the ovine lung. Given that the expression of IL-8 in the lung of lambs was much greater than that of TNF $\alpha$  and IL-1 $\beta$ , the anti-cytokine agents directed at this mediator could be more useful in the prevention and treatment of Bovine Respiratory Syncytial Virus infection.

## **P62- SPONTANEOUS NECROTIZING BRONCHOPNEUMONIA IN THREE YOUNG PIGS POSSIBLY CAUSED BY A(H1N1)pdm09**

*Kinji Shirota, Akiko Sakuma, Azabu*

*University, Japan, shirota@azabu-u.ac.jp*

**Introduction:** The experimental studies have shown that the A(H1N1)pdm09 induces pulmonary lesions in several animals including pigs. However, spontaneous animal cases have been rarely described. The objective of this work is to describe histopathological and immunohistochemical findings of the lungs from young pigs possibly infected with the A(H1N1)pdm09.

**Materials and Methods:** By retrospective study, we found three young pigs suspected to be infected with the A(H1N1)pdm09. In these cases, the A(H1N1)pdm09-specific hemagglutinin sequence was detected by a kit using total RNA extracted from paraffin-embedded lung tissues. Two cases (Cases 1 and 3) were euthanized and another one (Case 2) was found dead in pig farms. The paraffin sections of systemic organs of these pigs were examined.

**Results:** Histopathological features were characterized by necrosis of bronchial and bronchiolar epithelium, frequently associating with regeneration, hyperplasia or squamous metaplasia. The lumens of the air spaces were filled with macrophages, neutrophils and cellular debris. Influenza type-A antigen was detected in the nuclei of bronchial and bronchiolar epithelial cells, and in cellular debris in the air spaces. Alveolar septa were expanded by cellular infiltration and edema. In Case 2, hyaline membrane and loss of alveolar epithelium were evidenced.

**Discussion and Conclusion:** Pulmonary lesions of the pigs were similar to those in experimental infection of A(H1N1)pdm09 in pigs. Case 2 showed diffuse alveolar damage, which was consistent with those in lethal cases of humans.

### **P63- DIFFERENTIAL EXPRESSION OF CLEAVED CASPASE-3 AND TUNEL IN LUNG AND LYMPHOID ORGANS OF PRRSV INFECTED PIGS**

*Barranco I<sup>1</sup>, Gómez-Laguna J<sup>2</sup>, Rodríguez-Gómez IM<sup>1</sup>, Pallarés FJ<sup>3</sup>, Ramis G<sup>3</sup>, García-Nicolás O<sup>3</sup>, Salguero FJ<sup>4</sup>, Carrasco L<sup>1</sup>.*

*University of Córdoba, Spain. v92bacam@uco.es*

**Introduction:** Porcine Reproductive and Respiratory Syndrome (PRRS) is characterized by an impaired host immune response, which may be linked to apoptosis phenomena.. The aim of this study was to evaluate the apoptosis phenomena and to correlate them with PRRSV, caspase 3 (CCasp3), TUNEL and cytokines immunolabelling in lung and lymphoid organs of PRRSV-infected pigs

**Materials and methods:** Twenty eight, PRRSV-negative pigs were inoculated with PRRSV field isolate 2982 and killed sequentially in groups of four animals from 3 to 24 days post-inoculation (dpi). Control animals were mock-inoculated and killed at 24 dpi. Tissue samples were collected at the necropsy and fixed in 10% buffered formalin for the histopathological and immunolabelling studies

**Results:** The expression of CCasp3 and TUNEL was observed earlier in the lung than in lymphoid organs coinciding with a higher expression of pro-apoptotic cytokines (IL-1 and TNF- $\alpha$ ) and viral replication and a lower expression of anti-apoptotic cytokines (IL-6) in the lung. In addition, CCasp3 and TUNEL immunolabelling was mainly observed in macrophages in the lung, but both in lymphocytes and macrophages in lymphoid organs.

**Discussion:** These results suggest a different induction of apoptotic phenomena by PRRSV, which may be related with the differential expression of proinflammatory cytokines and viral replication kinetics in each organ.

Financial support by project number AGL2009-12438/GAN.

## **P64- IL-10 TRANSCRIPTIONAL AND PROTEIN EXPRESSION IN LUNGS OF PORCINE REPRODUCTIVE AND RESPIRATORY SYNDROME VIRUS (PRRSV) INFECTED PIGS.**

*García-Nicolás O<sup>1</sup>, Quereda JJ<sup>2</sup>, Gómez-Laguna J<sup>3</sup> Barranco I<sup>4</sup>, Ramis G<sup>1</sup>, Pallarés FJ<sup>1</sup>, Carrasco L<sup>4</sup>.*

*1Universidad de Murcia, Spain; 2CSIC, Madrid, Spain; 3CICAP, Pozo Blanco, Spain; 4Universidad de Córdoba, Spain, ognvet@hotmail.com*

**Introduction:** PRRSV causes interstitial pneumonia in growing pigs and reproductive failure in gilts. The aim of this work was to determine the IL-10 gene and protein expression in lungs of PRRSV infected pigs.

**Material & Methods:** Thirty-two PRRSV-free pigs (5 weeks old) were selected and randomly located in batches of four animals. Seven groups were inoculated with European PRRSV field strain, and these groups were euthanized at different days post infection (dpi). A non PRRSV inoculated group was utilized as control. Samples from medial lung lobe were taken to measure the IL-10 gene and protein expression as previously described. Kruskal-Wallis and U of Mann-Whitney test were used.

**Results:** PRRSV antigens were only detected in infected pigs with maximum expression at 7 dpi. The IL-10 gene expression was upregulated ( $p < 0.05$ ) at 10 and 21 dpi. The IL-10 protein expression was detected in areas of interstitial pneumonia mainly in the cytoplasm of septal macrophages ( $p < 0.05$ ) with a peak at 7 dpi and decreased thereafter.

**Discussion:** These results indicate that the IL-10 expression could be a PRRSV strategy to avoid an effective innate immune response in infected pigs. Future deep studies should be done focused to clarify the IL-10 post-transcriptional mechanism.

**P65- TYPE 2 PRRSV INFECTION MEDIATED APOPTOSIS IN B- AND T-CELL AREAS IN LYMPHOID ORGANS**

*Gómez-Laguna J<sup>1</sup>, Salguero FJ<sup>2</sup>, Fernández de Marco M<sup>3</sup>, Barranco I<sup>3</sup>, Rodríguez-Gómez IM<sup>3</sup>, Quereda JJ<sup>4</sup>, Quezada M<sup>5</sup>, Carrasco L<sup>3</sup>.*

*CICAP, Pozoblanco, Córdoba, Spain, jgomez@cicap.es*

**Introduction:** Porcine Reproductive and Respiratory Syndrome Virus (PRRSV) infection is characterised by persisting in lungs and lymphoid tissue, resulting in systemic lymphoid depletion. In this study we correlate the histological changes, viral antigen expression and apoptosis phenomena in lymphoid organs of pigs inoculated with a type 2 PRRSV isolate.

**Materials and Methods:** Nine 3-week-old pigs were randomly assigned to groups of three, inoculated with the PRRSV Chilean strain 2402 and killed at 7, 14 and 21dpi. Other three pigs were used as controls and killed at 21dpi. Specific PRRSV-antibodies and viraemia were detected from blood samples. Histopathology, PRRSV-immunohistochemistry and TUNEL technique were performed on tissue samples.

**Results:** Apoptosis phenomena were observed mainly in lymphocytes and PRRSV antigen in macrophages of lymphoid organs of inoculated animals, showing both a peak of expression at 21dpi. However, the number of apoptotic cells was higher than the number of PRRSV positive cells at the end of the study. In addition, apoptotic cells and PRRSV-positive cells were located in different structures of lymphoid organs.

**Discussion & Conclusion:** PRRSV-positive macrophages might modulate the apoptosis phenomena in other cells, mainly lymphocytes, by means of an indirect mechanism. Furthermore, apoptosis phenomena in B- and T-cell areas of lymphoid organs may play a role in the impairment of the host immune response.

Financial support by project number AGL2009-12438/GAN.

## **P66- PORCINE CIRCOVIRUS TYPE 2 (PCV2) IN CASES OF DIARRHOEA IN PIGS**

*Anna Szczotka, Zygmunt Pejsak.*

*National Veterinary Research Institute, Department of Swine Diseases, Partyzantow 57, 24-100 Pulawy, Poland, anna.szczotka@piwet.pulawy.pl*

**Introduction:** Porcine circovirus type 2 (PCV2) is an etiological agent of postweaning multisystemic wasting syndrome (PMWS) in pigs. The aim of the study was to analyze the presence of PCV2 in cases of antibiotic non-responsive diarrhoea and to evaluate the possible role of the virus in development of enteritis in pigs.

**Material and methods:** Internal organs were collected from 101 pigs, representing 52 Polish farrow-to-finish farms, PMWS-positive or PMWS-suspected. Sections of lymph nodes and intestines (ileum, caecum and colon) were analyzed for presence of PCV2 DNA by in situ hybridization test (ISH). They were also hematoxylin-eosin (HE) stained for standard histopathological examination. Additionally, fecal samples were tested for presence of *Brachyspira hyodysenteriae* and *Lawsonia intracellularis* by PCR.

**Results:** In samples from 19 (30.36%) farms large amounts of PCV2 DNA were detected in lymph nodes and intestines by ISH. In samples from 4 (7.70%) farms PCV2 was found in abundant amount in lymph nodes only. In material from 3 farms PCV2 was present exclusively in intestines, while 26 (50.00%) farms were negative. In this group in 6 farms *Lawsonia intracellularis* was confirmed and *Brachyspira hyodysenteriae* in 1 farm.

**Discussion & Conclusions:** In PMWS-affected pigs PCV2 may be found in lymph nodes and in intestines and it correlates with diarrhea. PCV2 identification may be therefore important in differential diagnosis of enteric disorders in pigs.

**P67- AN OUTBREAK OF CONGENITAL POXVIRUS INFECTION IN A COMMERCIAL BREEDING PIG HERD**

*Cardona S, De Martino A, Urra M, Jeffrey M, De las Heras M.*

*Departamento de Patología Animal. Universidad de Zaragoza, Zaragoza. Spain.  
lasheras@unizar.es*

**Introduction:** Congenital pox infection in swine has been described infrequently with only sporadic cases reported from North America and northern Europe. We describe here 5 piglets with skin lesions associated with poxvirus infection.

**Materials and Methods:** In a Spanish commercial pig breeding herd a congenital skin problem was detected. Over a two week farrowing period, three litters were affected. Five piglets from these three litters were found with severe skin problems. Two of them were slaughtered when 24 hour old and submitted for necropsy. Samples from skin and other organs were processed for routine histopathology and electron microscopy.

**Results:** Papules, erosions or ulcerations from 2-14mm were found distributed over the entire body but were more severe on the ears, lips, snouts and distal parts of the limbs. In one piglet the same lesions were found over the tongue. No major changes in other internal organs were found. Histopathology showed keratinocytes with prominent ballooning degeneration and necrosis with abundant eosinophilic and intracytoplasmatic inclusion bodies. Electron microscopy showed poxvirus particles in all the lesion specimens.

**Discussion:** This is the first congenital pox infection in swine described in Spain. The origin of the infection is unknown.

**P68- HSP 70 MEDIATED INNATE IMMUNITY IN THE BRAIN OF MICE INFECTED WITH VESICULAR STOMATITIS VIRUS.**

*Rocha PRD<sup>1</sup>, Kim MY<sup>2</sup>, Capucchio MT<sup>1</sup>, Shu Y<sup>2</sup>, Oglesbee M<sup>2</sup>.*

*1University of Turin, Grugliasco, Italy. 2The Ohio State University, Columbus, USA. ; pauloricardo.dellarmelinarocha@unito.it*

**Introduction:** Cellular heat shock proteins (hsp) promote innate immunity in the virus infected and protects against viral neurovirulence. We tested the hypothesis that protection mediated by the major inducible 70 kDa hsp (hsp70) reflects reduction in virus-induced cytopathic effect (CPE), particularly in the hippocampus.

**Materials and Methods:** Transgenic mice express hsp70 in neurons. Four weeks old C57BL/6 transgenic (TG, n = 11) and non-transgenic (NT, n = 13) mice were infected intranasally with  $1 \times 10^6$  PFU of vesicular stomatitis virus. Animals were euthanized at 3, 7 and 15 days post infection (dpi). Mortality rate, brain viral titer, and cytopathic effects of H&E stained tissue sections were evaluated.

**Results:** Mortality was 95% in NT mice and 50% in TG mice, with deaths first observed at 7 dpi. Greater viral clearance was present in TG versus NT mice at 7 dpi, with clearance being complete in survivors at 9 dpi. No significant difference in the level and distribution of CPE between both genotypes was observed.

**Discussion & Conclusion:** Survival rate and viral titer indicate that TG mice are more resistant to infection than NT mice, supporting the role of hsp70 in host protection against infection. In contrast, CPE was not a good predictor for survival in mice.



**P69- ROLES OF UBIQUITIN AND HEAT SHOCK PROTEIN 70 IN FORMATION OF NEGRI'S BODY LIKE STRUCTURE IN VITRO.**

*Sakai Y, Sunden Y, Umemura T.*

*Laboratory of Comparative Pathology, Graduate School of Veterinary Medicine, Hokkaido University. Japan. asakai@vetmed.hokudai.ac.jp*

**Introduction:** Negri's body-like inclusions (NBLs) found in rabies virus-infected cells were recently demonstrated to be the site of viral RNA synthesis. Despite the important function of IBLs, little is known about them. In the present study, the roles of ubiquitin and hsp70 in the development of IBLs were investigated because these proteins accumulate in IBLs together with rabies virus (RBV) proteins, and their physiological function correlates with the translocation of cellular proteins.

**Materials and Methods:** Inhibitors of Hsp70 or E1 ubiquitin ligase were used to analyse the role of Hsp70 or ubiquitin. NA cells, a murine neuroblastoma cell line, were maintained in Eagle's minimum essential medium (MEM), and the media were replaced by inhibitor -containing media, followed by addition of the RBV to the media. The cells were cultured for 24 h in the presence of inhibitor and RBV. After that, the cells underwent immunofluorescent staining of RBV nucleoprotein, RNA extraction or protein extraction.

**Results:** RBV spread was markedly suppressed by inhibitor treatment. Inhibition of ubiquitination impaired the formation of NBLs and consequently suppressed viral replication, while inhibition of Hsp70 did not affect NBL formation or replication but prevented segregation of NBL. Immunofluorescent staining demonstrated late-endosome marker, Rab9, encircled or co-localized with NBLs.

**Conclusion and Discussion:** Ubiquitination is required for the formation of NBLs and ubiquitin-dependent transport of the RBV protein into late-endosomes might be important for the formation of NBLs. Hsp70 plays a role in the event after viral replication such as assembly or budding of RBV.

**P70- COMPARISON OF ELISA ANALYSIS FROM SERUM AND LUNG EXTRACT SAMPLES OF PIGS NATURALLY INFECTED WITH *Mycoplasma hyopneumoniae***

*Díaz J<sup>P</sup>, Paz Y<sup>1,2</sup>, Quesada-Canales O<sup>2</sup>, Rivero MA<sup>1</sup>, Saavedra P<sup>3</sup>, Fernández A<sup>1,2</sup>, Andrada M<sup>1,2</sup>.*

*Department of Morphology1. Unit of Veterinary Histology and Pathology. University Institute for Animal Health2. Department of Mathematic3. Faculty of Veterinary. Universidad de Las Palmas de Gran Canaria. Spain. mandrada@dmor.ulpgc.es*

**Introduction:** *Mycoplasma hyopneumoniae* (Mh) is a pathogen of great importance in swine production. In different countries, antibodies against Mh have been detected in wild boars. As obtaining adequate serum for serological studies in wild boars is difficult, the study from tissue banks could be a tool for evaluating serologically the health of these populations. The objective of the present study was to evaluate the suitability of an ELISA test from lung extract samples (LES) and its possible application for serological diagnosis of Mh in pigs.

**Materials and Methods:** A preliminary study to compare ELISA test from LES with ELISA test from serum samples, and immunohistochemistry with ELISA test from serum samples (SS), was carried out in 33 pigs at slaughter.

**Results:** Results for sensitivity, specificity, prevalence, efficiency, positive and negative predictive parameters were 0.73, 1.0, 0.45, 0.87, 1.00, 0.81, respectively, when comparison between ELISA test results from SS and from LES was made; and 0.93, 1.0, 0.45, 0.96, 1.0, 0.94, respectively, when comparison between ELISA test results from SS and immunohistochemistry results was made.

**Discussion and conclusions:** ELISA test from LES was demonstrated to be an adequate serological ancillary technique while diagnosing Mh infection in pigs.

**P71- QUANTIFICATION AND LOCALIZATION WITHIN THE BRONCHIAL TREE OF LESIONS INDUCED BY *Mycoplasma hyopneumoniae* IN NATURALLY INFECTED PIGS.**

*Ramírez T<sup>1</sup>, Gil V<sup>2</sup>, Quesada-Canales O<sup>2</sup>, Paz Y<sup>1,2</sup>, Sierra E<sup>2</sup>, Rodríguez F<sup>1,2</sup>, Andrada M<sup>1,2</sup>*

*Department of Morphology<sup>1</sup>. Unit of Veterinary Histology and Pathology. University Institute for Animal Health<sup>2</sup>. Faculty of Veterinary. Universidad de Las Palmas de Gran Canaria. Spain.*

**Instruction:** *Mycoplasma hyopneumoniae* (Mh) is the primary agent of Porcine Enzootic Pneumonia. The predominant histological lesion is the hyperplasia of the bronchus-associated lymphoid tissue (BALT). Livingston et al. (1972), classified these lesions into four stages. The aim of this study was to determinate the severity of the histological lesions, quantify and locate them within the bronchial tree.

**Materials and Methods:** Thirty-five pigs were inspected at slaughter. Pneumonia patterns and the percentage of affected lung parenchyma were determined. The BALT of each bronchus and bronchiole was evaluated and immunohistochemical study against Mh was performed.

**Results:** Eighty-three per cent of animals showed cranioventral bronchopneumonia with 12.9% of pneumonic lesions. The predominant histological lesion was stage II (72.4%). In bronchi, bronchioles and in terminal and respiratory bronchioles also predominated stage II (44, 55.2 and 65%, respectively). Mh was detected in the 65.5% of the animals.

**Discussion and Conclusions:** Changes in the localization of Mh within the bronchial tree during the course of infection have been reported. In this study we have determined the distribution of Mh-induced lesions within the different parts of the bronchial tree. Further studies are desirable to research the immune response in the different levels of the bronchial tree.

**P71- QUANTIFICATION AND LOCALIZATION WITHIN THE BRONCHIAL TREE OF LESIONS INDUCED BY *Mycoplasma hyopneumoniae* IN NATURALLY INFECTED PIGS.**

*Ramírez T<sup>1</sup>, Gil V<sup>2</sup>, Quesada-Canales O<sup>2</sup>, Paz Y<sup>1,2</sup>, Sierra E<sup>2</sup>, Rodríguez F<sup>1,2</sup>, Andrada M<sup>1,2</sup>*

*Department of Morphology1. Unit of Veterinary Histology and Pathology. University Institute for Animal Health2. Faculty of Veterinary. Universidad de Las Palmas de Gran Canaria. Spain.*

**Instruction:** *Mycoplasma hyopneumoniae* (Mh) is the primary agent of Porcine Enzootic Pneumonia. The predominant histological lesion is the hyperplasia of the bronchus-associated lymphoid tissue (BALT). Livingston et al. (1972), classified these lesions into four stages. The aim of this study was to determinate the severity of the histological lesions, quantify and locate them within the bronchial tree.

**Materials and Methods:** Thirty-five pigs were inspected at slaughter. Pneumonia patterns and the percentage of affected lung parenchyma were determined. The BALT of each bronchus and bronchiole was evaluated and immunohistochemical study against Mh was performed.

**Results:** Eighty-three per cent of animals showed cranioventral bronchopneumonia with 12.9% of pneumonic lesions. The predominant histological lesion was stage II (72.4%). In bronchi, bronchioles and in terminal and respiratory bronchioles also predominated stage II (44, 55.2 and 65%, respectively). Mh was detected in the 65.5% of the animals.

**Discussion and Conclusions:** Changes in the localization of Mh within the bronchial tree during the course of infection have been reported. In this study we have determined the distribution of Mh-induced lesions within the different parts of the bronchial tree. Further studies are desirable to research the immune response in the different levels of the bronchial tree.

**P72- A MODEL OF INTRATRACHEAL INOCULATION FOR TESTING VACCINES AGAINST *Chlamydia abortus* IN SHEEPS**

*JA Navarro; MR Caro; N Ortega; AJ Buendía; MC Gallego; L Del Rio; F Cuello; A Murcia; D Alvarez; J Sanchez; J Salinas*

*Facultad de Veterinaria. University of Murcia. Spain. jnavarro@um.es*

**Introduction:** *Chlamydia abortus* is a sheep pathogen that infects placenta and causes ovine enzootic abortion. The use of intratracheal *C. abortus* infection is analyzed to evaluate the effectiveness of vaccination.

**Material and methods:** Ewes were infected by intratracheal route with  $5 \times 10^7$  UFI of *C. abortus* after immunization with an inactivated vaccine QS-21 adjuvated. Nonvaccinated sheeps served as infection control group. Animals were killed at days 8 and 22 pi. Lung samples were used for *C. abortus* isolation and immunohistochemical characterization of the inflammatory infiltrate. Whole blood was incubated with chlamydial antigen for measuring IL-10 and IFN- $\gamma$  production.

**Results:** Isolation data indicated a higher level of *C. abortus* at day 8 pi in non vaccinated group than in vaccinated group. At day 22 pi chlamydial isolation was positive only in one non-vaccinated sheep. Non vaccinated animals killed at day 8 pi showed consolidation areas in the lungs. Microscopically, sheeps showed bronchointerstitial pneumonia associated to chlamydia antigen. At day 22 pi, histological analysis showed mild interstitial pneumonia but no chlamydial antigen. In vaccinated sheeps only one animal at day 8 pi displayed bronchointerstitial pneumonia with scarce chlamydial antigen. At day 22 pi, vaccinated sheep displayed areas of atelectasis without chlamydial antigen. The IL-10 response diminished in vaccinated. At day 8 pi the amount of IFN $\gamma$  was higher in vaccinated-infected sheeps but no differences were observed onwards.

**Conclusion:** These findings indicate that the intratracheal inoculation is a useful tool for testing vaccines against *C. abortus* infection.

**P73- IL-10 OVEREXPRESSION IN TRANSGENIC MICE INCREASE MULTIPLICATION OF *Chlamydia abortus***

AJ Buendía; JA Navarro; MR Caro; N Ortega; MC Gallego; L Del Rio; F Cuello; A Murcia, J Sánchez; J Salinas

Facultad de Veterinaria. University of Murcia. Spain. [abuendia@um.es](mailto:abuendia@um.es)

**Introduction:** The IL-10 is a key immunoregulatory cytokine, downregulating the Th1 response. The use of mice overexpressing IL-10 infected with *Chlamydia abortus* could determine its effects on the immune response.

**Material and methods:** WT and macIL-10tg (tg-IL-10) mice were infected with  $4 \times 10^6$  IFUs of *C. abortus* after immunization with an inactivated vaccine. Four groups were established: (a) WT vaccinated (b) WT non vaccinated (c) tg-IL-10 non vaccinated and (d) tg-IL-10 vaccinated mice. Mice were killed at 4, 9 and 28 days pi. Liver samples were used for chlamydial isolation and immunohistochemical characterization of inflammatory infiltrate.

**Results:** Isolation data indicated high level of *C. abortus* at 4 and 9 days pi in all groups, except in the WT vaccinated group. At 28 days pi *C. abortus* was detected only in tg-IL-10 vaccinated and non vaccinated mice. All groups of mice showed multifocal hepatitis at 4 day pi; with a higher number of neutrophils in WT mice. At day 9 pi foci were formed by lymphocytes in all groups. The number and size of foci decreased at day 28 pi in all mice except in the tg-IL-10 non vaccinated group.

**Conclusion:** These findings indicated that over-expression of IL-10 avoid the clearance of *C. abortus*, allowing chronic infections and decreasing the efficacy of vaccination.

**P74- NEUTROPHILS ARE THE PRIMARY SOURCE OF IFN- $\gamma$  IN LISTERIC RHOMBENCEPHALITIS OF RUMINANTS**

*Ahmed Y., Guldimann C., Zurbriggen A., Vandeveld M., Janda J., Oevermann A.*

*Vetsuisse Faculty, University of Bern, Switzerland,  
anna.oevermann@vetsuisse.unibe.ch.*

**Introduction:** Rhombencephalitis is the most common presentation of listeriosis and amongst the most prevalent CNS infections in ruminants. In experimentally infected mice, IFN- $\gamma$  is strongly upregulated and involved in the clearance of LM. However, only little is known about IFN- $\gamma$  expression in listeriosis of ruminants. The present study investigated the spatiotemporal expression and the cellular origin of IFN- $\gamma$  in listeric rhombencephalitis of cattle.

**Materials and Methods:** IFN- $\gamma$  expressing cells were quantified and their localization determined in immunohistochemically stained brainstems of cattle with listeriosis, viral encephalitis and of normal cattle. IFN- $\gamma$ <sup>+</sup> cells were identified by morphology and double-immunofluorescence (IF). Bovine neutrophils were isolated, infected in vitro with LM and screened for IFN- $\gamma$  expression by double-IF and quantitative RT-PCR.

**Results:** IFN- $\gamma$  positive cells were significantly more numerous in listeriosis than in viral encephalitis. Intriguingly, IFN- $\gamma$  expression was highest in acute rhombencephalitis and decreased significantly with chronicity. In line with these findings, most IFN- $\gamma$  expressing cells had a nuclear morphology of neutrophils. In situ results were confirmed by in vitro data, which showed increased IFN- $\gamma$  expression in neutrophils upon LM infection.

**Conclusions:** We show that IFN- $\gamma$  is specifically upregulated during the early phase of natural listeric rhombencephalitis in ruminants and primarily produced by neutrophils. Our data indicate that IFN- $\gamma$  is a crucial player in the innate immune response of ruminants against LM.

**P75- BEHAVIOUR OF TWO *Streptococcus suis* SEROTYPE 2 FIELD STRAINS IN AN ACUTE EXPERIMENTAL INFECTION IN PIGS**

Gómez-Gascón L<sup>1,2</sup>, Gómez-Laguna J<sup>3</sup>, Luque I<sup>1,2</sup>, Amarilla P<sup>4</sup>, Cardoso F<sup>1,2</sup>, Carrasco L<sup>4</sup>, Tarradas C<sup>1</sup>,

2. CICAP, Pozoblanco, Córdoba (Spain), jgomez@cicap.es

**Introduction:** Virulence markers just as suilysin (Sly), muramidase-related protein (MRP), and extracellular factor (EF) has been reported for *Streptococcus suis*. In this study, two *S. suis* serotype 2 field strains with a different virulence marker profile were analyzed during the acute phase of infection.

**Materials and Methods:** Eight conventional, 7-weeks-old pigs from a *S. suis*-free herd were randomly divided into three groups: group A (3 animals; strain 235/03 at 1x10<sup>9</sup>cfu/mL, MRP+EF+Sly+), group B (3 animals; strain 123/11 at 1x10<sup>9</sup>cfu/mL, MRP-EF-Sly-), and group C (2 animals; PBS). Clinical signs were monitored each 12 hours. Inoculated pigs were death or killed at 3dpi due to animal welfare conditions. At necropsy tissue samples were collected for the microbiological study, and fixed in 10% buffered formalin for the histopathological study.

**Results:** The clinical signs score was slightly higher in group B than in group A, however, both groups showed a moderate enhancement of the temperature and a predominance of articular signs over nervous symptoms. Histopathological lesions were more marked in group A, and mainly focused on CNS. In both inoculated groups the strains were recovered from all examined organs.

**Discussion & Conclusions:** Both strains showed a similar virulence when compared the clinical signs, organ spread and histopathological lesions despite their different virulence factors pattern.



## **P76- CHARACTERIZATION OF ACUTE MAMMARY GLAND LESIONS ASSOCIATED WITH DIFFERENT *Staphylococcus aureus* STRAINS**

*Guerrero I., Viana D., Selva L., Ferrián S., Penadés M., García-Quirós A., Corpa J.M*  
*Universidad CEU Cardenal Herrera, Spain, jmcorpa@uch.ceu.es*

**Introduction:** *Staphylococcus aureus* is an adaptable and opportunistic pathogen capable of causing different lesions ranging from mild to severe depending on the infecting bacterial strain. Staphylococcal mastitis is one of the main causes of culling of adult rabbit does from commercial rabbitries. The objective of this study was to characterize the acute lesions in mammary glands infected with two different strains of *S.aureus* (A1/III1/δ and B1/IV2/α).

**Materials and methods:** Twelve primiparous rabbit does were inoculated in mammary gland with 100 CFU of each strain. Gross evolution of inflammation and rectal temperature were reported every 12 hours post-inoculation during 4 days. Mammary gland samples were taken for later histopathologic and immunohistochemical studies.

**Results:** Mammary glands infected with the strain A1/III1/δ presented severe inflammation with dermonecrosis, dermal edema and extensive areas of coagulative or liquefactive necrosis. However, mammary glands infected with strain B1/IV2/α showed mild inflammation with heterophil infiltration in the interstitium and lumen of alveoli.

**Discussion and Conclusion:** Although both bacterial strains were isolated from natural clinical mastitis, the results of the experimental infection showed that strain A1/III1/δ produces an acute and severe response in mammary gland while strain B1/IV2/α showed scarce virulence. Therefore, broadening the knowledge of the way strain B1/IV2/α is capable of causing lesions in natural conditions despite its lower virulence, would be of great usefulness for clarifying the pathogenesis of the disease.

### Acknowledgements

This study was supported by grants from the CEU Cardenal Herrera University (PRCEU-UCH01/11) and the Comisión Interministerial de Ciencia y Tecnología (AGL2011-30170-CO2-02).

**P77- ENDOCARDITIS IN FOUR WEEKS-OLD BROILERS DUE TO ENTEROCOCCUS SPP.**

*Andrés S, Bolea R, Chirino M, Vargas A, Marín B, Badiola JJ, Moreno B*

*Departamento de Patología Animal .Facultad de Veterinaria de Zaragoza.  
bmoreno@unizar.es*

**Introduction:** Endocarditis in broilers is rarely reported and usually associated with *Staphylococcus aureus*, streptococci and enterococci. This work describes a preliminary study of endocarditis in broilers.

**Material and methods:** Post-mortem examination was performed in thirty broilers from a farm with history of sudden death in birds approximately four weeks-old. Pathological and microbiological studies were made in two cases of endocarditis.

**Results:** A severe cauliflower-like vegetative endocarditis originating from the right atrioventricular valve and occupying most of the right ventricular lumen was found in two broilers (6.7%). Microscopically, a high number of coccoid bacteria mixed with an exudate composed by heterophils, some macrophages and fibrin were observed. In one broiler, a severe hemorrhagic typhlitis due to coccidiosis was also found. In other six broilers this typhlitis was also detected. Pure cultures of *Enterococcus* spp. were isolated in both cases.

**Discussion and Conclusion:** Endocarditis in broilers due to *Enterococcus* spp. is mainly found on the mitral valves and tends to be of small size. In this case lesions were severe and localized on the tricuspid valves. Its pathogenesis usually remains speculative and a translocation from the intestinal lumen has been sometimes suggested. In the present case a possible relationship with protozoal typhlitis might have been existed but further studies are needed and are in progress.

**P78- RELATIONSHIP BETWEEN HISTOPATHOLOGICAL FINDINGS AND SALMONELLA SPECIES, TESTED BY BACTERIAL CULTURE, SERTYPING AND PCR METHODS IN CATTLE.**

*Sasani.F; Zahedi. M.M ; Musakhani.F ; Zafari.M ; Bashiri.S*

*Department of Veterinary Pathology, Faculty of Veterinary Medicine, The University of Tehran, Iran.*

**Introduction:** Between 2010\_2011, 36 cases of salmonella positive animals were studied by histopathological examinations.

**Material and methods:** In this study after bacterial culturing of salmonella, serotyping was done. Highest frequency, about 50% (n=18) belonged to serogroup D and 25% belonged to serogroups B and C together (9 cases in each group). 15 different organs were studied in histopathologic sections by H&E method.

**Result:** There was enteritis in 40% and hepatitis in 21% while lymphoid tissue depletion was seen in 15%. Another lesion was necrosis in intestine 80%, kidney 42%, lymph node 33%, spleen 23% and liver 14%. Thrombosis in lymph node 33%, cerebellum 33%, cerebrum 25%, spleen 10%, heart 10%, lung 8% and intestine 10%. In 14 livers, paratyphoid nodule 29%, focal necrosis 14%, centrilobular necrosis 7%, fatty degeneration 14% and bile retention in 14%. 10 examined intestine showed 80% enteritis which all of them were in serogroup D.

**Discussion:** Final conclusion of this study revealed that major pathological findings were in intestine and liver tissues as are reported in other texts and references. The most identified serogroup in this study was serogroup D.

**P79- PROLIFERATIVE PLEURITIS CAUSED BY ACTINOMYCES HORDEOVULNERIS ASSOCIATED WITH LEUKEMIA IN A DOG**

*Gimeno M<sup>1</sup>, Pinczowski P<sup>1</sup>, Pérez M<sup>1</sup>, Insausti N<sup>1</sup>, Aceña C<sup>1</sup>, Cortabarría N<sup>2</sup>, Atxaerandio R<sup>2</sup>, de Martino A<sup>1</sup>, Aduriz G<sup>2</sup>, Luján L<sup>1</sup>*

*1University of Zaragoza and 2Neiker, Bilbao, Spain. Lluís.Lujan@unizar.es*

**Introduction:** Actinomycosis in dogs can cause serosal pyogranulomatous lesions. In human, Actinomyces species are opportunistic pathogens usually associated with immunosuppressive processes such as neoplasias. The objective of this work is to describe a case of a severe proliferative and pyogranulomatous pleuritis due to Actinomyces hordeovulneris concomitant with leukemia in a dog.

**Materials and Methods:** A 2 year-old, male, Yorkshire terrier dog was presented with severe dyspnea caused by pleural effusion, non-responsive to treatment and died.

**Results:** Post-mortem examination revealed a massive pyothorax with sulfur granules and a severe proliferative and pyogranulomatous pericarditis and pleuritis. Histopathologically the parietal and visceral pleura and the pericardium were thickened due to a severe infiltration of lymphocytes, neutrophils and macrophages and reactive mesothelial cells, connective tissue and several areas of neovascularization. Multifocal Splendore-Hoeppli phenomenon was seen with formation of eosinophilic material (radiate configuration) around filamentous bacterial structures. Microbiological and molecular (PCR and DNA sequencing) analysis identified Actinomyces hordeovulneris (CIP 103149). There was an intense neoplastic lymphoid proliferation at the liver, mainly around the portal areas and within sinusoids. Neoplastic cells were also seen in blood vessels. This leukemia is being phenotyped by immunohistochemistry.

**Discussion & Conclusion:** To our knowledge this is the first reported case of a dog infected by Actinomyces hordeovulneris associated with leukemia as a possible immunosuppressive process.

**P80- HISTOPATHOLOGICAL CLASSIFICATION OF THE DIFFERENT STAGES OF LYMPH NODE GRANULOMAS FROM PPD POSITIVE GOATS.**

*Pérez M<sup>2</sup>, Quesada-Canales O<sup>2</sup>, Paz Y<sup>1,2</sup>, Vigo V<sup>3</sup>, Arbelo M<sup>1,2</sup>, Espinosa de los Monteros A<sup>1,2</sup>, Andrada M<sup>1,2</sup>.*

*Department of Morphology<sup>1</sup>. Unit of Veterinary Histology and Pathology. University Institute for Animal Health<sup>2</sup>. Faculty of Veterinary. Universidad de Las Palmas de Gran Canaria. D.G. Ganadería, Canary Government<sup>3</sup>*

**Introduction:** Tuberculous granuloma formation in mammals is thought to be the result of chronic antigenic stimulation. The aim of this study was to classify the histopathological stages of granulomas from PPD positive goats. **Materials and Methods:** Retropharyngeal (RF), preescapular (PE), mediastinal (MD), mesenteric (MS), hepatic (H), mammary (MA) and ileocaecal (IC) lymph nodes, and the ileocaecal valve (V) from 48 PPD positive goats were collected at slaughter for histopathological examination. Granulomas were classified into four stages according to Wangoo et al. (2005).

**Results:** Granulomatous lesions were observed in 37 MS, 32 MD, 23 PE, 19 RF, 14 V, 10 MA, 6 IC, and 3 H. The predominant stage in the lymph nodes with only one type of stage was: stage I in MS (12), PE (11), IC (2) and V (8); and stage IV in MD (15), MA (7), RF (13) and H (2).

**Discussion and Conclusions:** Mycobacterial granulomas are dynamic, changing over the course of infection. This scheme should assist in standardizing descriptions of goat tuberculous lesions naturally infected in lymph nodes and in determining the stages of granulomas. Further studies are needed to characterize the inflammatory cell composition in each stage.

## **P81- COMPARATIVE STUDY ON CROHN'S DISEASE & JOHNE'S DISEASE IN IRAN: HISTOPATHOLOGICAL FINDINGS AND NESTED-PCR**

*Moayer Fariborz , Seyed Farshi A. , Roudgari R.*

*Department of Pathobiology, Faculty of Veterinary Medicine, Karaj branch, Islamic Azad University, Karaj, Iran fariborz\_moayer@yahoo.com*

**Introduction:** Crohn's disease (CD) is a chronic human intestinal inflammatory disorder which an etiologic agent has not been identified. Johne's disease (JD) is a similar chronic enteric granulomatous disease of ruminant species that has been proven to be caused by *Mycobacterium avium* paratuberculosis (MAP). It has been proposed that MAP may also cause CD. In this survey, histopathological findings and results of Nested-PCR test from paraffin-embedded intestinal tissue samples of bovine JD and human CD were compared.

**Materials and Methods:** 100 paraffin embedded of biopsy specimens from patients with CD and 20 intestinal samples from bovine JD were collected for histopathological study by H&E, Z-N staining. All samples were analyzed by Nested-PCR test (*IS900*).

**Results:** Histological examination indicated macrophages and giant cells in granulomas in CD biopsies did not contain bacilli. While ileal tissue samples of JD were thickened by infiltration with macrophages and epithelioid cells. Unlike CD, acid-fast intracellular bacilli were always present. In Nested-PCR, fifty three of the 100 (53%) intestinal samples from patients with CD and all (100%) of the animal tissues were positive for MAP by *IS900* sequence.

**Discussion:** The results of this study indicated that MAP is present in more than half of intestinal biopsy samples of patients with CD. There are many similarities and differences between CD and JD. According to the research it is possible that MAP is involved in Crohn's disease.

**P82- CYTOKINE AND INFLAMMATORY MEDIATORS EXPRESSION IN INTESTINAL TISSUES OF LAMBS SHOWING DIFFERENT TYPES OF LESIONS IN EXPERIMENTAL PARATUBERCULOSIS.**

*Delgado L<sup>1</sup>, Guilloteau LA<sup>2</sup>, Foret B<sup>2</sup>, Ferreras MC<sup>1</sup>, García Marín JF<sup>1</sup>, Pérez V<sup>1</sup>*

*1Instituto de Ganadería de Montaña (CSIC-ULE), Facultad de Veterinaria, Universidad de León, Spain. 2 INRA Centre de Tours, Nouzilly, France.  
valentin.perez@unileon.es*

**Introduction:** Animals infected with *Mycobacterium avium* subspecies paratuberculosis (Map) show a variety of lesions, from focal, persistent lesions, up to diffuse forms. It has been proposed that the local immune response mounted against Map in the intestine could play a role in the development of the lesions. This study investigates the expression of cytokines and other inflammatory mediators, measured by qPCR, in tissues from lambs experimentally infected with Map.

**Materials and Methods:** Tissue samples (distal ileum, jejunal Peyer's patches, mesenteric lymph node) from 14 lambs (11 infected with Map and 3 controls) were examined by histopathological methods. The same samples were assayed by qPCR for the determination of the expression of the following genes: Th1 response (TNF- $\alpha$ , IL-12, IFN- $\gamma$ , IL-1 $\beta$ , IL-6), Th2 (IL-13, IL-4, IL-10), Th17 (IL-17), TLR-2 innate immune response receptor, FoxP3 transcription factor, and urocortin (UCN).

**Results:** Although a great individual variability was found, differences were seen in some gene expression: IL-10 levels were higher in lambs with the more severe lesions in the distal ileum; IFN- $\gamma$  expression increased in tissues from infected lambs that did not show lesions; lambs with diffuse lesions had a lower IL-1 $\beta$  expression; IL-3 levels were higher in lambs with focal lesions; UCN expression was higher in lambs with focal and multifocal forms.

**Discussion & Conclusion:** This study confirms the high complexity of paratuberculosis pathogenesis. Some lesional forms are associated with changes in several cytokine and inflammatory mediators expression.

This work was supported by grant AGL2008-05820-C02-02 from MICINN.

**P83- LESIONAL AND IMMUNE RESPONSE IN THE EARLY STAGES OF AN EXPERIMENTAL INFECTION OF LAMBS WITH DIFFERENT STRAINS OF *Mycobacterium avium* subspecies *paratuberculosis*.**

*Fernández M<sup>L</sup>, Sevilla P, Benavides J, Fuertes M<sup>l</sup>, Morales S<sup>l</sup>, Delgado L<sup>l</sup>, Garrido JM<sup>2</sup>, García Marín JF<sup>1</sup>, Ferreras MC<sup>1</sup>, Pérez V<sup>1</sup>.*

*IInstituto de Ganadería de Montaña (CSIC-ULE), Facultad de Veterinaria, Universidad de León, 2Neiker-Tecnalia.valentin.perez@unileon.es*

**Introduction:** The strain of *Mycobacterium avium* subspecies *paratuberculosis* (Map) could play a role in the development of the lesions. Moreover, there is a need of standardize experimental infections by finding the appropriate strain. This study investigates the inflammatory and peripheral immune response (cellular and humoral) related to the infection with different Map strains in lambs.

**Materials and Methods:** A total of 36 lambs were divided into 6 groups of 6 animals. Each lamb was orally challenged with a total dose of  $2.5 \times 10^9$  ufc of the following Map strains: Group (1): uninfected control animals; (2) LETI ovine strain, (3) ovine strain 22-G, (4) K-10 reference bovine strain, (5) 764 ovine strain and (6) pigmented OVICAP49 strain. Antibody and interferon-gamma (IFN- $\gamma$ ) production in peripheral blood was assessed from 0 to 120 dpi, when 2 lambs from each group were euthanased and examined by pathological methods.

**Results:** Lambs from groups 3, 4 and 5 showed a higher production of IFN- $\gamma$  from 60 dpi. Antibodies increased in groups 4 and 4 from day 120. At 120 dpi, lambs from group 5 showed a diffuse granulomatous infiltrate, affecting mostly the jejunal Peyer's patches (JPP) and related mucosa. In the rest of infected groups, only focal granulomas were seen in the JPP and ileocaecal valve, more abundant in group 4.

**Discussion & Conclusion:** Differences in lesional severity appear in relation with the Map strain used in the experimental infection of lambs. Bovine strains cause the most severe lesions.

This work was supported by grant AGL2008-05820-C02-02 from MICINN.



**P84- *Mycobacterium bovis* INFECTION IN A DONKEY**

*Bryan J<sup>1</sup>, den Boon P<sup>2</sup>, McGuirk J<sup>3</sup>, Madigan G<sup>3</sup>, Fogarty U<sup>4</sup>.*

*1UCD School of Veterinary Medicine, Dublin, Ireland; 2The Donkey Sanctuary, Cork, Ireland; 3Central Veterinary Research Laboratory, Kildare, Ireland; 4Irish Equine Centre, Kildare, Ireland. jill.bryan@ucd.ie*

**Introduction:** Mycobacterial infections are rare in equines. *Mycobacterium bovis* (*M. bovis*) is an important zoonotic pathogen causing disease in a wide range of animal species. Infection with *M. bovis* has not been documented previously in the donkey.

**Materials and Methods:** A 29-year-old donkey gelding presented with depression, pyrexia, tachycardia, tachypnoea and generalised wheezes and crackles on thoracic auscultation. Haematologic examination identified neutrophilic leukocytosis. Response to treatment with antimicrobials and non-steroidal anti-inflammatories was poor and the donkey was euthanased.

**Results:** On gross postmortem examination the lungs were diffusely consolidated with an irregular nodular appearance of the surface and multiple coalescing, firm, pale masses diffusely distributed throughout the parenchyma. Multiple, variably sized, firm, pale nodular masses were also identified within the mediastinum, epicardium, omentum, kidneys, liver, spleen and diaphragm. Histopathological examination of lung showed prominent interstitial fibrosis and diffuse granulomatous inflammation in which acid-fast bacilli were occasionally identified. The additional nodular masses represented foci of chronic granulomatous inflammation. Culture of lung yielded a heavy growth of mycobacteria confirmed to be *M. bovis* by molecular techniques (GenoType MTBC).

**Conclusion:** Although rare in equines, disease caused by *M. bovis* should be considered as a possible differential diagnosis in donkeys presenting with signs of respiratory disease and respiratory or generalised granulomatous inflammation.

## **P85- HISTOPATHOLOGICAL AND BACTERIOLOGICAL INVESTIGATION OF RESPIRATORY LESIONS IN SLAUGHTERED DROMEDARY CAMELS IN IRAN.**

*Tavasoly Abbas, Bagheri Farnoosh, Kamyabi-moghaddam Zahra, Akbarinejad Vahid, Shojaei Mohammad, Kazempoor Reza.*

*Department of Pathology, faculty of Veterinary medicine, University of Tehran, Tehran, Iran.*

**Introduction:** Lung infections, specially pneumonia are major diseases of domestic animals. Present study was conducted to investigate the prevalence of different pulmonary lesions in slaughtered camels.

**Material and Methods:** From February 2009 to February 2010, 300 lungs of dromedary camels slaughtered at an abattoir located in Tehran province, Iran were grossly examined for the presence of pneumonic lesions. 120 lungs were diagnosed affected, from which specimens were collected for histopathological and bacteriologic examinations.

**Result:** Histopathology revealed that interstitial pneumonia, 41 cases (20.29%), 31 cases (15.34%) Emphysema, 29 (14.35%) cases Granulomatous pneumonia, 25(12.37%) cases verminous pneumonia, 19 (9.4%) cases Bronchopneumonia, 15 (7.42%) cases atelectasis, 8 (3.96%) cases hydatid cyst, 9 (4.45%) cases anthracosis. The microbiological culture of lungs in these camels diagnosed two different genres of bacteria staphylococcus (morbillorum, agalactiae, pyogenes) and streptococcus (auricularis, arlettae, auricularis, lentus, lugdunesis, schleiferi, saprophyticus, captis, haemolyticus, sciuri).

**Discussion:** Interstitial pneumonia was the most common lesion in this study which showed the same results in some other studies. It is known that the etiology of pulmonary disease is so complex and multi factorial, and hence the existence of more than one pulmonary lesion in one animal suggested that one of the lesions could be considered as a predisposing factor or a sequel to the other lesion.

## **P86- THE USE OF PATHOLOGICAL METHODS IN THE DIAGNOSIS OF OVINE ABORTIONS**

*Fernández M, Ferreras MC, González, J, Pérez, C, García-Iglesia, MJ, Pérez V, García Marín JF.*

*Dpt de Sanidad Animal (Anatomía Patológica) Instituto de Ganadería de Montaña (CSIC-ULE), Facultad de Veterinaria, Universidad de León, Spain, valentin.perez@unileon.es*

**Introduction:** Abortion is one of the main causes of economic losses in ovine production. Moreover, some of the causing agents have a zoonotic potential. The practitioners often require a simple, reliable and rapid diagnostic method. This study investigates the use of pathological methods for the establishment of the causes of abortion in sheep.

**Materials and Methods:** Samples from a total of 271 cases of ovine abortion, from 136 flocks located in the “Castilla y León” region (NW of Spain), received from 2004 to 2010 were examined by pathological methods. Additionally, immunohistochemical methods were employed for the detection of several infectious agents.

**Results:** In 164 cases (61%) the cause of abortion could be determined, mostly when samples from placenta and fetus were received. Enzootic abortion (29.5%) and toxoplasmosis (23.5%) were the most commonly diseases diagnosed, characterized by a fibrino-purulent and necrotizing placentitis respectively, and gliosis in the case of toxoplasmosis. Salmonellosis, border disease and Q fever were diagnosed in a lower number (between 2.7 and 10%). Mycotic infections, listeriosis and campilobacteriosis appeared sporadically.

**Discussion & Conclusion:** Pathological examination of the placenta and fetuses has shown to be an efficient method for the diagnosis of ovine abortion caused by infectious agents. Infections by *Chlamydia abortus* and *Toxoplasma gondii* seem to be the most important causes of abortion in our region.

**P87- CELLULAR IMMUNE RESPONSE IN WATER BUFFALO PLACENTAS AFTER INOCULATION WITH NEOSPORA CANINUM DURING EARLY GESTATION.**

*Cantón Germán<sup>1,2</sup>, Konrad José<sup>3</sup>, Caspe Gastón<sup>2</sup>, Moore Prando<sup>4</sup>, Campero Carlos<sup>2</sup>, Chianini Francesca<sup>1</sup>*

*1MoreDun Research Institute, Scotland, 2INTA, Argentina, 3UNNE, Argentina, 4CONICET, Argentina. german.canton@moredun.ac.uk*

**Introduction:** Water buffalo (*Bubalus bubalis*) plays a crucial role in tropical areas and their importance is increasing in western nations. Susceptibility to *Neospora caninum* is not fully understood, although vertical transmission and foetal death has been confirmed after infections and an exacerbated cellular immune response was associated with bovine abortion. The aim of this work was to characterise the placental immune response following experimental infection of water buffalo during early gestation.

**Material and Methods:** Ten pregnant Mediterranean water buffaloes were intravenously inoculated with NC-1 tachyzoites at days 70 (B1) and 90 (B2) of gestation. Dams were euthanized at 28 and 42 days post inoculation. Placentomes were examined by immunohistochemistry using antibodies raised against T-cells (CD3, CD4, CD8,  $\gamma\delta$ TCR), NK and B-cells.

**Results:** Non-suppurative placentitis was the most frequent finding in challenged animals. Inflammation was generally mild to severe in group B1 and mild to moderate in group B2 animals. Inflammation was mainly characterised by infiltration of CD3+,  $\gamma\delta$ TCR+ and CD4+; whereas CD8+ were less numerous. Few NK-cells were observed in infected animals.

**Discussion:** Compared with studies at the same gestation age in cattle, cellular immune infiltrates were less severe. These findings may explain the milder clinical outcome observed in water buffalo after infection with *N. caninum* at the same period of gestation.

**P88- OUTBREAK OF BESNOITIOSIS IN DONKEYS (*Equus asinus*) IN THE SOUTH OF SPAIN**

*Zafra R<sup>1</sup>, Soria-López N<sup>2</sup>, Díez de Castro E<sup>3</sup>, Jaber JR<sup>1</sup>, Mozos E<sup>3</sup>, Pérez J<sup>3</sup>*

*1University of Las Palmas de Gran Canaria, Spain, 2Veterinary Practitioner, Spain, 3University of Córdoba, Spain, rafael.zafra@uco.es*

**Introduction:** Besnoitiosis is a parasitic disease frequent in Africa and Asia affecting both wild and domestic animals caused by *Besnoitia* spp. The aim of this work was to describe the first report to date of besnoitiosis in donkeys with special attention to histopathological lesions.

**Materials and Methods:** Seven out of 13 donkeys from an equine farm showed cutaneous lesions consistent with besnoitiosis. Their age ranged from one-year to seven-years old. Skin biopsies were collected from lesions and fixed in formaldehyde 10% and sections of 4-micrometer thick were obtained for histopathological study.

**Results:** Grossly, animals showed thickened and darkened circular areas involving mainly in snout, ears, shoulders, perineum, conjunctiva and oral mucosa from lower lip. Microscopically, pseudoepiteliomatous hyperplasia and pigmentary incontinence were found in epidermis. Interstitial inflammatory infiltrate composed by lymphocytes and plasma cells was observed in dermis together with cystic structures of different size. A granulomatous reaction composed by macrophages, multinucleated giant cells and fibrous tissue was found sometimes around these cystic structures or necrotic rests of cysts. All animals except one improved after treatment with antibiotics.

**Discussion & Conclusion:** To date, this is the first report of besnoitiosis in donkeys in Spain. Nevertheless, deeper studies of this species (*Besnoitia bennetti*) need to be carried out because the life cycle of the parasite and the definitive host are both still unknown.

## **P89- CANINE LEISHMANIASIS IN THE CENTRAL AND PERIPHERAL NERVOUS SYSTEMS**

*Márquez Merce*<sup>1,2</sup>, *Pedregosa Jose-Raúl*<sup>3</sup>, *López Jesús*<sup>3</sup>, *Marco-Salazar Paola*<sup>1</sup>, *Fondevila Dolors*<sup>1,2</sup> and *Pumarola Martí*<sup>1,2</sup>

<sup>1</sup>*Department of Animal Medicine and Surgery.* <sup>2</sup>*Centre de Biotecnologia Animal i Teràpia Gènica (CBATEG).* *Universitat Autònoma de Barcelona.* <sup>3</sup>*Hospital Veterinario Al Sur. Servicio de Neurología y Neurocirugía del Hospital Veterinario Al Sur.* *Granada. Spain.* *[marti.pumarola@uab.cat](mailto:marti.pumarola@uab.cat)*

**Introduction:** Canine leishmaniasis (CL) is a cutaneous, mucocutaneous or visceral disease caused by intracellular *Leishmania* protozoan parasites. In visceral CL parasites are spread throughout the organism, producing proliferative inflammatory reactions. Among the inflammatory infiltrates macrophages predominate and sometimes amastigotes accumulate inside. Many organs are usually affected, especially the lymph nodes, liver, spleen and skin. Except for the choroid plexuses and meninges, *Leishmania* amastigotes have not been observed affecting nervous tissue in CL.

**Material and methods:** 4-year-old male Labrador retriever dog was presented with a 10-day evolution of tetraplegia and absent postural reflexes. The cerebrospinal fluid (CSF) was positive for *Leishmania* antigens. The brain and spinal cord were fixed and routinely processed for histological evaluation. Paraffin sections, were stained with haematoxylin and eosin (HE). For immunohistochemical (IHC) studies anti-*Leishmania infantum* antibodies (PB-75) were used at 1/1600 dilution to detect the organism.

**Results and Discussion:** We report for the first time the presence of *Leishmania* amastigotes in nervous tissue, producing radiculoneuritis, myelitis and slight meningoencephalitis. The presence of amastigotes inside brain blood vessels and CSF suggests disruption of the blood-brain and blood-CSF barriers allowing the organism to enter the nervous parenchyma.

**P90- FATAL DIARRHOEA DUE TO EIMERIA LEUCKARTI IN A HORSE**

*Marinković Darko, Nešić Slađan, Katić-Radivojević Sofija, Đoković Stefan*

*Faculty of Veterinary Medicine, University of Belgrade, Serbia darko@vet.bg.ac.rs*

**Introduction:** *Eimeria leuckarti* is the only reported coccidium of horses, but it is rarely implicated in the disease process.

**Materials and Methods:** A 4-year old female Thoroughbred with acute onset of colic followed with diarrhoea was referred to the Department of Equine, small animal, poultry and wild animal diseases on Faculty of Veterinary Medicine in Belgrade. After few days despite therapy horse died and necropsy was performed. During necropsy the tissue samples of small and large intestine, as well as liver, spleen, kidney, lung and myocardium were fixed, routinely processed and stained by HE and PAS. Fecal samples were also collected for parasitological examination.

**Results:** Necropsy examination revealed heavy diffuse haemorrhagic-necrotic jejuno-ileitis, focal colitis, serofibrinous peritonitis as well as mild gastric dilatation and spleen and liver congestion. Histopathological examination revealed haemorrhagic-necrotic jejuno-ileitis with microgametes of *Eimeria* species present in epithelial cells of jejunum and ileum. Parasitological examination confirmed that parasites found in fecal samples are oocysts of *Eimeria leuckarti*.

**Conclusion:** Although implication of *Eimeria leuckarti* in the disease process is rare, in some cases it can cause serious gastrointestinal problems.

**P91- BALANTIDIUM COLI IN PMWS-SUSPECTED PIGS**

*Anna Szczotka, Zygmunt Pejsak*

*National Veterinary Research Institute, Department of Swine Diseases, Partyzantow 57, 24-100 Pulawy, Poland,anna.szczotka@piwet.pulawy.pl*

**Introduction:** Porcine circovirus type 2 (PCV2) is an etiological agent of postweaning multisystemic wasting syndrome (PMWS) in pigs. Sometimes in diseased animals diarrhea can be present. The aim of the study was to analyze the presence of PCV2 in tissues from PMWS-suspected pigs.

**Material and methods:** Lymph nodes and intestines from 3 13 – 15-weeks old fatteners representing pig herd with symptoms of PMWS and persistent diarrhea were analyzed by in situ hybridization for the presence of PCV2 and hematoxylin-eosin stained. Also, feces and scrapings from intestinal mucosa were subjected to routine bacteriological examination.

**Results** All the pigs were PMWS-negative. No pathogenic microflora was identified in the testes samples. However, in the intestines *Balantidium coli* (*B. coli*) was found. The protozoons were present not only in the intestinal lumen, but also in the intestinal mucosa.

**Discussion & Conclusions:** *B. coli* is an opportunistic parasite of mammals, including humans. The infection is usually subclinical, but in immunocompromised individuals may lead to fulminant infection with bloody and mucus-containing diarrhea. The identification of *B. coli* in pigs showing symptoms of PMWS and antibiotic non-responsive diarrhea may indicate that these animals might have already recovered from PMWS, but due to PCV2-related immunosuppression *B. coli* infection complicated the clinical presentation of the disease.



## **P92- IMMUNOHISTOCHEMICAL STUDY OF THE INFLAMMATORY RESPONSE IN THE RUMEN AND RETICULUM OF *Calicophoron daubneyi*-INFECTED CATTLE**

<sup>1</sup>Ferreras M C, <sup>1</sup>Pérez V, <sup>1</sup>González-Lanza M C, <sup>1</sup>Benavides J, <sup>2</sup>Mezo M, <sup>1</sup>Fuertes M, <sup>2</sup>González-Warleta M, <sup>1</sup>Delgado L, <sup>1</sup>Martínez-Ibeas A, <sup>1</sup>Manga-González M Y

*Instituto de Ganadería de Montaña CSIC-ULE, Dpt de Sanidad Animal, Facultad de Veterinaria, Universidad de León, Campus de Vegazana s/n, 24071 León.*

*2Centro de Investigaciones Agrarias de Mabegondo, 15318 Abegondo, ACoruña  
mcfere@unileon.es*

**Introduction:** The importance of changes caused by the rumen and reticulum trematode parasite *Calicophoron daubneyi* (Digenea: Paramphistomidae) is unclear. Most authors suggest that the adult paramphistomes are relatively warmless. The aim of this work was to characterise the inflammatory cells on rumen and reticulum from cattle naturally infected with *C. daubneyi*.

**Material and Methods:** Samples of rumen and reticulum of 38 calves naturally infected with *C. daubneyi* flukes were examined by histology and immunohistochemistry using antibodies against macrophages (CD68), T-cells (CD3+, CD4+, CD8+) and B cells (CD79).

**Results:** Numerous inflammatory cells were seen in rumen papillae and reticular folds where ventral sucker of parasites was attached. T CD4+ lymphocytes, CD68+ macrophages, eosinophils and globular leukocytes were found in intraepithelial and subepithelial locations. A mixed population of lymphocytes, eosinophils, mast cells and macrophages was present in the reticular and ruminal lamina propria. Most of the cells from lymphoid aggregates and follicles were positive to B marker. CD3+ lymphocytes were mostly CD4+, although sporadic CD8+ were observed.

**Discussion & Conclusion:** In natural conditions adult flukes of *C. daubneyi* have pathogenic effect and may induce a humoral and cell-mediated local immune response in cattle.

**P93- EARLY HEPATIC CHANGES AND IMMUNE RESPONSE IN GOATS VACCINATED WITH A RECOMBINANT GLUTATHIONE TRANSFERASE SIGMA CLASS AND CHALLENGED WITH *Fasciola hepatica***

Zafra R<sup>1</sup>, Pacheco IL<sup>2</sup>, Buffoni L<sup>2</sup>, Escamilla A., Martínez-Moreno A<sup>2</sup>, LaCourse EJ<sup>3</sup>, Brophy PM<sup>3</sup>, Pérez J<sup>2</sup>

*1*University of Las Palmas, Spain, *2*University of Córdoba, Spain, *3*Aberystwyth University, Aberystwyth, UK. [ilpl0510@gmail.com](mailto:ilpl0510@gmail.com)

**Introduction:** The aim of the present work was to study early hepatic changes and local immune response in goats immunized with recombinant GST sigma class and experimentally infected with *F. hepatica*.

**Materials and Methods:** Twenty-seven Malagueña breed goats were divided into 3 groups. Group 1 (n=7) was unimmunized and uninfected; group 2 (n=10) was immunized with adjuvant Quil A and infected; group 3 (n=10) was immunised with rFhGST-S1 and infected. Three goats from each group were killed at 7-9 days post-infection (dpi) to evaluate early changes and immune response by histopathology and immunohistochemistry.

**Results:** In the rFhGST-S1 group two out of three goats showed low hepatic damage at early infection stages. This response was associated to a severe infiltrate of eosinophils in peritoneal fluid and hepatic necrotic foci, high iNOS expression in peritoneal cells and abundant infiltrate of eosinophils surrounding hepatic migrating flukes. CD2, CD4 and CD8 T lymphocyte subsets were found in the vicinity of necrotic areas but they were absent in the vicinity of migrating larvae.

**Discussion & Conclusion:**

Results of the present work suggest that early response mediated by eosinophils play a key role in the effective host response against *F. hepatica* in goats, and it should be considered to better formulate vaccine against this parasite.

**P94- FLOW CYTOMETRY FROM WHOLE BLOOD IN GOATS EXPERIMENTALLY INFECTED WITH *Fasciola hepatica***

*Zafra R<sup>1</sup>, Buffoni L<sup>2</sup>, Martínez-Moreno FJ<sup>2</sup>, Bautista MJ<sup>2</sup>, Escamilla A<sup>2</sup>, Pacheco IL<sup>2</sup>, Pérez J<sup>2</sup> Martínez-Moreno A<sup>2</sup>*

*1University of Las Palmas de Gran Canaria, Spain, 2University of Córdoba, Spain, Email: rafael.zafra@uco.es*

**Introduction:** Fasciolosis caused by *Fasciola hepatica* is an important disease causing important economic losses worldwide and affecting specially ruminants but also humans (zoonosis). The aim of this work was to study lymphocyte subsets (CD4+, CD8+ and WC1+) using flow cytometry from whole blood in order to characterized the immune response in goats experimentally infected with *F. hepatica*.

**Materials and Methods:** Twenty-four Malagueña breed goats were divided into 4 groups of six animals each. Group 1 was immunized with recombinant CL1; group 2 with recombinant GST sigma class; group 3 with the adjuvant Quil A, and group 4 was the uninfected control. Blood samples were collected at: 1) pre-immunisation; 2) 5th week post-infection and 3) 12th week post-infection. Flow cytometry assay was carried out using a COULTER EPICS-XL cytometer.

**Results:** Flow cytometry assay showed at 5th week post infection a significant decreased ( $P=0.012$ ) of CD4+ lymphocytes in vaccinated groups in comparison with group 4 (uninfected and unimmunized). No significant differences were found among the immunized groups.

**Discussion & Conclusion:** To date, this is the first report of flow cytometry from whole blood in ruminants experimentally infected with *Fasciola hepatica*. The decrease in CD4+ cells in 5th week post infection coincide with the migratory stage of the parasite and could explain the lack of effective immune response during this critical period of the infection.

**P95- DISTRIBUTION OF STELLATE CELLS IN SHEEP LIVER WITH PARASITIC FIBROSIS**

*Kukolj Vladimir, Aleksić-Kovačević Sanja, Jovanović Milijan*

*Department of Pathology, Faculty of Veterinary Medicine, University of Belgrade, Belgrade, Serbia, e-mail: vkukolj@vet.bg.ac.rs*

**Introduction:** Increase of extracellular matrix in humans, as well as in animals, occurs as a consequence of hepatic stellate cells (HSCs) activation. The role of these cells in the development of liver fibrosis, which occurs as a consequence of infection *Dicrocoelium dendriticum*, is the subject of this paper. We described the distribution of HSCs which express  $\alpha$ -smooth muscle actin ( $\alpha$ -SMA), desmin and vimentin in the liver of sheep with various degrees of fibrosis.

**Materials and methods:** Formalin-fixed and paraffin-embedded liver samples from 10 sheep, naturally infected with *Dicrocoelium dendriticum*, were examined by light microscopy, using H&E and Masson-trichrom stains and immunohistology for  $\alpha$ -SMA, vimentin and desmin.

**Results:** According to histological criteria, all samples were divided into three groups: the liver of infected sheep without fibrosis/cirrhosis, liver with fibrosis and liver with cirrhosis. Distribution of HSCs is dependent on the degree of liver fibrosis.  $\alpha$ -SMA positive HSCs were most prominent in the perisinusoidal areas. Cells of different shapes and size were positive to  $\alpha$ -SMA immunoreactivity desmin and vimentin. Numerous septal and portal myofibroblasts also stained positive with these antibodies.

**Conclusion:** HSCs play an important role in the synthesis of extracellular matrix components in the development of parasitic fibrosis and cirrhosis in the liver of sheep. Activated HSCs, as well as portal and septal myofibroblasts, correlate to the degree of liver fibrosis.

**P96- PULMONARY HYPERTENSION IN NEW WORLD CAMELIDS (NWC) DUE TO INFECTION WITH LIVER FLUKES.**

*Monika Hilbe<sup>1</sup>, Nadja Robert<sup>2</sup>, Christian Gerspach<sup>3</sup>, Andreas Pospischi<sup>1</sup>*

*1 Institute of Veterinary Pathology, Zurich, Switzerland, 2 Institute of Animal Pathology, Berne, Switzerland\* (\*current adresse: Evole 53, 2000 Neuchatel), 3 Department of Farm Animals, Clinic of Ruminants, Zurich, Switzerland. hilbe@vetpath.uzh.ch*

**Introduction:** Pulmonary hypertension associated with liver parasites is well documented in humans. About 200 million people are infected with parasites belonging to the schistosoma species and about 4.6% to 10% of these suffer from pulmonary arterial hypertension caused by the hepatosplenic form of the disease.

In Switzerland dicrocoeliosis is regarded as the most significant parasitic infection of llamas and alpacas. The aim of this study was to evaluate retrospectively NWC lungs for pulmonary arterial hypertension and pathological liver changes in cases of liver fluke infestation.

**Materials and Methods:** 20 llamas and 20 alpacas with liver fluke infestation were histologically evaluated. In addition to an H&E staining, alpha-smooth muscle actin (alpha-SMA) and a VanGieson (VG)-Elastica stain were used to visualize better the vessel wall structures in the lung tissue.

**Results/Conclusion:** In the H&E staining 9 out of 20 llamas (45%) and 3 out of 20 alpacas (15%) showed severe intimal and adventitial thickening and slight to moderate media thickening, which was confirmed with alpha-SMA and VG-Elastica staining. All animals had liver changes of different degrees, like fibrosis and biliary hyperplasia, which were correlated to the infestation with liver flukes. A correlation between degree of liver fluke infestation, liver damage and hypertensive arterial vessel changes could not be established.

In summary, an infestation of NWC with liver flukes can induce a pulmonary arterial hypertension.

**P97- STRAELENSIOSIS (*Straelensia cynotis*) IN A HUNTING DOG IN PORTUGAL – A CASE REPORT**

*Faisca Pedro<sup>1,3</sup>, Santos Sara<sup>1</sup>; Soeiro Joana<sup>2</sup>; Azevedo Patrícia<sup>2</sup>, Hernandez Cláudio<sup>3</sup>, Carvalho Inês<sup>3</sup>.*

*1- FMV – ULHT, CICV, Lisbon – Portugal. 2- Aristocão. 3- DNAtch, pedrofaisca@ulusofona.pt*

**Introduction:** A male mongrel hunting dog with 2 years old, presented to the veterinarian with a non-pruritic nodular dermatitis affecting the dorsal regions of the head and trunk, accompanied by alopecia and scaly areas.

**Material and Methods:** After unresponsive therapy with systemic ivermectin and oral antibiotic, a biopsy was performed and skin tissues were sampled and processed for histopathology.

**Results:** The epidermis showed marked acanthosis with hyperkeratosis and purulent crusting. Several follicular ostiums were dilated and in each one a rounded to ovoid well preserved larval mite in an amorphous eosinophilic shell were identified. Pseudoepitheliomatous follicular hyperplasia and perifollicular mucinosis was evident. Dermal inflammation was interstitial to perifollicular composed of lymphocytes, plasma cells and mast cells.

**Discussion and conclusion:** The histological findings are consistent with the diagnosis of Straelensiosis. *Straelensia cynotis* is a trombiculid larve mite which resides in hair follicles and is responsible for nodular dermatitis. Foxes are considered to be the natural host for the larval stage, and dog a permissive but occasional host. Straelensiosis has been reported in Southern France and Iberian Peninsula with increasing incidence.

**P98- ENCEPHALITIS IN CANTABRIAN CHAMOIS (*Rupicapra pyrenaica parva*) CAUSED BY A FLAVIVIRUS.**

*Martín-Hernando MP<sup>1</sup>, Balseiro A<sup>2</sup>, Oleaga A<sup>1</sup>, Gortázar C<sup>1</sup>, Ruiz-Fons F<sup>1</sup>*

*1 REC (CSIC – UCLM – JCCM), Ciudad Real, Spain 2 SERIDA, Centro de Biotecnología Animal, Gijón, Asturias, Spain. mpzmartin@gmail.com*

**Introduction:** Three flaviviruses are responsible for cases of encephalitis in domestic bovids in Europe: louping ill virus (LIV), Spanish sheep encephalomyelitis virus (SSEV) and Greek goat encephalitis virus. Only SSEV had been reported in Spain until an outbreak of LIV was recently reported in goats from “Principado de Asturias” in northwestern Spain, but never a case of encephalitis caused by a flavivirus had been reported in a European wild bovid.

**Materials and methods:** Two Cantabrian chamois (*Rupicapra pyrenaica parva*) from Principado de Asturias – one fell down a cliff and the other presented severe clinical nervous signs – were tested by the haemagglutination inhibition assay (HAI) for louping ill virus antibodies. Additionally, tissue samples from different organs including the brain were preserved in 10% buffered formalin and processed routinely.

**Results:** Sera from the two chamois were positive by HAI. Histopathologically, one showed severe necrosis of Purkinje cells and neurons in the cerebellum, the only brain part analyzed. The other animal presented necrosis of Purkinje cells in the cerebellum while the hypothalamus and midbrain showed lymphocytic perivascular cuffs, neuronal degeneration and gliosis. Lesions were more severe in the medulla oblongata.

**Conclusion:** Clinical, serological and histological results point to LIV as the causal agent of encephalitis in the Cantabrian chamois. This would show that LIV may be more widespread in Asturias region than previously thought. Implications for conservation of Cantabrian chamois cannot be ruled out but need to be the focus of future research.

**P99- PROTECTION OF SPANISH IBEX (*Capra pyrenaica*) AGAINST BLUETONGUE VIRUS SEROTYPES 1 AND 8 IN A SUBCLINICAL EXPERIMENTAL INFECTION.**

Lorca-Oró C<sup>1</sup>, Pujols J<sup>1,2</sup>, García-Bocanegra F<sup>3</sup>, Mentaberre G<sup>4</sup>, Granados JE<sup>5,6</sup>, Solanes D<sup>1</sup>, Fandos P<sup>8</sup>, Galindo -Cardiel I<sup>1,7</sup>, Domingo M<sup>1,4</sup>, Lavín S<sup>4</sup>, López-Olvera JR<sup>4</sup>

1 Centre de Recerca en Sanitat Animal (CRESA), Barcelona, Spain. 2 Institut de Recerca i Tecnologia Agroalimentàries (IRTA), Barcelona, Spain. 3 Facultat de Veterinària, UCO, Córdoba, Spain. 4 Universitat Autònoma de Barcelona (UAB), Bellaterra, Spain. 5 Parque Nacional y Parque Natural de Sierra Nevada, Granada, Spain. 6 Agencia de Medio Ambiente y Agua, Granada, Spain. 7 Worldpathol S.L. Zaragoza, Spain.

**Introduction:** Bluetongue virus (BTV) infection causes disease mainly in domestic sheep and cattle but many wild ruminants such as Spanish ibex (*Capra pyrenaica*) are susceptible. Outbreaks related to BTV serotypes 1 (BTV-1) and 8 (BTV-8) have been reported in Europe. Inclusion of wildlife vaccination among BTV control measures should be considered in certain species.

**Material and Methods:** Four out of fifteen seronegative Spanish ibexes were immunized with a single dose of inactivated vaccine against BTV-1 (Syvazul 1[1]), four against BTV-8 (Syvazul 8<sup>1</sup>) and seven ibexes were non-vaccinated controls. Seven ibexes (four vaccinated and three controls) were inoculated with each BTV serotype. RT-PCR virus detection, SNT antibodies and IFN-gamma responses were evaluated until 28 days after inoculation (dpi).

**Results:** The vaccinated ibexes showed significant ( $P < 0.05$ ) neutralizing antibody levels after vaccination compared to non-vaccinated ibexes. The non-vaccinated ibexes remained seronegative until challenge and showed neutralizing antibodies from 7 dpi. BTV RNA was detected in the blood of non-vaccinated ibexes from 2 to the end of the study (28 dpi) and in target tissue samples obtained at necropsy (8 and 28 dpi). BTV-1 was successfully isolated on cell culture from blood and target tissues of non-vaccinated ibexes. Clinical signs were unapparent and no gross lesions were found at necropsy.

**Conclusion:** Our results show for the first time that Spanish ibex is susceptible and asymptomatic to BTV infection and also that a single dose of vaccine prevents viraemia against BTV-1 and BTV-8 replication.



### **P100- LESIONS ASSOCIATED WITH INTRAMUSCULAR VACCINATION AGAINST WEST NILE VIRUS IN RED-LEGGED PARTRIDGES (*Alectoris rufa*)**

*Gamino Virginia*<sup>1</sup>, *Gutiérrez-Guzmán A. Valeria*<sup>1</sup>, *Escribano-Romero Estela*<sup>2</sup>, *Blázquez Ana-Belén*<sup>2</sup>, *Saiz Juan-Carlos*<sup>2</sup>, and *Höfle Ursula*<sup>1</sup>

1. *Instituto de Investigación en Recursos Cinegéticos IREC (CSIC-UCLM-JCCM), Ciudad Real, Spain. Virginia.gamino@uclm.es*, 2. *Departamento de Biotecnología, INIA, Madrid, Spain.*

**Introduction:** Recent flavivirus outbreaks in avian species have shown the potential need of vaccination of birds with economic and/or ecologic value. During the study of the immunogenicity induced by two different vaccines against West Nile virus (WNV) that were being experimentally tested in red-legged partridges (*Alectoris rufa*), we analyzed the macroscopic and microscopic changes produced after intramuscular injection in the pectoral muscle.

**Material and methods:** A commercial inactivated vaccine (Duvaxyn®, Pfizer, Spain) and an E protein based recombinant vaccine candidate with different commercial adjuvants (Stimune® and MetaStim®) were tested. They were applied intramuscularly in the pectoral muscle in two experiments. While local injection volume increased, injection frequency decreased between experiments. During necropsies, pectoral muscle samples were collected for microscopic examination.

**Results:** No mortality or clinical signs were observed related to vaccinations. At necropsy, white or yellowish nodules were seen in the pectoral muscle. Microscopic changes included myofibril degeneration, inflammation and oil cysts (the latter only with the recombinant vaccine). Severity of lesions increased with injection volume and decreased as number of injection sites increased.

**Discussion:** Local reactions with no apparent clinical effect are observed with both vaccines and are modified by vaccine application schemes. The implication of the adjuvants and/or other vaccine components should be studied further.

**P101- ADENOVIRUS INFECTION IN A TURTLE (*Testudo graeca*) RELATED WITH HYPERPLASIC STOMATITIS AND ESOPHAGITIS**

*García-Morante Beatriz*<sup>1</sup>, *Pénzes Judit*<sup>2</sup>, *Costa Taiana*<sup>1</sup>, *Martorell Jaime*<sup>1</sup>, *Ramis Antonio*<sup>1</sup>, *Martínez Jorge*<sup>1</sup>

*1 Universitat Autònoma Barcelona, Bellaterra, Spain. 2 Hungarian Academy of Sciences, Budapest, Hungary*

**Introduction:** Stomatitis and gingivitis is a common clinical problem in chelonians related with herpesvirus, iridovirus and bacterial infections.

**Material and methods:** A 2-year-old female, Mediterranean tortoise (*Testudo graeca*) presented with anorexia of one week of evolution. It belonged to a captive group of 10 turtles of different species. The animal showed low body condition (1/5), stomatitis and weakness. Fecal analysis showed presence of large numbers of nematode eggs. Radiographs were compatible with gastrointestinal obstruction. Pathological studies were performed together with consensus PCRs for virus identification in the DNA extracted from formalin-fixed paraffin-embedded tissues.

**Results:** At necropsy, mucous stomatitis joined with colonic obstruction consisting of dehydrated feces mixed with ascarids was detected. In the histopathology, a severe hyperplasic stomatitis and esophagitis were observed with marked epithelial cytomegaly and enormous basophilic intranuclear inclusion bodies. By electron microscopy, these inclusions corresponded with large number of 60-80 nm, non-enveloped, icosahedral virions arranged in crystalline arrays; which is compatible with adenovirus-like particles. A nested, consensus pan-adenovirus PCR gave positive signals, while herpesvirus, dependovirus and ranavirus could not be detected by corresponding PCRs. Molecular characterization of the detected adenovirus type is being performed.

**Conclusion:** Adenovirus should be included in the differential diagnosis of stomatitis and esophagitis in turtles.

**P102- EPIDEMIC RANAVIRAL DISEASE IN TWO COLLECTIONS OF CAPTIVE POISON DART FROGS.**

*Yumi Une, Tomoo Kudou, Ken-ichi Tamukai, Satoshi Taharaguchi, Masaru Murakami*  
Azabu University; [une@azabu-u.ac.jp](mailto:une@azabu-u.ac.jp)

**Introduction:** Epidemics of ranaviral disease have been found in both free-ranging and captive amphibians in many parts of the world. However, there is only one published case of its occurrence in the Dendrobatidae. The aim of this study was to report the first epidemic of ranaviral disease in poison dart frogs in Japan.

**History:** In February, 2012, an importer (Trader A) imported 12 poison dart frogs from the Netherlands via Canada. These frogs showed onset of disease two or three days after arrival, and all died within a month. All his other frogs that had come into contact with the dead frogs died within the month of April. The total number of dead frogs was forty-eight adults and about 30 juveniles. Trader B imported frogs of three genera from the Netherlands in March, 2012. Onset of disease and death began about the 10th day after importation. Fifty-three adults of five species died in about one month.

**Results:** PCR yielded positive results for ranavirus in dead in the two collections. In gross findings, the liver appeared atrophied and blackish. Necrosis and degeneration in organs was dominant histologically. Inclusion bodies were present in hepatocytes and epithelial cells of the kidneys. Chytrid fungus was not present in the keratinous layer.

**Conclusions:** This is the first report of ranaviral disease in the Dendrobatidae in Japan. These cases were related to animals that had been imported, and, therefore, we deemed it necessary to share the information of this infectious disease internationally.

**P103- HERPESVIRUS ASSOCIATED TO GENITAL LESIONS IN A STRIPED DOLPHIN (*Stenella coeruleoalba*) IN CANARY ISLANDS.**

*Eva Sierra, Manuel Arbelo, Marisa Andrada, Daniele Zucca, Simona Sacchini, Josué Díaz Delgado, Antonio Fernández.*

*Veterinary Histology and Pathology, Department of Morphology, Institute of Animal Health, University of Las Palmas de Gran Canaria. Arucas. Spain  
esierra@becarios.ulpgc.es*

**Introduction:** Herpesviruses in cetaceans have been described in association with encephalitis, skin lesions and fatal disseminated infections.

**Material and Methods:** An adult male striped dolphin (*Stenella coeruleoalba*) stranded at Canary Islands, on 2011, and a complete necropsy was performed. Both formalin-fixed and fresh unfixed samples, for histopathological and microbiological studies, respectively, were taken from selected tissues. Tissue sections for microscopic studies were stained with hematoxylin and eosin.

**Results:** The most remarkable gross finding were the presence of two fleshy masses of approximately 1 cm in diameter, raised, both tan and pigmented, respectively, near the tip of the penis. Histologically, they were composed of hyperplastic epithelial cells with pigmentary incontinence. Ballooning degeneration and margination of chromatin was observed within superficial stratum of the epidermis. Lymphocytes and plasma cells were present at the epidermal-dermal junction. Based on the association of herpesviruses with skin lesions in other marine mammal species, a universal nested Polymerase Chain Reaction (PCR), that amplifies a conserved region within the polymerase gene, was applied. The product of the PCR was electrophoresed in agarose gel. An amplicon of about 215 and 315 bp was obtained (expected size) and sequenced.

**Discussion:** A herpesvirus was associated to the genital lesions in this case.

**P104- RENAL LESIONS IN DEER (*Cervus elaphus*) – *Mycobacterium avium* subsp. *paratuberculosis* INVOLVEMENT**

Matos AC, Figueira L, Martins MH, Matos M, Pires MA, Álvares S, Mendes A, Sousa N, Coelho A, Pinto ML

UTAD-CECAV. Quinta de Prados. Vila Real. Portugal. lpinto@utad.pt

**Introduction:** In Europe, paratuberculosis infection has been described in red deer (*Cervus elaphus*). *Mycobacterium avium* subsp. *paratuberculosis* (MAP) in kidneys was previously reported in cows with advanced paratuberculosis, however it has not been referred in wild deer.

**Material and Methods:** Kidneys from thirty-seven red deer from the centre of Portugal were examined for the presence of MAP by culture, IS900 polymerase chain reaction (PCR) and histopathology. Samples also included intestine and associated lymph nodes in which the same analytical procedures were performed.

**Results:** Lesions found in the kidneys of *Cervus elaphus* were of solitary nature or multifocal, with the exception of one case of interstitial chronic nephritis. Lesions consisted of granulomas, with caseous nature, which varied in size from microscopic to up to 1cm in diameter. Calcification was absent in all the observed cases. Only a small percentage (5.4%) of lesions presented liquefactive necrosis at the center of the granuloma. No *Mycobacteria* were visualized in the organ samples submitted to histopathological examination and bacilloscopy. MAP was cultured from 13.5% kidney samples and MAP PCR identification allowed us to detect 81.1% infected red deer.

**Discussion and Conclusion:** Our results show that granulomatous renal lesions may be associated to MAP infection. Furthermore, we demonstrate that MAP circulates widely among populations of wild cervids in Portugal.

**P105- GRANULOMATOUS LESIONS AND *Mycobacterium avium* subsp. *paratuberculosis* IN PORTUGUESE WILD BOARS (*Sus scrofa*)**

Matos AC, Figueira L, Martins MH, Matos M, Andrade S, Álvares S, Mendes A, Sousa N, Coelho A, Pinto ML

UTAD-CECAV. Quinta de Prados. Vila Real. Portugal. lpinto@utad.pt

**Introduction:** Wild boar (*Sus scrofa*) is considered a vector of mycobacterial infections, but the presence of *Mycobacterium avium* subsp. *paratuberculosis* (MAP) was never assessed in this species in Portugal.

**Materials and Methods:** During the time period of 2009-2011, 589 free-ranging wild boars legally hunted at the Centre of Portugal were examined. The mesenteric lymph nodes of 97 animals were submitted to histopathological examination and tested for the presence of MAP (culture and PCR).

**Results:** Granulomatous lymphadenitis was found in 28 mesenteric lymph nodes, in which the presence of lymphocytes (96.4%) and caseous necrosis (78.6%) were the most common features. Lesions were always multifocal and ranged from occasional proliferative lesions, with less than 1 cm (71.4%) to large areas of granulomatous lesions, more than 1 cm (28.6%) in diameter, of either necrotic or necrotic calcified granulomas. Of the 28 lymph nodes with granulomatous lymphadenitis, 46.4% were either PCR positive or 21.4% culture positive.

**Discussion and Conclusion:** We report the presence of MAP in the mesenteric lymph nodes of wild boars with granulomatous lesions. According to our results, 37.9% of the infected animals were approved for human consumption.

**P106- DIFFUSE LYMPHADENITIS AND DISSEMINATED *Mycobacterium avium* subsp. *paratuberculosis* INFECTION IN TWO WILD EURASIAN OTTERS (*Lutra lutra* L. 1758)**

*Matos AC, Figueira L, Martins MH, Matos M, Pires MA, Álvares S, Mendes A, Sousa N, Coelho A, Pinto ML*

*UTAD-CECAV. Quinta de Prados. Vila Real. Portugal. lpinto@utad.pt*

**Introduction:** Eurasian otters (*Lutra lutra*, L. 1758) are diving mammals of the Mustelidae family, order Carnivora that live almost exclusively in riparian habitats. They can be carriers of mycobacteria, but *Mycobacterium avium* subsp. *paratuberculosis* (MAP) was never referred in these animals.

**Material and Methods:** Two Eurasian otters that were found death in Center region of Portugal were submitted to necropsy. Samples consisting of liver, spleen, kidney, intestine and lymph nodes were collected for histopathology, bacteriological culture and polymerase chain reaction (PCR) analysis.

**Results:** On gross examination, the organs showed no significant alterations, however, microscopically, both animals presented diffuse lymphadenitis with macrophage infiltration and deposition of hyaline material in the center of the lymphoid follicles. The presence of MAP was confirmed by isolation in bacteriological culture and detected by molecular methods in multiple organs of both animals.

**Discussion and Conclusion:** The occurrence of paratuberculosis infection has been well documented in nonruminant wildlife, but in wild carnivores the studies about MAP infection are scarce. Herein we confirm that Eurasian otters can be a carrier of mycobacteria, specifically of MAP, which, to the best of our knowledge, was never described before.

**P107- TUBERCULOSIS-NEGATIVE GRANULOMATOUS INFLAMMATION IN THE LUNG AND LYMPH NODES OF THE ELK (*Cervus elaphus*)**

*Soon-Seek Yoon, Kyung-Hyun Lee, In-Soon Roh, Oun-Kyong Moon, Young-Hwa Jean, Jae-Won Byun, Myoung-Heon Lee*

*Animal Disease Diagnosis Division, Animal, Plant and Fisheries Quarantine and Inspection Agency, South Korea, yoonss24@korea.kr*

**Introduction:** The outbreak of tuberculosis in Cervid has dramatically increased (103 cases in 2011) in Korea since 2002. When granuloma in necropsy and histopathology is detected, we do two tests to diagnose tuberculosis (Acid-fast stain, PCR). However, all test negative results were detected in four elks.

**Materials and Methods:** Nine elks (1 to 6-year-old) showed downer animal syndrome in Pocheon area in Korea in 2012. Ziehl-Nelson stain was done to detect acid-fast bacteria for the granulomatous tissues. PCR was also performed to detect IS6110 and IS1081 genes of *Mycobacterium spp.*

**Results:** Granulomatous lesions were detected in 4 animals (4 to 6-year-old) grossly and histopathologically. Lesions were detected in the lung (1 animal), lymph node (LN, 1 animal), and lung and LN (2 animals). PCR test and Acid-fast staining was also negative in lesion tissues of the lung and LN of 4 elk.

**Discussion and Conclusion:** Dower animal syndrome occurred in ruminant farms in Pocheon area including this elk farm was declared the botulism. We haphazardly detected the granulomatous inflammatory lesions in 4 animals out of 9 animals in one farm. However, we could not make a diagnosis with tuberculosis finally due to negative results in the special staining and PCR.



**P108- MYCOBACTERIOSIS IN OSTRICHES (*Struthio camelus*).**

*Kelly Pamela*<sup>1</sup>, *Jahns Hanne*<sup>1</sup>, *Power Eugene*<sup>2</sup>, *Kenny Kevin*<sup>2</sup>, *Corpa Juan M*<sup>3</sup>, *Callanan John J*<sup>1</sup>.

*1University College Dublin, Dublin, Ireland, 2Central Veterinary Research Laboratory, Kildare, Ireland., 3Universidad CEU Cardenal Herrera, Valencia, Spain., Email: Pamela.kelly@ucd.ie*

**Introduction:** Avian tuberculosis rarely affects ratides compared to other bird species and only single case reports on the disease caused by *Mycobacterium avium* have been published in ostriches. This study describes the pathological and microbiological findings in three adult ostriches with mycobacteriosis.

**Materials and Methods:** Post-mortem examinations were carried out on ostriches from two different zoological collections. Collected tissues were stained with hematoxylin and eosin, ziehl neelsen, gram, PAS and congo red. Large granulomas and lymph nodes were submitted for mycobacterial culture and spoligotyping.

**Results:** All cases presented with multifocal caseous granulomas affecting the spleen, liver and mesentery. Large numbers of acid fast bacilli were present in the granulomas in two cases. Two had multifocal granulomas throughout the intestines from which *Mycobacterium* spp. members of the *mycobacterium avium* complex were isolated. *M. bovis* spoligotype SB0140 was cultured in the third case.

**Discussion:** This represents the first reported case of *M. bovis* in an ostrich. Avian tuberculosis due to *M. bovis* is rare and to date has only been reported in parrots and experimentally inoculated birds. *M. bovis* needs to be considered as a possible cause of tuberculosis in ostriches as it causes lesions similar to the ones observed with MAC infection.

**P109- SUBCUTANEOUS MYCOBACTERIOSIS WITH SYSTEMIC AMYLOIDOSIS IN A DOMESTIC PIGEON (*Columba livia domestica*)**

*Nouri M., Azarabad H., Madani A., Kamyabi Z., Moini M*

*Department of Pathology, Faculty of Veterinary Medicine, the University of Tehran, Tehran, Iran.*

**Introduction:** Avian mycobacteriosis is an important disease in birds. Amyloidosis is a rare disease and there are a few reports of natural amyloidosis in avian. Cutaneous mycobacteriosis infections are almost unknown in Columbiformes. The present report describes the clinical, radiological and pathological features of a pigeon with subcutaneous mycobacteriosis and systemic amyloidosis.

**Materials and Methods:** A male pigeon was presented with a history of the presence of a mass in the dorsolumbar area and weight loss. Two perpendicular standard avian radiographs were taken from the case. Because of the poor prognosis a complete necropsy was performed. Collected organs were preserved in 7.2 % buffered formalin. Microscopic sections were prepared and stained with hematoxylin&eosin, Congo red, PAS and Ziehl-Neelsen staining.

**Results:** At necropsy, a discrete mass (30×25 mm) was removed from the subcutaneous tissue of the dorsolumbar area. One yellowish-white granuloma was found in the intestinal serosa. The liver was enlarged with greenish discoloration. The kidney appeared pale and enlarged. The testes were asymmetric. Histopathologically, multiple foci of chronic inflammation were seen in subcutis and intestinal serosa. ZN Staining showed numerous acid-fast bacilli. In hepatic, renal and spleen tissues amyloid materials were deposited and with Congo red staining systemic amyloidosis was confirmed.

**Discussion and Conclusion:** This clinical case is unusual because of the high resistance of pigeons to Mycobacterium infection. As far as we know, it is the first time that granulomatous dermatitis has been described in pigeon.

**P110- GRANULOMATOUS SYSTEMIC INFECTION ASSOCIATED WITH *Rhodococcus sp.* IN POISON DART FROGS.**

David Hugo<sup>1,2</sup>, Marques Pereira Nuno<sup>2</sup>, Albuquerque Teresa<sup>3</sup>, Faisca Pedro<sup>1</sup>

1 FMV- ULHT, CICV, Lisbon – Portugal. 2 Oceanário de Lisboa. 3 LNIV  
pedrofaisca@ulusofona.pt

**Introduction:** Between June and July 2011, six poison dart frogs (*Dendrobates auratus*) died in quarantine in a zoological park. All animals presented as clinical signs: lethargy, anorexia, cutaneous ulcerations and an obvious increase of the coelomic cavity volume. After the death of the first three animals, Enrofloxacin (Baytril® 10 mg/kg SID) was initiated by topical/percutaneous absorption. The last surviving animal was euthanized due to humanitarian reasons.

**Material and Methods:** At necropsy, multifocal, elevated whitish nodules of different sizes were observed in the spleen, liver and gonads. Intracoelomic organs were sampled and processed for histopathology.

**Results:** Several granulomas were observed in lungs, liver and gonads, presenting a multifocal distribution. These consisted mainly of macrophages and heterophils with central necrosis in larger granulomas. The digestive tract, heart and kidneys showed no abnormalities. Periodic acid schiff and Ziehl-Neelsen (ZN) staining were performed. The PAS was negative, but several intracellular filamentous bacteria stained positive with ZN. A sample from the described nodules was submitted for Mycobacterial culture. The result came back negative, but in that same growth medium *Rhodococcus sp.* was isolated.

**Discussion and Conclusion:** The final diagnosis was multi-organ chronic granulomatous infection by *Rhodococcus sp.* To the author's knowledge this is the first case of an infection by *Rhodococcus sp.* in an amphibian.

**P111- NECROTIC LARYNGITIS OF EUROPEAN BISON (*Bison bonasus*) FROM BIAŁOWIEŻA FOREST**

*Osińska Barbara, Bielecki Wojciech, Rzewuska Magdalena*

*Warsaw University of Life Science-SGGW, Warsaw, Poland, osinskab@op.pl*

**Introduction:** The research material was the first case of necrotic laryngitis of 914 European bison from Białowieża Forest which were investigated post mortem.

**Materials and methods:** A male European bison at the age of 6 years from Białowieża Forest was examined post mortem. The samples were collected for the histological and bacteriological investigation.

**Results:** The anatomopathological examination revealed that necrotic lesions and focal haemorrhages in the larynx and in two first rings of the trachea were observed without lesion in the skin of this area. Verminal pulmonitis, fascioliasis hepatitis and nephritis were also noticed. The larynx microscopic investigation showed infiltrations of mononuclear cells with neutrophils, eosinophils and large cells. Epithelial and cartilage necrosis and damage were also observed. The bacteriological examination allowed the isolation of *Trueperella* (*Arcanobacterium*) *pyogenes* and *Pasteurella multocida*. The obligate anaerobes in the culture were absent.

**Conclusion:** The lesions of the larynx were probably caused by the attack of another bison. As the bison's skin is very thick and injury resistant, there is huge possibility that despite of serious internal damages there will be no injury marks on the bison's body.

The study was supported by the National Centre for Science, Poland, grant Nr: N N308 573340

**P113- ULCERATIVE ENTERITIS-LIKE DISEASE ASSOCIATED WITH CLOSTRIDIUM BEIJERINCKII/BUTYRICUM IN A PIGEON (*Columba livia*)**

*Bolfa P, Tabaran F, Niculae M, Borza G, Gal A, Bouari C, Taulescu M, Nagy A, Farcas L, Vidrighinescu R, Catoi C*

*Pathology Department, University of Agricultural Sciences and Veterinary Medicine, Cluj-Napoca, Romania, email:pompeibolfa@gmail.com*

**Introduction:** Ulcerative enteritis is a severe bacterial disease induced by *Clostridium colinum* that affects various bird species including pigeons. Bacteria from the *Clostridium butyricum-beijerinckii* group have not been associated with intestinal pathology in pigeons.

**Materials and Methods:** A 7 month old pigeon was brought dead to the Pathology Department, following chronic weight loss and diarrhea, from a group of 37 pigeons. We performed a necropsy, followed by cytological, histopathological, bacterioscopic, and bacteriological exams.

**Results:** Gross postmortem lesions included emaciation, pectoral muscle atrophy and lesions mainly confined to the intestine (lower jejunum and ileon). There were discrete or confluent, round to oval, multifocal irregularly shaped ulcers filled with necrotic debris (2-4 mm in diameter). Histologically there was severe ulceration, an important inflammatory infiltrate composed mainly of heterophils and rare mononuclear cells, associated with many colonies of gram positive rods and reepithelization. Predominantly bacteria with a morphology corresponding to *Clostridium* spp., was seen in gram-stained smears of the intestinal lesions. Anaerobic cultures followed by API 20 A gallery suggested a diagnose of *Clostridium beijerinckii/butyricum* infection (99.9%).

**Discussion & Conclusion:** To our knowledge this is the first link between an ulcerative enteritis and bacteria from the *Clostridium butyricum-beijerinckii* group in pigeons.

**P114- HEMORRHAGIC-NECROTIZING COLITIS ASSOCIATED TO CAMPYLOBACTER JEJUNI AND BALANTIDIUM COLI IN A ZOO GORILLA.**

*Isidoro Marc<sup>1</sup>, Martínez Jorge<sup>1</sup>, Almagro, Ramis, Antonio<sup>1,2</sup>*

*1. Departament de Sanitat i Anatomia Animals. F.Veterinària. UAB. 2. Centre de Recerca en Sanitat Animal (CReSA). UAB.*

**Introduction:** Hemorrhagic-necrotizing colitis is a possible cause of death in different species of apes kept in captivity.

**Material and methods:** A 32- year-old female, Western Gorilla (*Gorilla gorilla*) kept in captivity at the Zoo of Barcelona presented depression and moderate hemorrhagic diarrhea that led it to death in 15 days. *Campylobacter jejuni* was isolated after the onset of the process but antibiotherapy was unsuccessful. A postmortem pathological study was performed in order to characterize the definitive cause of death.

**Results:** At necropsy, focally extensive necrotizing colitis was observed along with a mild fibrinous peritonitis. In the histopathology, the mucosa was completely substituted by an extensive amount of necrotic debris, blood, fibrin, bacteria and large amounts of ciliated protozoa morphologically compatible with *Ballantidium coli*. A transmural, chronic and severe inflammatory infiltrate was also present. The serosa showed granulation tissue, fibrin and a mixed inflammatory infiltrate.

**Conclusion:** *Ballantidium coli* is considered an opportunistic agent, but there are evidences that it may be a primary pathogen in great apes. On the other hand, *Campylobacter jejuni* has been associated to mild erosive-ulcerative and hemorrhagic colitis in different species of primates. A synergic interaction between both agents could be the cause of the fatal necrotizing colitis in this case.

**P115- PULMONARY LESIONS CONSISTENT WITH DISSEMINATED ADIASPIROMYCOSIS IN EGYPTIAN MONGOOSES (*Herpestes ichneumon*) FROM PORTUGAL**

*Matos AC, Figueira L, Martins MH, Matos M, Pires MA, Coelho A, Pinto ML*

*UTAD – CECAV. Quinta de Prados. Vila Real. Portugal. lpinto@utad.pt*

**Introduction:** The Egyptian mongoose (*Herpestes ichneumon*), is a small terrestrial carnivore from the Viverridae family. Adiaspiromycosis, caused by dimorphic fungus of the genus *Emmonsia*, is primarily a respiratory disease, rare in humans, which affects small mammals, especially members of the families Rodentia, Carnivora and Mustelidae.

**Materials and Methods:** Eight Egyptian mongooses, killed by hit-and stock control of predators in the Centre-western Portugal during the period of 2010-2011 were subjected to necropsy and histopathological examination.

**Results:** Gross pathological examination of lungs at post mortem revealed focal lesions in 3 animals. The lesions were widely distributed, whitish/cream, and most were 0.5–3 mm diameter. At microscopy, the lungs from 2 animals showed cystic structures consistent with visible intact adiaspores composed of a central thick walled, PAS positive, spore surrounded by macrophages and eosinophils or by typical granulomatous lesion. These animals also showed granulomas of parasitic origin. One animal exhibited only adiaspores and abundant foamy macrophages. The lungs from all of the animals affected also displayed hemorrhagic lesions.

**Discussion and Conclusion:** This is the first report of pulmonary lesions consistent with adiaspiromycosis in Egyptian mongooses from Portugal.

**P116- TOXOPLASMOSIS IN AUSTRALIAN MARSUPIALS IN CAPTIVITY**

*Cedillo C<sup>1,2</sup>, Rangel IC<sup>3</sup>, Espinosa D<sup>4</sup>, Salas G<sup>5</sup>, Rico CP<sup>2</sup>, López O<sup>3</sup>, Díaz M<sup>3</sup>, Correa D<sup>2</sup>.*

*1. Est. de Posgrado, FMVZ, UNAM, México; 2. Instituto Nacional de Pediatría, SSA, México; 3. DGZVS, Gobierno del Distrito Federal, México; 4. Zoológico de Guadalajara, México; 5. Depto. de Patología, FMVZ, UNAM, México.  
mvzcarloscedillo@hotmail.com*

**Introduction:** Australian marsupials are hosts with high susceptibility to *Toxoplasma gondii* infection, since there are documented clinical cases and outbreaks of acute disease. However, infection in marsupials is not always fatal and can favor development of chronic infection.

**Materials and Methods:** 18 cases were evaluated, they were processed by routine histopathology, IHC, PCR and PCR-RFLP.

**Results:** In three cases of necropsy, there were no lesions compatible with toxoplasmosis and the animals died of other causes. Necrotic lesions with inflammatory infiltrates and parasitic structures (*T. gondii* tachyzoites or tissue cysts) were observed microscopically in various tissues, confirmed by IHC in 12 cases. Eleven of 18 cases were positive by PCR. PCR-RFLP analysis showed genotypes in the tissues tested of 9 cases.

**Discussion and Conclusion:** Lesions in respiratory, digestive and lymphoid systems were severe, consistent with an acute course. In heart and nervous system, lesions were mild to moderate, with or without tissue cysts, suggesting a chronic course. For PCR, 11 cases were positive. The results by PCR-RFLP, indicating the presence of I and atypical genotypes involved, being different to those described in the literature



## **P117- THE OCCURRENCE EIMERIAN SPECIES AND HISTOPATHOLOGICAL LESIONS OF EUROPEAN BISON IN POLAND**

*Pyziel AnnaMaria<sup>2</sup>, Osińska Barbara<sup>1</sup>, Demiaszkiewicz Aleksander W.<sup>2</sup>*

*1Warsaw University of Life Science-SGGW, Warsaw, Poland, 2Polish Academy of Sciences, W. Stefański Institute of Parasitology, Warsaw, Poland, osinskab@op.pl*

**Introduction:** In the existing literature the occurrence of *Eimeria bovis* (*E. bovis*), *E. bukidnonensis*, *E. canadensis*, *E. ellipsoidalis*, *E. zuernii* from European bison has already been described.

**Material and Methods:** The number of 424 specimens of faeces from free-living and breeding centres European bison at the age of 3 month-26 years were collected for the parasitological investigation. The samples of small and large intestine from culled bison were also collected for the histopathological investigation.

**Results:** The 11 species of oocysts of *Eimeria* were observed in the faeces of European bison. Except these described in the literature there are also: *E. alabamensis*, *E. auburnensis*, *E. brasiliensis*, *E. cylindrical*, *E. pellita*, *E. subspherica*. The overall prevalence of *Eimeria* spp. reached 33,5%. The Oocyst Count Per Gram (OPG) varied from 50 to 6550. The microscopic examination revealed presence of gamonts and inflammatory cells with eosinophils.

**Conclusion:** The diversity of eimerian species, as well as the prevalence of invasion, and the value of OPG in calves and breeding bison were remarkably higher than in mature free-living ones. The mature gamonts of eimerians were diagnosed only in the intestinal cells of bison that shed coccidian oocyst in their faeces.

The study was partially supported by National Centre for Science, Poland, grant Nr: N N308 573340

**P118- A CASE OF *Dirofilaria immitis* IN A EURASIAN OTTER (*Lutra lutra*)**

Saraiva AL<sup>1</sup>, Sousa S<sup>1</sup>, Silva J<sup>2</sup>, Andrade S<sup>1</sup>, Botelho N<sup>1</sup>, Canavarro I<sup>1</sup>, Costa M<sup>1</sup>, Ferreira F<sup>1</sup>, Meier K<sup>1</sup>, Silva JA<sup>1</sup>, Tiago J<sup>1</sup>, Kanoun-Boulé M<sup>1</sup>

*1*IEUVG – Escola Universitária Vasco da Gama, Coimbra, Portugal, [analaorasaraiva@gmail.com](mailto:analaorasaraiva@gmail.com), *2*ICNB – Institute for Nature Conservation and Biodiversity, Coimbra, Portugal

**Introduction:** *Dirofilaria immitis* infection is an endemic disease in Portugal, with dogs being the main reservoir. This work reports a case of dirofilariasis in a eurasian otter recovered at the river bank of Mondego in Coimbra, Portugal.

**Materials and Methods:** An adult otter male was rescued and brought into a wildlife recovery centre (ICNB) where it survived for a few hours. Necropsy was performed under standard protocol during an anatomical pathology lesson. Collected parasites were placed in ethanol and identified under magnification.

**Results :** After removing thoracic organs as a main block, heart dissection was performed. When the major vessels were cut, a plug of filiform parasites was expelled through the pulmonary artery. Other similar parasites were present at the right cardiac chambers and pulmonary artery branches. Additionally, the cardiac silhouette was rounder than normal, with flaccid walls. On parasitological exam, four females of *Dirofilaria immitis* were identified.

**Discussion and Conclusion:** To our knowledge, this is the first report of *Dirofilaria immitis* in an otter from the central region of Portugal. Since this is a heartworm endemic area, keeping otter's population on prevention may be of utmost importance.

## P119- IMMUNOPATHOLOGICAL STUDY OF PARASITIC CHOLANGITIS IN DOLPHINS

*Jaber JR<sup>1</sup>, Pérez J<sup>2</sup>, Zafra R<sup>2</sup>, Suárez-Bonnet A<sup>1</sup>, Quesada O<sup>1</sup>, Fernández A<sup>1</sup>*

*Institute of Animal Health, University of Las Palmas de Gran Canaria, Spain, 2  
Department of Comparative Pathology, Veterinary Faculty, University of Córdoba.  
jjaber@dmor.ulpgc.es*

**Introduction:** *Campula* sp. is a common trematode that inhabits the bile of cetaceans. Heavy infestations may produce biliary hyperplasia, portal fibrosis and an inflammatory infiltrate of lymphocytes, plasma cells and eosinophils. Our purpose was to examine the distribution of CD3<sup>+</sup> T lymphocytes, IgG bearing plasma cells, macrophages, MHC class II antigen and S-100 protein in chronic cholangitis produced by *Campula* sp.

**Material and Methods:** Several stranded cetaceans were included in the study. Three samples from each liver were processed for histological examination. Mesenteric lymph nodes were used as control tissues for immunohistochemical examination.

**Results:** *Campula* sp. was seen in the bile ducts producing severe damage and eliciting a focal suppurative cholangitis, severe necrotizing cholangitis, or chronic granulomatous cholangitis. In chronic parasite cholangitis, granulomata associated to parasite eggs showed numerous lysozyme<sup>+</sup> and MHC class II<sup>+</sup> macrophages. The anti-S100 reacted with lymphocytes of these areas. The anti-S-100 reacted with the nucleus and cytoplasm of lymphocytes and with dendritic-like cells that were also strongly immunoreactive with the anti-MHC class II. In fibrotic areas, a variable number of CD3<sup>+</sup> T cells was found, with few lysozyme<sup>+</sup> and MHC class II<sup>+</sup> macrophages.

**Discussion & Conclusion:** The series presented in this work showed an infiltrate similar in nature to that reported in parasite cholangitis of other species, which contained dendritic-like cells. The presence of stellate cells suggested that these are highly organized structures developed to enhance antigen presentation to B and T cells.

## **P120- BILIARY CIRRHOSIS CAUSED BY CAMPULA SPP IN DOLPHINS: AN IMMUNOHISTOCHEMICAL AND PATHOLOGICAL STUDY**

*Jaber JR<sup>1</sup>, Rotstein D<sup>2</sup>, Pérez J<sup>3</sup>, Zafra R<sup>3</sup>, Suárez-Bonnet A<sup>1</sup>, Quesada OI, Fernández A<sup>1</sup>*

*1Institute of Animal Health, University of Las Palmas de Gran Canaria, Spain, jjaber@dmor.ulpgc.es; 2 Department of Medicine, Medical University of South Carolina, USA. 3Department of Comparative Pathology, Veterinary Faculty, University of Córdoba.*

**Introduction:** In humans, chronic obstruction of the intrahepatic biliary duct may result in primary biliary cirrhosis (PBC). In terrestrial mammals, it has been experimentally induced by surgery, antifungal drugs, as well associated to parasites. This work reports PBC produced by *Campula* spp. in dolphins.

**Material and Methods:** One striped dolphin and six harbor porpoises were studied. They showed the presence of numerous hard and whitish nodules ranging 2 to 3 cm in diameter, affecting approximately half of the liver and associated to marked dilatation of the hepatic ducts.

**Results:** The hepatic lesions consisted on severe proliferation of fibrous connective tissue with loss of the lobular pattern, nodular regeneration of the hepatic tissue and bile duct hyperplasia; they were associated with *Campula* spp. Around these areas, there was an abundant inflammatory infiltrate organised in lymphoid follicles. The cellular distribution in these hepatic lymphonodular lesions associated to parasitic cholangitis was closely similar to that found in the cortex of control lymph nodes, including the presence of S100+ and MHC class II+ dendritic like cells in lymphoid follicles and interfollicular areas.

**Discussion & Conclusion:** Although inflammatory and degenerative hepatic lesions are frequently found in stranded dolphins, PBC has not been previously reported in cetaceans. Massive infestation by this parasite should be included as cause of hepatic failure resulting of stranding in marine mammals.

**P121- INCREASED MORTALITY IN RED FOXES (*Vulpes vulpes*) IN SLOVENIA – PRELIMINARY STUDY RESULTS**

*Juntes Polona, Vengušt Gorazd, Žele Diana, Hostnik Peter, Paller Tomislav, Milan Pogačnik*

*University of Ljubljana, Veterinary Faculty, Ljubljana, Slovenia,  
polona.juntes@vf.uni-lj.si*

**Introduction:** Red fox (*Vulpes vulpes*) is a common wild carnivore living in Slovenia. Their number has been growing constantly after introduction of oral vaccination against rabies, but since last year, increased mortality rate has been observed by hunters. Preliminary study was carried out in order to determine possible causes.

**Materials and methods:** Nine foxes were selected for necropsy randomly from the pool of foxes that were killed by hunters or found dead in the field and collected for the purpose of rabies testing. Internal organs were examined by histopathology and bacteriology, immunohistochemistry (IHC) was made for the presence of canine distemper virus (CDV), *Toxoplasma gondii* and *Neospora caninum*.

**Results:** All examined foxes were negative for rabies. Necropsy and histopathology results revealed pneumonia or bronchopneumonia in 8/9 animals (3 with protozoan organisms) and encephalitis or meningoencephalitis in 4/8 (3 with protozoal organisms in inflammatory lesions). IHC confirmed the presence of distemper virus infection in 8/9 animals, *Neospora caninum* was negative in all cases, while results for *Toxoplasma gondii* were inconclusive.

**Discussion and conclusions:** Preliminary results obtained in this study suggests that causes for the increased mortality and decline in population of red foxes could be in many cases attributed to the epidemic of distemper in combination with protozoal infections. Further follow up is essential to obtain definite conclusions.

**P122- PIGMENTARY NEURODEGENERATIVE DISEASE IN MACROPODS EXPOSED TO *Phalaris tuberosa***

*Bacci Barbara, Ceccolini Mary, Whiteley Pam*

*Faculty of Veterinary Science, University of Melbourne. bbacci@unimelb.edu.au*

**Introduction:** *Phalaris tuberosa* is a winter-active perennial grass that is widely grown in pastures in south-eastern Australia. *Phalaris* contains several dimethylated tryptamine alkaloids that can be toxic to ruminants; the alkaloid content varies with the pasture's stage of growth. Young, vigorously growing *phalaris* is more likely to be toxic. Two Eastern Gray kangaroos (*Macropus giganteus*) near Seymour (Victoria) with neurological signs characterized by incoordination and ataxia were submitted for necropsy examination. Additional samples collected from Western Gray kangaroos (*Macropus fuliginosus*) and Wallabies (*Macropus eugenii*) grazing *Phalaris*-dominant swards in Kangaroo Island (Western Australia) were reviewed for comparison.

**Materials and methods:** Tissues were processed and stained with Haematoxylin and Eosin. Additionally sections were stained with PAS and Fontana-Masson. Gas chromatography-mass spectrometry analysis was performed in order to identify the pigment stored within neurons.

**Results:** At necropsy there was a prominent grayish discolouration of the gray matter throughout the cerebrospinal axis. Histologically there was accumulation of abundant brown granular pigment in neurons of brain cortex, thalamic nuclei and spinal cord. Lesser amounts of pigment were also present in the cerebellum and hippocampus. Pigment was negative for PAS stain and positive for Fontana-Masson.

**Discussion:** The neurological signs in free ranging macropods and the typical histological findings are consistent with *Phalaris* toxicity.

## **P123- MULTIPLE MALFORMATIONS IN NON-RELATED CAPTIVE LIONS (*Panthera leo*)**

*Negrini J<sup>1</sup>, Guerra R<sup>2</sup>, Ruiz J<sup>2</sup>, Novales M<sup>3</sup>, Blanco B<sup>3</sup>, Diz A<sup>1</sup>, Guil S<sup>1</sup>, Mozos E<sup>1</sup>.*

*1 Department of Anatomy and Comparative Pathology. 2 Zoological Garden of Córdoba. Dpto. of Medicine and Surgery. Ed. Sanidad Animal, Campus de Rabanale. Crtra Madrid-Cádiz. Córdoba. Spain anlmomoe@uco.es*

**Introduction:** Reports of malformations in captive wild felids are relatively uncommon and these are mostly regarding the Arnold-Chiari syndrome in lions. In this work we report congenital malformations involving the head, trachea, liver and skin in a pride of lions non-paternally blood related.

**Material and Method:** Five African lions born from the same parents died during the last two years. Four were stillborn or newborn and 1 still alive 18 months; this animal developed different neurological signs as ataxia, tremors, strabism, and laryngeal stridor and died by tracheal collapse after food regurgitation. Haematological analysis was normal. Simple radiography, computer tomography, necropsies and histopathological study were performed.

**Results:** At necropsy, the lioness stillborn and newborn showed different head anomalies (acrania, anencephalia, gnathoschisis or palatoschisis), as well as tracheal cartilage and hepatic vascular hypoplasia; in the juvenile lion, the main lesions were both tracheal cartilages and cerebellar hypoplasia. Clinical and pathological features were consistent with vitamin A deficiency.

**Discussion and conclusion:** The cause of these malformations still unclear, nonetheless the high incidence in these non-consanguineous lions, suggest that environmental traits could be involved. Thus, because the higher and special dietary requirement for vitamin A in felids, and the multiple cases in which suspected or confirmed hypovitaminosis A have been reported, it should be routinely investigate.

**P124- MULTISEPTATE GALLBLADDER IN AN AFRICAN LIONESS  
(Panthera leo)**

*García-González Beatriz, Cuesta-García Nerea*

*Veterinary Diagnostic Services, University of Glasgow, Glasgow, UK beatriz.garciagonzalez@glasgow.ac.uk*

**Introduction:** Multiseptate gallbladder is a rare congenital malformation described in human beings. It is characterized by multiple septa dividing the gallbladder lumen into several chambers. This anomaly is frequently associated with right upper quadrant pain suggestive of cholecystitis, although coexistence with cholelithiasis has seldom been reported. Cholecystectomy is curative.

**Materials and Methods:** A 12 year African lioness was presented for post-mortem examination with a 2 month history of reluctance to move and discomfort. A complete necropsy was performed and samples of selected tissues were fixed in 10% buffered formalin and routinely processed for histologic examination.

**Results:** On gross examination, the lioness had icteric mucous membranes and mild abdominal distension. The liver was enlarged and the gallbladder was tortuous. Upon opening the gallbladder, the lumen was divided by thin septa into multiple chambers, adopting a honeycomb appearance. The bile content was inspissated, but no gallstones were seen. Histologic findings showed multiple sacculations separated by septa of loose fibrovascular and adipose tissue. These sacculations had intercommunicating openings and pouch-like endings. There was a mild hyperplasia of mucus-secreting mucosal glands, as well as formation of mucus-filled cysts. Neither thickening of the gallbladder wall nor inflammatory infiltrates were detected.

**Conclusion:** To our knowledge, this is the first description of this gallbladder malformation in animals. It shares many similarities with its human counterpart and the name multiseptate gallbladder is proposed. A congenital origin is suspected.



## **P125- THE ALOPECIA-SYNDROME OF SPECTACLED BEARS (*Tremarctos ornatus*) – WHAT DO WE KNOW, WHAT CAN WE DO?**

*Jäger, Kathrin<sup>1</sup>, Langguth, Sandra<sup>2</sup>, Einspanier, Almuth<sup>3</sup>, Schachtner, Martina<sup>2</sup>,  
Bechstein, Nadine<sup>3</sup>, Schoon, Heinz-Adolf<sup>1</sup>*

*1Institute of Veterinary Pathology, Leipzig, Germany, 2Zoo Leipzig  
corporation, Germany, 3Institute of Physiological Chemistry, Leipzig, Germany.  
jaeger.kathrin@vetmed.uni-leipzig.de*

**Introduction:** The Spectacled bear (*Tremarctos ornatus*) is the last remaining short-faced bear native to South America. Animals are kept in zoos worldwide, where for the last 40 years, especially in female bears, severe skin disorders have been observed. These do not respond to various therapeutic strategies.

**Materials and Methods:** Ninety-six skin biopsies of female bears with different stages of hair loss were examined histopathologically with H.-E.-staining and PAS-reaction. The animals were kept in different zoological gardens in Europe, their age ranged from 9.5 to 31 years.

**Results:** Clinically, the animals show progredient alopecia, aggravating pruritus, seborrhoea sicca and lichenification of the skin with histopathologically telogenic or atrophic hair follicles, perifollicular fibrosis and a severe yeast infection. Furthermore, a perivascular dermatitis, consisting of mast cells, eosinophils and lymphocytes is diagnosed.

**Discussion:** The results show the following problem complexes: 1. The Alopecia, for which all examinations do not point to a specific cause, e.g. endocrinopathy or autoimmune disease, 2. The perivascular dermatitis, that indicates an allergic skin disorder and 3. The severe yeast infection in multiple animals, that most likely developed as secondary dermatophytosis to the underlying alopecia and inflammatory alterations. Genetic and social causes have to be excluded in further research work.

## **P126- CELLULAR IMMUNOPHENOTYPICAL CHARACTERISTICS IN A CASE OF EXTRAMEDULLARY HEMATOPOIESIS IN A GOELDI'S MONKEY (*Callimico goeldii*)**

*Noiva R, Pissarra H, Fernandes T, Bernardino R, Peleteiro C*

*Interdisciplinary Research Centre on Animal Health, (CIISA/FMV/UTL), Portugal, rute.noiva@gmail.com*

**Introduction:** The current work aims at reporting a case of extramedullary hematopoiesis in a Goeldi's monkey (*Callimico goeldii*) that was considered a good opportunity to evaluate the immunohistochemical phenotype of the cells involved.

**Materials and Methods:** A 9-year-old male Goeldi's monkey (*Callimico goeldii*) (zoological collection) was evaluated due to loss of body condition and prostration. An intra-abdominal 4 cm nodule was detected by ultrasound, that surgery revealed to be attached to the abdominal aorta. Unfortunately, the animal did not survive surgery.

**Results:** At necropsy, the liver exhibited yellowish foci and nodules, and the spleen appeared diffusely enlarged. Most liver lesions corresponded to infiltration by hematopoietic precursor cells and multiple granulomas containing *Calodium hepaticum* eggs and adults. Splenomegaly was also due to infiltration by hematopoietic precursor cells. The abdominal mass was a large mycotic granuloma. Immunostaining for specific myeloid and lymphoid markers (CD3, Pax5 Macrophages/Monocytes, Myeloperoxidase, CD10, CD20cy, light  $\lambda$ -chains and CD117) revealed that the cells infiltrating both liver and spleen was heterogenous and compatible with hepatosplenic extramedullary hematopoiesis. The most commonly expressed markers were Macrophage/Monocytes, Myeloperoxidase and CD3, followed by Pax5 and CD20 and, less commonly, CD10 and light  $\lambda$ -chains. CD117 was persistently negative.

**Discussion & Conclusion:** In this case of extramedullary hematopoiesis in a Goeldi's monkey, immunohistochemistry positive for myeloperoxidase successfully contributed for the diagnosis.

**P127- DECOMPRESSIVE PATHOLOGY IN RISSO'S DOLPHIN:  
DEADLY HUNTING**

*Fernández A, Bernaldo de Quirós Y, Sierra E, Sacchini S, Andrada M, Rivero M, Zucca D, Arbelo M*

*Institute of Animal Health, University of Las Palmas Gran Canaria.  
afernandez@dmor.ulpgc.es*

**Introduction:** Although marine mammals appear to have developed adaptations to avoid most mechanical and physiological effects related to this type of diving disease (Kooyman, 1989), gas bubble-like lesions have been found in mass strandings of beaked whales (Family Ziphiidae) associated in time and space with naval (Fernandez et al., 2005). One of them is the alteration of beaked whales' diving behaviour in response to MFA sonar exposure in such a manner that behavioural or physiological mechanisms employed for protecting against the formation of nitrogen gas (N<sub>2</sub>) bubbles are overridden (Fernández et al., 2005; Cox et al., 2006). According to this proposal, bubble evolution occurs as a result of severe alterations in dive behaviour (e.g. extremely rapid surfacing or remaining at the surface and possibly vigorously swimming).

**Material and Methods:** Fifteen Risso's dolphins stranded in the Canary Islands were necropsied following a protocol which includes gas sampling analysis. A complete pathological study, including bacteriological and virological studies was done in order to look for cause/s of death.

**Results and conclusions:** Here we present pathological findings consistent with severe acute systemic "gas bubble" pathology in Risso's dolphins, providing evidences of a lethal interaction with big squids (*O. bartramii*), as a novel non-related acoustic anthropogenic cause of this Decompression like sickness, previously described in beaked whales linked to sonar.

Dedicated to Prof Dr Franco Guarda

**P128- AMELOBLASTIC FIBROMA IN CHAMOIS (*Rupicapra rupicapra*)**

*Scaglione FE, Iussich S, Grande D, Chiappino L, Sereno A, Ferroglio E, Bollo E*  
*University of Turin, Italy, enrico.bollo@unito.it*

**Introduction:** Odontogenic tumors are rare in animals, and true ameloblastic fibromas have only been described in humans, cattle, and in a dog. It is a rare neoplasm of mixed odontogenic ectomesenchymal and odontogenic epithelial origin.

**Materials and Methods:** A 3-year-old male Chamois (*Rupicapra rupicapra*) was referred for the necropsy to the Department of Animal Pathology of the University of Turin (Italy). A 10×8 cm, exophytic, red-pink, smooth, firm and ulcerated mass was observed on the inferior lip. At the cut surface the neof ormation appeared whitish with a narrow base, suggesting a neoplasm. The mass was fixed in 10% neutral buffered formalin.

**Results:** Histologically a moderately cellular neoplasm characterized by spindle shaped cells arranged in sheets and bundles in abundant hyaline matrix was detected. Neoplastic cells showed indistinct borders, a small amount of eosinophilic cytoplasm, and spindle shaped nuclei with finely stippled chromatin. Mitotic figures averaged 0-1/400x fields. Multifocal chords of odontogenic pigmented epithelium that penetrate the neoplasia were visible. The mucosa showed multifocal and severe erosions, and a severe inflammatory infiltrate. Immunohistochemistry showed Cytokeratin positivity of epithelial clusters.

**Conclusion:** Histological and immunohistochemical findings were consistent with the diagnosis of ameloblastic fibroma. To our best knowledge, this is the first report of this tumor in a chamois.

**Acknowledgements** The authors acknowledge the “Centro di Referenza di Patologia Comparata “Bruno Maria Zaini”, Italy.

**P129- ANAPLASTIC LARGE CELL LYMPHOMA IN A EUROPEAN WILD BOAR (*Sus scrofa*)**

*Rocha PRD<sup>1</sup>, Biasibetti E<sup>1</sup>, Palmerini D<sup>1</sup>, Sereno A<sup>1</sup>, de Vries C<sup>2</sup>, Capucchio MT<sup>1</sup>*

*1 University of Turin, Italy, 2Ghent University, Belgium, pauloricardo.dellarmelinarocha@unito.it*

**Introduction:** Anaplastic large cell lymphoma (ALCL) is classified as a non-Hodgkin's lymphoma. The tumor was first described in humans in 1985. No case of ALCL in wild boar has been described. The present study described a case of ALCL in a European wild boar.

**Materials and Methods:** An adult, male wild boar was necropsied. Samples of tissues were fixed in 10% buffered formalin and submitted to H&E and immunohistochemistry (IHC). CD3, CD79, CD20 and CD30 immunoreactivity were tested by means of DAKO EnVision™+/HRP kit (code K5361).

**Results:** Grossly, an irregular, gray, solid mass (7x8x5 cm) was observed in the abdominal cavity between the liver and the diaphragm, presenting adherences throughout serosa of the same organs. Microscopically, the mass was composed of dense, large basophilic round cells supported by a thin fibrovascular stroma. The liver parenchyma and diaphragm were invaded with metastasizing neoplastic cells. Multifocal necrotic areas were also observed in the mass. Immunohistochemistry was positive for CD30, but negative for CD79, CD20 and CD3.

**Discussion & Conclusion:** This is the first description of ALCL in a wild boar. Histologically, it should be considered as a differential diagnosis of diffuse multicentric large B-cell lymphoma.

**P130- A CASE OF IRIDOPHOROMA IN A DWARF BEARDED DRAGON (*Pogona henrylawsoni*)**

*de Brot S, Ruetten M, Sydler T.*

*Institute of Veterinary Pathology, Vetsuisse Zurich, Switzerland*

**Introduction:** Chromatophoromas are rarely reported cutaneous pigment cell tumors that originate from normal dermochromatophores of skin of fish, amphibians and reptiles. Based on their specific chromatophores, they are classified as melanophoromas, xanthophoromas or iridophoromas.

**Materials and Methods:** An adult female dwarf bearded dragon was presented with a subcutaneous mandibular swelling and with multiple whitish nodules in the oral mucosa. The masses recurred after surgical excision and the animal was euthanized.

**Results:** The animal showed multiple randomly distributed, well demarcated non-encapsulated whitish firm masses in the subcutis of the mandible, oral mucosa, visceral fat, heart, liver and kidney. Histologically, the masses consisted of an infiltrative growing, spindleoid mesenchymal neoplasm with olive greenish intracytoplasmatic pigment which remained unchanged after bleaching. Melan A and vimentin were weakly positive. On transmission electron microscopical images the neoplastic cells contained multiple elongated platelets resembling iridophores.

**Discussion & Conclusion:** A malignant iridophoroma with visceral metastases was diagnosed in a dwarf bearded dragon. In poikilotherms chromatophoromas have to be included in the list of differential diagnoses of pigmented skin tumors.

**P131- MIXED TESTICULAR NEOPLASIA IN A COMMON DOLPHIN (*Delphinus delphis*) INVOLVING SERTOLI CELL TUMOR, INTERSTITIAL (LEYDIG) CELL TUMOR AND SEMINOMA**

*Arbelo M<sup>1</sup>, Díaz-Delgado J<sup>1</sup>, Espinosa de los Monteros A<sup>1</sup>, Fernández-Maldonado C<sup>2</sup>, Quesada O<sup>1</sup>, Rivero M<sup>1</sup>, Andrada M<sup>1</sup>, Rodríguez-Grau Bassas E<sup>1</sup>, Fernández A<sup>1</sup>.*

*1 Institute of Animal Health. University of Las Palmas de Gran Canaria. Spain., 2 Agencia de Medio Ambiente y Agua de Andalucía. Junta de Andalucía. Spain ,marbelo@dmor.ulpgc.es*

**Introduction.:** Among the cetacean scientific literature, testicular neoplasms have been rarely described. A diagnosis of mixed testicular neoplasia in a common dolphin (*Delphinus delphis*) involving a Sertoli cell tumor, an interstitial (Leydig) cell tumor and a seminoma is presented.

**Material and Methods.:** An adult male common dolphin was found stranded on the coast of Almeria (Andalucía, Spain). At necropsy, two masses were observed in the abdominal cavity. Samples from different organs were preserved in buffered formalin (10%), embedded in paraffin, sectioned at 5 µm, and stained with hematoxylin and eosin.

**Results:** One of the masses was adhered to the left testicle showing poor demarcation from the adjacent testicular parenchyma, and the other, was closely related to the right testicle and consistent with a retroperitoneal lymph node. Histologically, in both testicles, the presence of three microscopically distinguishable neoplastic cell populations was observed.

**Discussion and Conclusion:** To our knowledge, this is the first description of a mixed Sertoli cell tumor, interstitial (Leydig) cell tumor and seminoma in a common dolphin. The occurrence of this mixed pattern of testicular neoplasia has not been previously reported in wildlife pathology.

**P132- DIAGNOSTIC METHODS FOR THE DETECTION OF VERTEBRAL MALFORMATIONS IN SENEGAL SOLE (*Solea senegalensis*, KAUP 1858) AT DIFFERENT STAGES OF DEVELOPMENT**

*De Azevedo AM<sup>1</sup>, Losada AP<sup>1</sup>, Barreiro A<sup>1</sup>, Barreiro JD<sup>1</sup>, Ferreiro P<sup>2</sup>, Riaza A<sup>2</sup>, Vázquez S<sup>1</sup>, Quiroga MI<sup>1</sup>*

*1University of Santiago de Compostela, Lugo, Spain, 2Stolt Sea Farm, A Coruña, Spain, anmanuelade.azevedo@rai.usc.es*

**Introduction:** Skeletal malformations cause serious economic losses in aquaculture of many species. One of the major limitations in sole culture is the high incidence of vertebral anomalies that in juvenile Senegal sole are around 40%. Therefore, proper and reasonable methods are required for detecting such deformities.

**Materials and Methods:** A total of 191 Senegal soles were sampled at different stages of development from 32 to 741 days after hatching (DAH). Double staining for bone and cartilage technique (DSBC), digital radiography (DR) and Computed Tomography (CT) were performed.

**Results:** In this study, all the three methods (DSBC, DR and CT) revealed significant information on vertebral structures, allowing malformation identification. Anomalies in smaller specimens were visualized more suitably with double stain technique, while vertebral abnormalities in juveniles and adults were observed with greater convenience with DR and CT.

**Conclusion:** In our experience, the sole size and not the age, is the main factor for selecting the correct method for the adequate observation of the skeleton and vertebral malformations.

This work was supported by “Consellería de Economía e Industria” of Xunta de Galicia (10MMA020E), Spain. AM de Azevedo was the recipient of a University Professorship Formation (FPU) grant from the Spanish Ministry of Education.



### **P133- HISTOLOGICAL AND MORPHOMETRIC CHANGES OF SPLENIC MELANOMACROPHAGE CENTRES IN TURBOT (*Psetta maxima*) VACCINATED AGAINST FURUNCULOSIS**

*Coscelli G<sup>1,2</sup>, Ronza P<sup>1</sup>, de Azevedo AM<sup>1</sup>, Losada AP<sup>1</sup>, Failde LD<sup>1</sup>, Sancho AR<sup>1</sup>, Bermúdez R<sup>1</sup>, Quiroga MI<sup>1</sup>*

*1Universidad de Santiago de Compostela, Spain. 2Universidad Nacional de Rosario, Argentina. germanalberto.coscelli@rai.usc.es*

**Introduction:** Melanomacrophage centres (MMCs) are macrophage aggregates usually located in haematopoietic tissues. They may act as sites of antigen processing in immune responses. This study investigates the histological and morphometric parameters of splenic MMCs of immunized fish with *Aeromonas salmonicida* subsp. *salmonicida* bacterins.

**Materials and methods:** Turbot were immunized by intracoelomic injection with non-adjuvanted and oil-adjuvanted vaccine against furunculosis. Fish from each vaccinated and control group were sampled at 3 h, 7, 21, 46, 90 and 180 days post-vaccination. The spleen were collected, processed for histological examination and stained with H-E and PAS. MMCs morphometry of three randomly selected fields per PAS-stained sections were analysed using an image processing programme. Number and size of MMCs and surface of MMCs per mm<sup>2</sup> of spleen were measured. Statistical studies were performed.

**Results:** No statistically significant differences in any studied parameters among groups were detected at each sampling point. However, a clear tendency toward increasing of mean size, number and occupied surface by MMCs throughout the experiment was observed.

**Discussion and conclusion:** MMCs are involved in the development of the immune response against several fish diseases, including furunculosis; however our results did not show evident morphometric changes in splenic MMCs between immunized and non-immunized fish. In this work, the findings suggest that the morphological features of MMCs were related with the weight or age of fish more than with an immunological process.

This work was funded by the Xunta of Galicia project 08MMA011200PR.

**P134- DOES THE TYPE OF TECHNOLOGY OF RAINBOW TROUT (*Oncorhynchus mykiss*) BREEDING INFLUENCE MORPHOLOGICAL PATTERN OF THE INTERNAL ORGANS AND IMMUNITY IN THIS FISH?**

*Szarek J<sup>1</sup>, Siwicki KA<sup>1</sup>, Babińska I<sup>1</sup>, Skibniewska KA<sup>1</sup>, Dobosz S<sup>2</sup>, Goryczko K<sup>2</sup>, Guziur J<sup>1</sup>, Szynaka B<sup>3</sup>, Strzyżewska E<sup>1</sup>, Wojtacka J<sup>1</sup>, Terech-Majewska E<sup>1</sup>, Zakrzewski J<sup>1</sup>, Wiśniewska A<sup>1</sup>, Szweda M<sup>1</sup>*

*1University of Warmia and Mazury, Olsztyn, 2Inland Fisheries Institute, Rutki, 3Medical University, Białystok, Poland, Szarek@uwm.edu.pl*

**Introduction:** The aim of the study was to evaluate the influence of rainbow trout breeding technologies: recirculation system (RS) and traditional (open system – OS) on morphology of the internal organs and immunity.

**Materials and Methods:** The study was conducted on 480 rainbow trout's took in 2011: 6 groups (n=80), A–C fish from OS, D–F fish from RS. A1-F1 group: fish of 350-500 g b.m., A2-F2: 501-800g. The liver, spleen and kidneys were examined macroscopically, microscopically and ultrastructurally. The immunological study – determination of metabolic and cidal activity of phagocytes and activity of T and B lymphocytes, lysozyme, ceruloplasmine and total protein and gamma-globulin level.

**Results:** Few retrogressive lesions and circulation disturbances were noted in the microscopic study. Ultrastructural examination showed mitochondrial edematous, RER defragmentation and disorders in glycogen distribution. No statistically significant differences in the immunological parameters were found between RS and OS fish.

**Conclusions:** Examined technologies of rainbow trout breeding had similar influence on the pattern of internal organs. The differences were noted in the number of lesions. Rainbow trout bred in RS and OS showed similar cellular and humoral immunity.

**P135- CHANGES IN SPLENIC MELANOMACROPHAGE CENTRES OF TURBOT, *PSETTA MAXIMA* (L.), EXPERIMENTALLY INFECTED WITH *Enteromyxum scophthalmi* (MYXOZOA)**

*Ronza P, Coscelli G, Losada AP, Bermúdez R, Quiroga MI*

*University of Santiago de Compostela, Spain. paolo.ronza@usc.es*

**Introduction:** Melanomacrophage centres (MMCs) are well-defined groups of pigmented macrophages mainly observed in the haemolymphopoietic organs of teleost. There are many evidences of their role in the immune response and it has been suggested that they may be evolutionary precursors of germinal centres. The aim of the study was to evaluate the morphometric changes of MMCs during *Enteromyxum scophthalmi* infection.

**Materials and Methods :** Five control and ten infected fish were randomly sampled at days 20, 40, 56 and 78 post-exposure (PE). The health condition and severity of infection were evaluated by histopathology. MMCs area (MA), number of MMCs/mm<sup>2</sup> of splenic tissue (MN) and percentage of the organ occupied by MMCs (PO) were measured in histological sections stained with toluidine blue at 200x enlargements.

**Results :** MMCs density (PO and MN parameters) resulted significantly ( $p < 0,05$ ) lower in turbot with slight infection and greater in severe infected fish, mostly represented in the 40 and 78 days PE sampling point respectively. MA did not show any significant variation.

**Discussion:** Changes in splenic MMCs density suggest that a mobilization of melanomacrophages from this site occurs during enteromyxoses, opening interesting perspectives in the study of the kinetics and function of these cells in turbot immune response.

This work was funded by project AGL2009-13282-C02-02 of the Spanish Ministry of Science and Innovation. Ronza P is the recipient of a predoctoral grant from University of Santiago de Compostela.

## **P136- FRACTAL ANALYSIS USED FOR IDENTIFYING THE IMPACT OF DRUGS ON THE HEPATIC TISSUE**

*Gaita L., Militaru M.*

*University of Agronomic Sciences and Veterinary Medicine of Bucharest, Romania,  
clinica@ortovet.ro*

**Introduction:** In the initial stage of drug induced hepatic lesions, classic histological exams fail to reveal changes, while blood work already shows significant functional and enzyme level changes. This study examines the ability of fractal analysis to reflect drug induced minor changes in the liver.

**Materials and Methods:** Fractal dimension (FD) was computed on complete histology images (CHI) and on chromatin regions (CR) extracted by image segmentation. Images were available from a previous study on rats with induced tumours, investigating the hepatic effects of mitoxantrone, farmarubicine, and holoxan, as well as of phenol extracts from three plants. The statistical analysis carefully complied with the features of the input data and included ANOVA, t-test, power, size effect, and confidence intervals.

**Results:** We found the impact of the toxic drugs on the FD of the histology images to be major and reliable, with variations among the drugs and the types of images (CHI and CR). The effect of the protective drugs on the FD of the images is less impressive.

**Discussion & Conclusion:** This study provides additional evidence that FD of histology images can be used as an additional diagnostic tool in the pathology lab. Introduction of FD as a regular additional image-processing step can lead in a short time to confirming its added value in identifying small and diffuse lesions.

### **P137- ASSESSMENT OF MULTI-WALLED CARBON NANOTUBES (MWCNT) IMMUNOTOXICITY ON THE PERITONEUM-ASSOCIATED LYMPHOID TISSUE.**

*Tăbăran Alexandru-Flaviu<sup>1</sup>, Cătoi Cornell, Bolfă Pompei<sup>1</sup>, Nagy Andras<sup>1</sup>, Gal Adrian*

*1, Taulescu Marian<sup>1</sup>, Bouari Cosmina<sup>1</sup>, Simona Clichici<sup>2</sup>, Teodora Mocanu<sup>2</sup>,<sup>1</sup>University of Agricultural Sciences and Veterinary Medicine Cluj-Napoca, Romania, <sup>2</sup>Iuliu Hatieganu University of Medicine and Pharmacy, Cluj-Napoca, Romania, flaviu\_tabaran@yahoo.com*

**Introduction:** The carbon nanotubes are novel one-dimensional nanomaterials that, due to their unique chemical and mechanical properties, are intensively investigated for medical application. The main limitation of these applications are related to the toxicity issues, their impact on living organisms being, however, not entirely clarified.

**Materials and Methods:** Each of the 60 rats received intraperitoneally 1.5 ml of ss-DNA-MWCNT solution (4,05 mg. MWCNT/animal). Samples from the greater omentum and lymph nodes that drain the peritoneal cavity were analyzed in terms of histology, ultrastructure, oxidative stress parameters and pro-inflammatory cytokines.

**Results:** At 1 hour after the administration, the MWCNT were concentrated primarily in the peritoneal milky spots and lymph nodes which drain the peritoneal cavity. Local expression of IL6, iNOS, TNF $\alpha$  and S-nitrosocysteine had a peak at 24 hours, structural changes being observed at 48 hours and well expressed at 144 hours after the MWCNT administration. The histological changes were represented by sinus histiocytosis and granulomatous peritonitis accompanied by early fibroplasia.

**Discussion & Conclusion:** A strong relationship between the accumulation and toxicity of these nanoparticles on the peritoneum-associated lymphoid tissue was found, the local oxidative stress being followed by the expression of pro-inflammatory cytokines, macrophage influx, myofibroblast phenotype expression and early fibrosis.

## **P138- MORPHOLOGICAL LESIONS IN MOUSE LIVER AND LUNGS AFTER CARBON NANOTUBES LUNG EXPOSURE**

*Szarek J<sup>1</sup>, Mortensen A<sup>2</sup>, Jackson P<sup>3</sup>, Saber AT<sup>3</sup>, Kyjovska ZO<sup>3</sup>, Wallin H<sup>3</sup>, Vogel U<sup>3</sup>, Hougaard KS<sup>3</sup>*

*1University of Warmia and Mazury, Olsztyn, Poland, 2National Food Institute, Technical University of Denmark, Søborg, Denmark, 3National Research Centre for the Working Environment, Copenhagen, Denmark, Szarek@uwm.edu.pl*

**Introduction:** Engineered nanoparticles are smaller than 100 nm in at least one direction and designed to improve or achieve new physicochemical properties. Consequently, also toxicological properties may change. Carbon nanotubes have attracted industrial interest due to their unique properties.

**Materials and Methods:** One day pre-mating 30 mice (C57BL/6BomTac, Taconic Europe, Denmark) were instilled intratracheally with 67 µg multiwalled carbon nanotubes (NM-400, Nanocyl, Belgium) – A group. 30 controls mice received vehicle (Millipore water with 2% mouse serum) – B group. Lungs and liver were taken from 6 animals from each group for histopathological examination (hematoxylin and eosin staining) 6 weeks (A1, B1 group) and 4 months (A2, B2) after exposure.

**Results:** Lungs in A1 mice show bronchiolar subepithelial oedema and perivascular oedema, and also sporadically hyperaemia and presence of macrophages. Oedema was slightly visible in A2 mice, but infiltration of macrophages was more intensive. In liver, microfoci of necrosis, infiltration of inflammatory cells, and lesions in Kupffer cells were more intensive in A1 group than A2.

**Conclusion:** Intratracheal exposure to multiwalled carbon nanotubes caused inflammatory and retrogressive lesions in mouse lungs and liver.

## **P139- CELL PROLIFERATION-INDUCING CARCINOGENS LEAD TO ABERRANT ACTIVATION OF G2/M CHECKPOINT AND APOPTOSIS AFTER 28-DAY ADMINISTRATION IN RATS**

*Eriko Taniai<sup>1,2</sup>, Atsunori Yafune<sup>1,2</sup>, Kunitoshi Mitsumori<sup>1</sup>, Makoto Shibutani<sup>1</sup>*

*1 Laboratory of Veterinary Pathology, Tokyo University of Agriculture and Technology, Tokyo, Japan, 2 Pathogenetic Veterinary Science, United Graduate School of Veterinary Sciences, Gifu University, Gifu, Japan, taniaie@cc.tuat.ac.jp*

**Introduction:** We have previously revealed that all renal carcinogens examined in rats treated for 28 days increased tubular cell proliferation and topoisomerase (Topo) II $\alpha$ + cells. We aimed to identify in vivo early prediction markers of carcinogens.

**Materials and Methods:** Immunohistochemical analyses of marker candidates selected from microarray analysis was performed in the kidney of rats treated with renal carcinogens (ferric nitrilotriacetic acid, ochratoxin A, monuron, tris(2-chloroethyl) phosphate, and potassium bromate) or non-carcinogens (p-nitrobenzoic acid and acetaminophen) for 28 days. We then immunohistochemically examined marker candidates with other carcinogens targeting the liver (thioacetamide, fenbendazole, piperonyl butoxide and methyleugenol), thyroid (sulfadimethoxine), urinary bladder (phenylethyl isothiocyanate), forestomach (butylated hydroxyanisole), pylorus (catechol), or colon (chenodeoxycholic acid and 2-amino-1-methyl-6-phenylimidazo[4,5-b]pyridine) and with non-carcinogens (acetaminophen and  $\alpha$ -naphthyl isothiocyanate for the liver and caprolactam for other organs).

**Results:** All renal carcinogens increased Topo II $\alpha$ +, minichromosome maintenance 3+, ubiquitin D (Ubd)+ and apoptotic cells, compared with untreated controls or non-carcinogens. Similar responses were detected with other organ carcinogens facilitating cell proliferation.

**Discussion:** Both Topo II $\alpha$  and Ubd, indicative of aberrant activation of G2/M checkpoint, and an apoptosis assay may be a rapid screening unit for cell proliferation-inducing carcinogens irrespective of target organs after 28-day-treatment.

## **P140- STUDIES ON LIVER TUMOR PROMOTING EFFECTS OF ORPHENADRINE IN RATS**

*Reiko Morita<sup>1, 2</sup>, Hitomi Hayashi<sup>1, 2</sup>, Kazuhiko Suzuki<sup>1</sup>, Makoto Shibutani<sup>1</sup> and Kunitoshi Mitsumori<sup>1</sup>*

*1 Laboratory of Veterinary Pathology, Tokyo University of Agriculture and Technology, Tokyo, Japan, 2 Pathogenetic Veterinary Science, United Graduate School of Veterinary Sciences, Gifu University, Gifu, Japan, rmorita@cc.tuat.ac.jp*

**Introduction:** Orphenadrine (ORPH), an anticholinergic agent, is a cytochrome P450 (CYP) 2B inducer. CYP2B inducers are known to have liver tumor promoting effects in rats. In this study, we performed a rat two-stage liver carcinogenesis bioassay to examine the tumor-promoting effect of ORPH.

**Materials and Methods:** Male rats were given a single intraperitoneal injection of N-diethylnitrosamine (DEN) and were fed diet containing ORPH (0, 750, or 1500 ppm) for 8 weeks after DEN initiation with two-thirds partial hepatectomy one week after the ORPH-administration.

**Results:** The number and area of glutathione S-transferase placental form-positive foci significantly increased in ORPH groups. Real-time RT-PCR revealed increased mRNA expression levels of Cyp2b1/2 and Mrp2 in ORPH groups and Gpx2 in high ORPH group. The microsomal reactive oxygen species (ROS) production and oxidative stress markers increased in high ORPH group. Immunohistochemically, constitutively active/androstane receptor (CAR) in ORPH groups were clearly localized in the nuclei of hepatocytes.

**Conclusion:** These results suggest that ORPH has a liver tumor-promoting activity and causes nuclear translocation of CAR resulting in the induction of the liver tumor-promoting activity. Furthermore, oxidative stress resulting from the ROS production is also involved in its promoting activity of ORPH.



## **P141- EFFECT OF MATERNAL EXPOSURE TO GLYCIDOL ON NERVOUS SYSTEM OF DAMS AND OFFSPRING IN RATS**

*Hirotooshi Akane<sup>1</sup>, Fumiyo Saito<sup>2</sup>, Ayako Shiraki<sup>1</sup>, Kunitoshi Mitsumori<sup>1</sup>, and Makoto Shibutani<sup>1</sup>.*

*1) Laboratory of Veterinary Pathology, Tokyo University of Agriculture and Technology, Tokyo, Japan; 2) Chemicals Evaluation and Research Institute, Chemicals Assessment and Research Center, Tokyo, Japan, hi-akane@cc.tuat.ac.jp*

**Introduction:** We examined the developmental exposure effect of glycidol, a by-product of cooking oil, on hippocampal neurogenesis in rats. Maternal neurotoxicity was also examined.

**Materials and Methods:** Glycidol was given to maternal SD rats at 0, 100, 300 or 1000 ppm in the drinking water from gestational day 6 until postnatal day (PND) 21 on weaning. Dams were examined on PND 21, and male offspring were examined on PND 21 and 77.

**Results:** At 1000 ppm, dams exhibited axonal degeneration by spheroid formation in the cerebellar granule cell layer and dorsal funicle of the medulla oblongata and central chromatolysis in the trigeminal nerve ganglion cells. At this dose, offspring showed decreased dpysl3-expressing immature granule cells at the subgranular zone of the hippocampal dentate gyrus on PND 21. In the dentate hilus, interneurons expressing calretinin or reelin and NeuN-positive mature neurons were increased on PND 21 and sustained to PND 77.

**Discussion:** These results suggest that glycidol at high doses targets axon terminals causing distal axonopathy in adult animals and aberration in neurogenesis at the late stage showing neurite extension in offspring sustaining through to the adult stage after developmental exposure.

**P142- MELAMINE INDUCED NEPHROTOXICITY IN WEANED PIGS**

*Kureljušić B<sup>1</sup>, Ivetić V<sup>1</sup>, Savić B<sup>1</sup>, Krnjajić S<sup>2</sup>, Risteovski D<sup>2</sup>, Kureljušić J<sup>1</sup>, Jezdimirović N<sup>1</sup>, Jakić-Dimić D<sup>1</sup>*

*Institute of Veterinary Medicine of Serbia, Belgrade, Serbia, 2Delta Vet Med, DOO, Belgrade, Serbia. branislavkureljusic@yahoo.com*

**Introduction:** Melamine is a chemical product that was sporadically mixed into animal feeds to boost protein content. Excessive melamine in animal feed can induce nephrolithiasis, chronic kidney inflammation, bladder carcinoma and even death in animals.

**Materials and methods:** Ten piglets from one farm were necropsied, and kidneys were taken for histopathological analysis. In addition, feed was taken for toxicological examination.

**Results:** In September 2011. 30–60–day old piglets from one farm in Serbia developed anorexia, polydipsia and lethargy. Mortality was 12% of the population of postweaning piglets. In the 10 piglets in which postmortem examinations were conducted, kidneys were enlarged, firm in consistency, cortical surface was wrinkled and dimpled, with yellow foci in the cortex and medulla. In addition, renal pelvis was dilated. Microscopically, these foci were accumulations of crystals within the lumina of dilated distal tubules and collecting ducts, causing flattening of the renal tubular epithelial cells. Crystals had several dark striations radiating from the center. The multinucleated giant cells surrounding the crystals, interstitial fibrosis, and nonsuppurative infiltrates indicated a chronic inflammatory response. Melamine concentration in the feed was 5 mg/kg.

**Discussion and Conclusion:** This is the first report of poisoning due to melamine in pigs in Serbia. We definitely must give our consideration or judgment to the quality of animal feed and feedstuffs, which always play a major role in animal health.

## **P143- SAFETY ASSESSMENT IN PIGS OF AN EXPERIMENTAL MOLECULE WITH IN VITRO ANTIVIRAL ACTIVITY AGAINST AFRICAN SWINE FEVER**

*Roels Stefan*<sup>1</sup>, *Van der Heyden Sara*<sup>1</sup>, *Neyts Johan*<sup>2</sup>, *Krečmerová Marcela*<sup>3</sup>,

*Koenen Frank*<sup>1</sup>, *Cay Ann Brigitte*<sup>1</sup>, *Tignon Marylène*<sup>1</sup>

*1CODA-CERVA, Brussels, 2Rega Institute, Leuven, Belgium, 3ASCR, Prague, Czech Republic. stefan.roels@coda-cerva.be*

**Introduction:** HPMPDAP (9-(S)-[3-Hydroxy-2-(phosphonomethoxy)propyl]-2,6-diaminopurine) belongs to the group of acyclic nucleoside phosphonates that have proven their efficiency with convincing activity against several viruses. African swine fever virus can cause devastating outbreaks in pigs, with important economic impact. Up to now control strategies to prevent spread of the virus are limited to prophylactic measures and pre-emptive culling. In order to evaluate if HPMPDAP could also be used against ASFV infection, a toxicity study was performed in domestic pigs.

**Materials and Methods:** Four groups of two pigs were intramuscularly injected with 4 different doses of the molecule. There was daily clinical observation and blood collection. Blood parameters were controlled. Autopsy was performed 3 to 4 days after the last administration. Samples of liver and kidneys were taken for histopathological examination.

**Results:** There was apathy, anorexia and vomiting noticed in the groups with the 3 highest doses. Adverse effects were confirmed both by the blood parameters and histopathological findings.

**Conclusion:** HPMPDAP has previously been shown to exert potent protective activity against various DNA virus infections in mouse models and was also demonstrated to be very well tolerated in mice. However, it was not well tolerated in pigs. Before evaluating a novel compounds in pigs, the optimal treatment schemes and administration routes should be established. Additionally, our study confirms that data obtained from studies in laboratory animals cannot per se be extrapolated to target species.

## **P144- THE EFFECT OF WHITE-ROT FUNGI ON *Jatropha curcas* L. PRESSED-SEED CAKE DETOXIFICATION ON CHICKS VISCERAL ORGANS**

*Alves, A<sup>1</sup>, Barros, C<sup>1</sup>, Gama, A<sup>1</sup>, Bezerra, R<sup>2</sup>, Mourão, J<sup>1</sup>, Rodrigues, M<sup>1</sup>*

*1-CECAV, 2-CITAB, University of Trás-os-Montes e Alto Douro, Vila Real, Portugal, aalves@utad.pt*

**Introduction:** *Jatropha curcas* (Linnaeus) is a plant of the family Euphorbiaceae which seeds contain oil that can be converted to biodiesel. The *Jatropha curcas* pressed-seed cake (JC) obtained after oil extraction is an excellent source of nutrients. However, the presence of toxic compounds restricts its use in animal feeding. This study is part of a project that aims to develop a biological detoxification method of *Jatropha curcas* seed cake utilizing white-rot fungi.

**Materials and Methods:** Ninety male chicks (egg tipe), (mean weight 133,3g) were assigned to three dietary treatments between 17 and 45 days of age. The treatments were: Control (Basal diet); 6JC – Basal diet with 6% of JC; 6JC+G – Basal diet with 6% JC treated with *Ganoderma resinaceum*. Deaths were recorded. At the end of the experiment, birds were slaughtered and examined for gross and microscopical changes. Tissues were taken for histopathological examination.

**Results:** 6JC birds showed the highest mortality rates (76,7%), showing generalized congestion, hepatic massive necrosis, pulmonary edema and haemorrhages, renal edema, meningitis and myocarditis. No effects were observed on histomorphology of visceral organs of 6JC+G chicks compared to the control group.

**Discussion & Conclusion:** These results show that the utilization of white-rot fungi to detoxify *Jatropha curcas* seed cake might be a possible alternative.

## **P145- OXT GENE UP-REGULATION IN BOVINE SKELETAL MUSCLE INDUCED BY DEXAMETHASONE AND 17BETA-OESTRADIOL.**

*Divari S<sup>1</sup>, Cannizzo FT<sup>1</sup>, Starvaggi Cucuzza L<sup>1</sup>, Brina N<sup>2</sup>, Mulasso C<sup>1</sup>, Spada F<sup>1</sup>, De Maria R<sup>1</sup>, Biolatti B<sup>1</sup>*

*1University of Turin, Italy. 2COOP Italia, Italy*

**Introduction:** The development of innovative systems for the detection of the illegal growth promoters treatment in animals would be useful to the Public Veterinary Health. In this study the transcriptional effects of 17beta-oestradiol (betaE2) and dexamethasone (DEX) were evaluated in beef cattle skeletal muscle.

**Material and methods:** Charolaise male beef cattle (n=18) were divided into: group A (n=6) received 5 doses of betaE2(20 mg/week/animal, im), group B (n=6) were administered DEX (0.7 mg/day/animal, os) for 40 days and group C (n=6) were negative controls. Samples from the Sternocleidomastoid muscle were submitted to a relative qPCR analysis to detect the gene expression change for oxytocin (OXT), oxytocin receptor (OXTR), insulin growth factor (IGF1), SOX8 and several myogenic factor as MYOD1, MYF5, MRF4 and myogenin. Serum oxytocin was measured by bovine ELISA test.

**Results:** Both the betaE2 and DEX induced a significant up-regulation of OXT in skeletal muscle. DEX treatment increased MYOD1, MYF5 and MRF4 mRNA levels compared to untreated control animals. Serum OXT of cattle increased following betaE2 administration.

**Discussion and Conclusion:** Glucocorticoids, when administered at low concentration, up-regulate the myogenic differentiation. The significant over-expression of OXT gene, induced by betaE2 and DEX administration in beef cattle, could be an interesting topic for future investigation on anabolic effects in skeletal muscle.

**P146- PROGESTERONE RECEPTOR UP-REGULATION FOLLOWING IN VITRO ESTROGEN TREATMENT.**

*Starvaggi Cucuzza L, Cannizzo FT, Divari S, Spada F, Botta M, Biolatti B*

*University of Turin, Dept. Animal Pathology, Italy*

**Introduction:** As previously reported, progesterone receptor (PR) gene expression proved to be a specific biomarker of 17 $\beta$ -estradiol illicit treatment in cattle, following its experimental in vivo administration. This study investigates the effect of different estrogens on the regulation of PR expression in bovine bulbourethral tissue culture.

**Material and methods:** Bulbourethral glands were collected from 6 cattle (5-7 months of age) and then cut into small pieces. Tissue pieces from each specimen were incubated in control medium or medium supplemented with 10<sup>-6</sup> M of either 1) 17 $\beta$ -estradiol, 2) 17 $\alpha$ -ethynylestradiol, 3) mestranol and 4) diethylstilbestrol for 48 or 72 h. The samples were submitted to a relative qPCR analysis to detect the fold gene expression for PR. Each experiment was repeated three times.

**Results:** All the tested estrogenic molecules induced a significant up-regulation of PR gene in bulbourethral gland tissue cultures at both 48 and 72 hours compared to relative control. The greater increase of fold gene expression was obtained for 17 $\beta$ -estradiol as expected because of its higher relative estrogenic potency.

**Discussion and Conclusion:** These results demonstrate that natural and synthetic estrogens induce the increase of PR mRNA levels in bulbourethral gland tissue cultures as demonstrated for the in vivo 17 $\beta$ -estradiol treatment. A future target could be the evaluation of other compounds having estrogen-like activity, such as phytoestrogens and mycotoxins.

## **P147- MORPHOMETRIC ANALYSIS OF TESTICULAR STRUCTURES IN TENCH (*Tinca tinca*) AFTER EXPOSURE TO 17 ALPHA-ETHYNYLESTRADIOL**

*Gómez L<sup>1</sup>, Jiménez B<sup>1</sup>, Fallola C<sup>2</sup>, Pula HJ<sup>2</sup>, Cuesta JM<sup>1</sup>, Galapero J<sup>1</sup>, Oropesa AL<sup>1</sup>*

*1University of Extremadura, Cáceres, Spain. 2Aquaculture Center. Junta de Extremadura. Spain*

**Introduction:** Environmental pollution with synthetic estrogens may pose a serious threat to reproduction of aquatic wildlife species. The current study describes the effects of 17 $\alpha$ -ethynylestradiol (EE2) on the structure of the testis in tench (*Tinca tinca*).

**Material and methods:** Adult male tench were exposed to sub-lethal doses of EE2 (0, 50, 100 and 500  $\mu\text{g}/\text{Kg}$  t.w.) under static conditions for 30 days. The condition factor (CF), testicular somatic index (TSI) and histology (including a morphometric analysis) of the testis were examined.

**Results:** No consistent differences were observed in the CF of EE2-exposed tench when compared with non-exposed fish. A significant decrease in TSI could only be observed at a 50  $\mu\text{g}/\text{Kg}$  t.w. EE2 dose ( $p < 0.05$ ) as compared to the control group. The histopathology of the testis was associated with loss of normal tubular structure with increased doses of exposure, decrease of tubule number, degeneration in Sertoli and Leydig cells, increase in necrotic testicular cells including formation of syncytia structures and, finally, a high incidence of intersex individuals at 100 and 500  $\mu\text{g}/\text{Kg}$  t.w. EE2.

**Discussion and conclusions:** These results indicate that long-term exposure to EE2 may produce clear negative effects on testicular structure in tench.

**P148- INTERSPECIES DIVERGENCE OF MODULATOR GENES IN  
CYSTIC FIBROSIS AND ITS RELEVANCE TO TRANSLATIONAL  
MEDICINE**

*Plog S<sup>1</sup>, Klymiuk N<sup>2</sup>, Mundhenk L<sup>1</sup>, Wolf E<sup>2</sup>, Gruber AD<sup>1</sup>*

*1Freie Universität Berlin, Germany, stephanie.plog@fu-berlin.de. 2Ludwig-  
Maximilians-Universität, Munich, Germany*

**Introduction:** The CLCA (chloride channel regulators, calcium-activated) gene family may play an important role in modulating cystic fibrosis (CF). Interspecies divergence of modulator genes is of prime interest for assessing the phenotype of animal models. In light of the new CF pig models, we have characterized the porcine CLCA family and compared them to the human and murine orthologs.

**Materials and Methods:** The porcine CLCA genes were identified using bacterial artificial chromosomes. Expression patterns were established on protein and mRNA levels. Genomic structures, expression patterns and protein processing were compared with their human orthologs.

**Results:** Interspecies and interindividual divergences of CLCA genes were identified. The porcine gene pCLCA4a was duplicated into two differently expressed genes. Interestingly, a genomic variation of pCLCA4b limits its translation to a subgroup of individuals in the porcine population. Although the pCLCA family shares similarities with the human orthologs, select but significant differences exist.

**Discussion:** Porcine models of CF resemble the human disease more closely than CF mice do, although disease outcome in the pig still differs in some aspects from the human phenotype. Interspecies divergences as seen here are considered responsible for such variations that limit the suitability of animal models. These data emphasize the importance of interspecies variations of modulator genes and add to the understanding of translational medicine.



**P149- THE INCIDENCE OF GROSS MALFORMATIONS IN CHICK  
EMBRYOS OF ROSS 308 BROILERS**

*Dolka I, Kosowska G, Żbikowski A, Dolka B, Doner S, Szeleszczuk P*

*Warsaw University of Life Sciences, Department of Pathology and Veterinary  
Diagnostics, Poland, izabella\_dolka@sggw.pl*

**Introduction:** Malformations in chick embryos are related to genetic, nutritional or toxic factors, also wrong hatchery management, infections, unknown etiology. Regardless of the cause they lead to lost income. This study aimed to estimate the incidence of malformations in chick embryos in relation to the laying period.

**Materials and Methods:** About 1500 eggs were placed in each of the 4 hatcheries. Eggs were incubated at the same conditions (Petersime incubators, according to the manufacturer's recommendations). Eggs came from Ross 308 broiler breeder flocks (BB): 1st group at 37-39 week old (post-peak egg production) and 2nd 53-54wk old. Hatchery waste consisting of dead-in-shell chick embryos was examined (n=270). Gross lesions were evaluated.

**Results:** A total number of embryos with malformations was 20.4% (55/270) of dead-in-shell chick embryos. More cases were in the 1st group (22.2%), less in the 2nd (15.6%). In both groups most often were observed: 45.5% ectopic viscera (mean age 17.5 day of incubation), 38.2% exencephaly (18di), 27.3% polymelia (17.6di). Only in the 1st group were: 16.3% microphtalmia (17.3di), 9,3% crossed beak (19di), 6.9% feathery defect (18.7di), 4.7% dicephalus (17.5di).

**Conclusion:** Malformations were increased after peak egg production of BB. Ectopic viscera was more frequent and often coexisted with other abnormalities. High setter temperatures during mid-incubation may be a possible cause.

**P150- DEGENERATIVE MOTOR POLIOENCEFALOPATHY WITH  
CYTOSKELETON DISRUPTION IN GENETICALLY MODIFIED  
MICE**

*Márquez Merce*<sup>1, 2</sup>, *Capdevila Sara*<sup>3</sup>, *Zamora Carolina*<sup>3</sup>, *Rabanal Rosa M.*<sup>1, 2</sup>,  
*Pumarola Martí*<sup>1, 2</sup>, *Martín Caballero Juan*<sup>3</sup>

*1 Departament de Medicina i Cirurgia Animals and 2 Centre de Biotecnologia  
Animal i Teràpia Gènica (CBATEG). Universitat Autònoma de Barcelona. Bellaterra,  
Barcelona. SPAIN. 3 Parc de Recerca Biomèdica de Barcelona (PRBB). Animal  
Facility. Barcelona. SPAIN. [jmcaballero@prbb.org](mailto:jmcaballero@prbb.org)*

**Introduction:** An unexpected phenotype was found in some 4-month-old knockout mice, presented with 1-month evolution of tremors and ataxia, finishing with death of the animal.

**Materials and methods:** Histological, immunohistochemical (IHC) and ultrastructural (TEM) studies were performed.

**Results:** Microscopically, the central nervous system revealed the accumulation of a white and/or eosinophilic material in the perikaryon of motor neurons (Oculomotor N., Red N., Hypoglossal N., Facial N., spinal cord motoneurons, etc.) associated to gliosis in a symmetric bilateral pattern. This neuronal material was negative to PAS and KB stainings and did not show autofluorescence. IHC revealed the accumulation of neurofilaments (total NF-200KDa) and ubiquitin in those neuronal cumuli;  $\beta$ III-Tubulin was decreased. TEM studies revealed that they were compatible with bundles of neurofilaments; abnormal mitochondria and tubulovesicular structures were also observed. IHC against GFAP and Iba-1 showed reactive hyperplastic astrocytosis and microgliosis. Moreover astrocytes in affected animals showed an increased immunostaining against Heat Shock Protein 25.

**Conclusion:** All these findings correlate with those observed in some human cytoskeletal related neurodegenerative diseases. This transgenic mouse could be a new animal model to study this group of human diseases.

**P151- IMMUNOMODULATION WITH EPIGALLOCATECHIN  
GALLATE IN INJURED SPINAL CORD OF RABBIT.**

*Shaho Ghahramani Dehbokri<sup>1</sup>, Hossein Dehghani<sup>2</sup>, Reza Mohammadzadeh<sup>3</sup>*

*Faculty of Specialized Veterinary Sciences, Islamic Azad University of Tehran (Science & Research Campus), Tehran-IRAN. Special Board Certified in Veterinary Pathology*

**Introduction:** Spinal cord injury (SCI) stimulates an immune response that causes substantial secondary damage inside the injured spinal tissue. Objective: To determine the immunomodulatory effects of epigallocatechin gallate (EGCG) on traumatized spinal cord of rabbit.

**Materials and Methods:** Rabbits were randomly divided into three groups of 7 rabbits each as follows: sham-operated group, control group, and experimental group (50mg/kg EGCG, i.p., immediately after SCI). Spinal cord samples were taken 24 hours after injury and studied for immunohistochemistry of CD4, TNF- $\alpha$ , IL-1 $\beta$ , iNOS and COX-2.

**Results:** Epigallocatechin gallate attenuated immunohistochemical expression of immune-related response criteria.

**Conclusion:** On the basis of these findings, we propose that EGCG may be effective in protecting rabbit spinal cord from secondary damage by modulating of immune responses.

Key words: Epigallocatechin gallate/ spinal cord injury/ immune response/ immunohistochemistry/ Rabbit

**P152- HISTOPATHOLOGICAL & IMMUNOHISTOCHEMICAL  
SURVEY ON ALCL3 MICROINJECTION IN RAT HIPPOCAMPUS**

*Moayer Fariborz , Daliri N. , Roudgari R.*

*Department of Pathobiology, Faculty of Veterinary Medicine, Karaj branch, Islamic Azad University, Karaj, Iran. fariborz\_moayer@yahoo.com*

**Introduction:** Alzheimer's disease (AD) is a senile type dementia and prevalent neurodegenerative disorder characterized by accumulation of extracellular  $\beta$ -amiloid protein (A $\beta$ P) and intracellular neurofibrillary tangles, neuronal loss. According to recent hypothesis, there is a close relationship between Aluminum and AD. The aim of this study was experimental induction of amyloidosis in rat brain as an animal model.

**Materials and Methods:** 60 wistar rats were randomly divided into 2 groups that received normal saline 0.9% (control),  $3.7 \times 10^{-4}$  g/kg/bw AlCl<sub>3</sub> (experimental) by microinjection into CA1 sector of the hippocampus. In days 5, 10, 15, 20, 25 and 30 after injection, 5 rats from each group were euthanized; their brains were removed and weighted. Brain samples were fixed in neutral buffered 10% formalin, routinely embedded in paraffin and stained with H&E and Congo-Red. Immunohistochemical analysis was made by using NCL- $\beta$ -Amyloid Antibody.

**Results:** There was no significant change in weight of brain. Histopathological and immunohistochemical examination showed focal amyloidosis in brain rats of experimental group, particularly in hippocampus and around the vessels. The rate and extent of amyloid deposition significantly increased over days. Neuronal degeneration, edema and gliosis with neurophagia were detected in brain matrix of rats in this group after 25 days.

**Discussion:** Direct injection of AlCl<sub>3</sub> into rat brain results in a number of similarities with the neuropathological changes observed in AD. Aluminum may play crucial roles as a cross-linker in oligomerization. Aluminum induces conformational changes of A $\beta$ P and enhances the neurotoxicity could explain several unsolved aspects of the relation between Aluminum and AD.

**P153- PATHOHISTOLOGICAL AND IMMUNOHISTOCHEMICAL  
EXAMINATIONS OF BRAINS IN DYING AND SURVIVING SEPTIC  
MICE.**

*Klang Andrea<sup>1</sup>, Högler Sandra<sup>1</sup>, Osuchowski Marcin<sup>3</sup>, Katrin Weixelbaumer<sup>3</sup>, Tichy Alexander<sup>2</sup>, Schmidt Peter<sup>1</sup>*

*1Institute of Pathology and Forensic Veterinary Medicine, 2Institute of Medical Physics and Biostatistics; University of Veterinary Medicine, Vienna, Austria.  
andrea.klang@vetmeduni.ac.at*

**Introduction:** In septic humans, encephalopathy is a common complication. The understanding of underlying pathomechanisms and the nature of potential pathohistological lesions in septic brains is insufficient.

**Materials and Methods:** Polymicrobial sepsis was induced by cecal ligation and puncture (CLP) surgery in 3 month old female mice. Based on the daily body temperature (BT) measurements during first 3 days post-CLP, mice were stratified into predicted to die within 24h (BT35°C). Mice were always sacrificed in pairs on the same day. HE- and Fluoro-Jade-B-staining and GFAP and Iba 1-immunohistochemistry of selected brain regions were performed on formalin fixed, sagittally paraffin-embedded brain halves.

**Results:** Pathohistological lesions were not detected in in septic animals, regardless of outcome. Intensity and extent of Iba 1- and GFAP-expression was significantly higher in septic mice compared to control animals. There were no significant differences between surviving and dying septic mice except a higher GFAP-expression in medulla oblongata in dying animals.

**Discussion:** Our results indicate a sepsis-induced activation of microglia and astrocytes that was not accompanied by neuronal damage. We were not able to demonstrate any major outcome-related differences in septic animals except for astrocyte activation in medulla oblongata.

**P154- THE WOBBLY HEDGEHOG SYNDROME– A CLINICAL  
ENTITY WITH VARIABLE CNS LESIONS**

*Karkamo Veera, Dillard Kati, Schulman Kitty, Anttila Marjukka*

*Pathology Unit, Evira, Helsinki, Finland, veera.karkamo@evira.fi*

**Introduction:** Wobbly Hedgehog syndrome is a neurological disease of African pygmy hedgehogs resulting in progressive paralysis.

**Materials and Methods:** Of the 64 hedgehogs necropsied during 2003-2011, 12 had had typical neurological symptoms.

**Results:** Of the 12 affected animals 11 had lesions both in the brain and spinal cord. In all 12 cases there was bilaterally symmetrical vacuolation of the white matter. In the brain it was most severe in the cerebellum and caudal brain stem extending locally to the grey matter. In the spinal cord vacuolation was present to a variable degree in all levels and in all funiculi. Often it was most marked in the cervical spinal cord and in the lateral and ventral funiculi. Myelination was normal in the vacuolated areas. In some hedgehogs multifocal and not always bilaterally symmetrical areas of demyelination were present in the cerebellar roof, caudal brain stem and spinal cord. In some cases the degeneration extended to the grey matter and resulted in Wallerian degeneration in the associated tracts. In quite a few hedgehogs with other causes of death and no previous neurological symptoms there was mild to moderate multifocal white matter vacuolation in the brain but not in the spinal cord.

**Discussion:** The pathogenesis of the lesions remains obscure but it seems likely that the variability in the histological lesions reflects the progression of the disease.

**P155- AGED-RELATED LIPOFUSCIN ACCUMULATION IN DOG  
BRAIN**

*Nesic S<sup>1</sup>, Ristić B<sup>2</sup>, Jovanović M<sup>1</sup>*

*1. Faculty of veterinary medicine, University of Belgrade, Belgrade, Serbia 2. Veterinary specialized institute Zaječar, Zaječar, Serbiasladjan@vet.bg.ac.rs*

**Introduction:** Lipofuscin is a pigment which accumulates in the process of aging mainly in postmitotic long living cells (neurons, myocytes). The pigment consists of various intracellular substances and accumulates primarily in lysosomes.

**Material and Methods:** Brain samples were collected from 59 autopsied dogs. Examined dogs were divided into 4 groups according to the age: I up to 5; II from 5 to 10; III from 10 to 15 and IV over 15 years. Parts of brains (frontal cortex, parietal cortex, hippocampus, cerebellum and medulla oblongata) was fixed in 10% neutral formalin and processed by routine method to paraffin blocks. Paraffin slices thick 5µm were stained with: hematoxylin-eosin, periodic acid Schiff (PAS) and long Ziehl-Neelsen techniques.

**Results:** In the age group over 15 years, pigment was detected in 80% of the examined dogs, while this percentage was 30% in the first group. In the first and second group, lipofuscin accumulated only in neurons of the medulla oblongata. In the third and fourth group lipofuscin was detected in various percentages in neurons of all examined brain sections.

**Conclusion:** Presence of lipofuscin in neurons was proven in dogs from all age categories. Number of positive animals increases proportionally with age. Lipofuscin most often accumulates in large neurons of medulla oblongata nuclei. The accumulation of lipofuscin pigment in neurons increases with the dog's age as well as its widespread increases in neurons of different brain regions.

**P156- MORPHOLOGIC EVALUATION OF THE AGING PROCESS IN BOVINE PERIPHERAL NERVES.**

*Biasibetti E, Iuliano A, Rocha PRD, Amedeo S, Mioletti S, Bianco P\*, Bisanzio D#, Capucchio MT.*

*Dept. Animal Pathology, University of Turin; \*ASLTo4, Italy; #Dept. Environmental Studies, Emory University, Atlanta, U.S.A. elena.biasibetti@unito.it*

**Introduction:** During ageing process multiple degenerative changes occur on nervous tissue involving axons, myelin sheaths and connective tissue. These processes have been investigated in humans and other mammals, but not in cattle. The authors report the morphological changes in bovine peripheral nerves.

**Materials and Methods:** Samples of nerves (axial dorsal metacarpal) from 27 regularly slaughtered aged cows (10-20 years) were submitted to morphological evaluation and biochemical analysis. Animals were grouped in 3 age groups and possible associations between the histological findings and age were investigated.

**Results:** Axonal degeneration, demyelination, thickness of perineurium and endoneurium were the most important detected features. Numerous perivascular mast cells were also observed. All lesions showed a statistically significant (Kruskal wallis with post hoc paired comparisons  $P < 0.05$ ) increase of severity between the age groups. Biochemical analysis reported a statistically significant increase (Kruskal wallis with post hoc paired comparisons  $P < 0.05$ ) of glycosaminoglycans quantitative content between the oldest and the control group.

**Discussion & Conclusion:** Most of the observed findings are similar to those described in aged people and in laboratory species. This is the first study about age related changes of bovine peripheral nerves. Further investigations are needed to better understand the mechanism of these nerve tissue changes.



**P157- DISEASES OF THE CENTRAL NERVOUS SYSTEM IN CATTLE  
FROM THE STATE GOIÁS, MIDWESTERN BRAZIL**

*Sant'Ana FJF<sup>1</sup>, Ferreira Junior JA<sup>1</sup>, Moreira Junior CA<sup>1</sup>, Freitas Neto AP<sup>1</sup>, Costa YL2, Resende RM<sup>2</sup>*

*1. Universidade Federal de Goiás, Brazil, 2. AGRODEFESA, Brazil  
santanafff@yahoo.com*

**Introduction:** Neurological diseases are worldwide important causes of death in cattle. Bovine neurological cases diagnosed over a 3-year period in the State of Goiás, Midwestern Brazil, were reviewed.

**Material and methods:** The review included 148 neurological bovine cases submitted for necropsy and histopathological examination from 2009-2012 to the Laboratory of Veterinary Pathology of the Universidade Federal de Goiás, Campus Jataí, Brazil.

**Results:** Fifty eight (39.19%) cases had a conclusive diagnosis of a central nervous system (CNS) disease and 90 were either inconclusive or consisted of peripheral nervous system disorders. Rabies (27.59%), necrotizing meningoencephalitis by bovine herpesvirus (BoHV) (22.41%), polioencephalomalacia (PEM) (20.69%), nonsuppurative meningoencephalitis (10.34%), listeriosis (5.17%) and pesticide poisoning (5.17%) were the main diagnoses. Cerebellar abscesses, embolic meningoencephalitis, bacterial meningitis and malignant catarrhal fever were infrequently seen.

**Discussion & Conclusion:** Diseases affecting the CNS of cattle from Midwestern Brazil are frequent and the main disorders observed during this period were rabies, BoHV infection and PEM. Control and prophylaxis strategies must be conducted by Brazilian governmental authorities aiming in decreasing economic losses associated to these diseases.

**P158- HIGH-FLOW PRIAPISM CONSECUTIVE TO LUMBAR SPINAL  
STENOSIS IN A DOG: CASE REPORT**

*Payan-Carreira R<sup>1</sup>, Colaço B<sup>1</sup>, Albuquerque C<sup>2</sup>, Abreu H<sup>3</sup>, Rocha C<sup>2</sup>, Pires MA<sup>1</sup>*

*ICECAV- UTAD, Vila Real, Portugal, 2HV-UTAD, Vila Real, Portugal, 3VetFunchal,  
Madeira, Portugal. , ritapay@utad.pt*

**Introduction:** Priapism, a persistent involuntary erection of the penis lasting for more than 4 hours, is uncommon in dogs. Priapism may be classified as non-ischemic or high flow and ischemic or low flow. In the dog, the later are more frequently described. Ischemic priapism is an emergency and often leads to amputation.

**Material and Methods:** A 13-year-old male Pointer was presented for persistent exposition of the penis. The priapism followed an intermittent priapism situation of 2 weeks' duration, which has been attributed to the inflammation and haematoma associated with a perianal bite. The owners became unable to retract the penis into the prepuce, and asked for euthanasia.

**Results:** The dog, anorectic for 48h, showed poor body condition and unsteady locomotion. Complete blood count and serum chemistry were unremarkable. At necropsy, penile and prepuce evaluation showed vessels engorgement and blood accumulation within all the cavernous spaces, accompanied by congestion and thrombosis within the corpus cavernosum. As no significant changes were observed in the pelvic organs, the lumbar-sacral spinal regions were carefully inspected. Signs of L7-S1 stenosis due to spondylosis were observed.

**Discussion & Conclusion:** The case presented herein is a rare situation of high-flow priapism of neurogenic origin. Necropsy findings suggest that it was consecutive to cauda equina compression due to lumbar spinal stenosis.

**P159- EFFECTS OF GLUCOSAMINE SULFATE, CHONDROITIN  
SULFATE AND HIALURONIC ACID ON ARTICULAR CARTILAGE**

*Mónica López<sup>1</sup>, María Permuy<sup>1</sup>, Fernando Muñoz<sup>1</sup>, Oscar Varela<sup>1</sup>, David Guede<sup>2</sup>, José Ramón Caeiro<sup>2</sup>, Antonio González-Cantalapiedra<sup>1</sup>.*

*1 Veterinary Clinical Sciences. Santiago de Compostela University. Lugo, Spain. 2  
Trabeculae S.L., Ourense, Spain.monica.lopez@usc.es*

**Introduction:** The aim of this study was test the effectiveness of the treatment with Glucosamine sulfate (GS), Chondroitin sulfate (CS) and Hialuronic acid (HA) in an experimental model of osteoarthritis (OA) in rabbits.

**Materials and Methods:** A surgical OA was performed on one femorotibial joint of 24 rabbits; divided in 4 groups: OA, treated with vehicle, GS, CS and HA. Treatments begun 3 weeks after surgery and lasted 8 weeks. Contralateral joints were used as control (CTRL-OA, CTRL-GS, CTRL-CS, CTRL-HA). Samples were processed using Donath technique for plastic and measured cartilage thickness (Cg.Th) and superficial fibrillation (FI). Cg.Th was measured independently for non-calcified cartilage (nCg.Th) and calcified (cCg.Th).

**Results:** OA showed a significant increase in all parameters respect to CTRL-OA. GS showed no differences against OA but neither against CTRL-GS indicating a tendency to approach to health. CS showed no differences against OA and CTRL-CS in Cg.Th but difference in FI with CTRL-CS which might suggest less effectiveness in preserving surface. HA has difference in cCg.Th respect to OA showing a little improvement of cartilage.

**Conclusions:** The three treatments were able to partially reverse structural effects of OA, specially swelling, recovering Cg.Th close to healthy joints. GS and HA could stop superficial fibrillation too but not CS.

**P160- A CASE OF BULL-DOG TYPE CHONDRODYSPLASIA IN A  
MINIATURE SCOTTISH HIGHLAND CALF**

*Dittmer KE,<sup>1</sup> Hogan T,<sup>2</sup> Thompson KG<sup>1</sup>*

*1 Institute of Veterinary, Animal and Biomedical Sciences, Massey University,  
Palmerston North 4442, New Zealand, K.E. Dittmer@massey.ac.nz, 2 Vet Services,  
Dannevirke, New Zealand*

**Introduction:** “Bull-dog” type chondrodysplasia is a well recognised genetic disorder of miniature Dexter cattle.

**Materials and Methods:** In November 2011, the mating of a purebred 6-year-old miniature Scottish Highland dam and 3 year-old miniature Scottish Highland sire resulted in the birth of a calf with features very similar to Dexter bull-dog type chondrodysplasia.

**Results:** The calf had no hair, a domed head, a retruded muzzle and protruding tongue. The limbs were extremely short, and the calf had a large ventral abdominal hernia. Genetic testing for the Dexter Bulldog dwarfism mutations, BD1 (2266\_2267ins-GGCA) and BD2 (-198C>T) in the aggrecan gene, was performed at the Animal Genetics Laboratory, University of Queensland, Australia. The calf was homozygous for the BD1 mutation, and both parents were heterozygous carriers of the BD1 mutation.

**Discussion:** This could either be the result of a new mutation or perhaps reflects out-crossing to short-legged Dexter cattle carrying the chondrodysplastic gene during breeding up of the miniature Scottish Highland breed.

**P161- OSTEOCHONDROSIS IN YOUNG FIGHTING BULLS:  
PATHOLOGY, FREQUENCY AND SEVERITY IN SPANISH FARMS.**

*Dávila, U. M, Méndez-Angulo, J.L., Sierra M.A., Méndez, A.*

*University of Córdoba. z52damou@uco.es*

**Introduction:** Osteochondrosis (OC) is a disorder of the cartilage development that has been reported in several species including cattle. Typically affects young animals and causes joint effusion, lameness, and weakness of the affected limb. We hypothesized that could affect Spanish fighting bulls, and that could be related to the weakness observed during the fight.

**Material and Methods:** A total of 450 animals (12 yearling bulls, 42 two year old bulls, 90 three year old bulls, and 306 four year old bulls) were included in this study. We collected the carpometacarpal joints from an abattoir, and evaluated them macroscopically for lesions which were classified as mild, moderate and severe. The cartilage and subchondral bone of the lesions were evaluated histopathologically.

**Results:** Osteochondrosis was found in 58%, 29%, 80%, 86% of yearlings, 2, 3, and 4 year old bulls, respectively. Mild to moderate lesions were found in yearlings and 2 year old bulls, while more severe lesions were detected in 3 and 4 year old bulls. Histologically, mild lesions appeared as slight depressions on the cartilage surface with loss of continuity. In moderate lesions, chondrocytes had a heterogeneous arrangement and showed moderate hypertrophy. In severe lesions, only few hypertrophied chondrocytes could be observed.

**Conclusion:** OC affects young fighting bulls, which in severe cases may cause lameness and weakness leading to a fall. Furthermore, frequency and severity of lesions is influenced by age as showed in the results of this study.

**P162- A CASE OF HYPERTROPHIC OSTEOPATHY IN A CAT  
ASSOCIATED WITH A PNEUMONIA DUE TO AN AWN**

*Brandes K, Heblinski N*

*Animal Pathology Augsburg, Germany, Small Animal Clinic Augsburg, Germany.  
kristin\_brandes@yahoo.de*

**Introduction:** Hypertrophic osteopathy is a rarely described disease in cats consisting in a hyperostosis of the appendicular bones associated with neoplastic or inflammatory intrathoracic lesions. In this particular case an awn caused a focal bronchitis and pneumonia followed by hypertrophic bone changes.

**Material and Methods:** A 9 years old, male neutered, european short hair cat presented clinically episodes of coughing for several months. Lameness appeared after 2 further months and the cat was euthanized because of poor prognosis.

**Results:** In radiographic examination a right side pulmonic consolidation emerged around the main bronchus. The radiography of the long bones, 2 months later, revealed hyperostosis especially of humerus and femur. Gross examination discovered a 2 cm long awn in the lumen of the right main bronchus with surrounding inflammation. Moderate bilaterally symmetric, periosteal hyperostosis of humerus, metacarpi, femur and metatarsi was noted. The axial skeleton was not affected. Pathohistologically, a severe, focal, suppurative and necrotizing bronchitis surrounding the awn was diagnosed. Hyperostotic lesions consisted in a displacement of periosteum by radiating trabeculae of lamellar bone.

**Discussion and Conclusion:** A rare case of hypertrophic osteopathy in a cat caused by incidental inhalation of an awn is presented. The awn as the causing agent was not seen clinically but only in necropsy.

**P163- FRONTONASAL PARASINUSAL EPITHELIAL INCLUSION  
CYST IN THREE HORSES**

*Gunnarsdottir Helga, Chiers Koen, Saunders Jimmy, Schauvliege Stijn, Vlaminck Lieven*

*Faculty of Veterinary Medicine, Ghent University, Ghent, Belgium,  
Koen.Chiers@UGent.be*

**Introduction:** Cysts developing in the skull of horses are rare and limited to paranasal sinuscysts. These occur in foals or young adult horses and are composed of cystic bony nodules filling the maxillary or frontal sinuses. In this study, we've characterized three cystic masses developing from the frontonasal bone in adult horses.

**Materials and methods:** A fluctuating mass of several centimeters located sagittally on the forehead at the level of the frontonasal bone suture was observed in a 12-year-old French Warmblood gelding, a 11-year-old Arabian stallion and a 17-year-old Quarter horse gelding. Sizes of the masses gradually increased during several months. Radiographic examinations revealed that the masses protruded in the frontal sinus without deforming other bony structures. Masses were surgically removed.

**Results:** Histological examination revealed that the wall of the masses consisted of trabecular bone and fibrous soft tissue lined by ciliated epithelium. The epithelium was often flattened and squamous metaplasia was present. Focal hemorrhages, hemosiderin-laden macrophages and suppuration was observed. The masses did not recur and all horses performed well up to 1 year after surgery.

**Conclusion:** The localization, gross and histological appearance are suggestive of a congenital sinusal origin.

**P164- CONGENITAL CUTANEOUS MUCINOSIS IN GREAT DANE  
PUPPIES**

*Hoffmann Annalena<sup>1,2</sup>, Wöhlke Anne<sup>2</sup>, Distl Ottmar<sup>2</sup>, Peters Martin<sup>3</sup>, Hewicker-  
Trautwein Marion<sup>1</sup>*

*1Department of Pathology, University of Veterinary Medicine Hannover, Germany  
2Department of Animal Genetics and Breeding, University of Veterinary Medicine  
Hannover, Germany 3Staatliches Veterinäruntersuchungsamt Arnsberg, Arnsberg,  
Germany. Marion.Hewicker-Trautwein@tiho-hannover.de*

**Introduction:** Canine cutaneous mucinosis occurs as primary condition like in Chinese Shar-Pei dogs or as secondary mucinosis, often in association with other diseases (e.g. hypothyroidism or pyoderma). In dogs, beside diffuse mucin deposition, focal accumulation of mucin within the dermis or submucosa may occur. Furthermore, a single case of follicular mucinosis characterized by accumulation of mucin within the pilosebaceous unit resembling follicular mucinosis in humans has been reported in a 10-year-old Labrador Retriever. The present study describes the pathomorphological features of an unusual congenital cutaneous mucinosis in 12 Great Dane puppies.

**Materials and Methods:** Eight male and four female puppies, between 1 day and 5 weeks old, had thickened skin and wrinkles on the head and legs. Skin samples collected at necropsy were examined histologically and histochemically (alcian blue/periodic acid Schiff method).

**Results:** All animals, beside dermal deposition of mucin, had marked follicular mucinosis with accumulations of alcianophilic material within the pilosebaceous unit, i.e. hair canal, follicle epithelium, and sebaceous glands. Preliminary pedigree analysis suggests an autosomal recessive heredity.

**Discussion:** In the puppies examined, a congenital dermal mucinosis affecting both the pilosebaceous unit and the interfollicular dermis was found. Such a condition, to the best of our knowledge, has not been described in dogs before.



**P165- INTRAEPIDERMAL CYTOKERATIN CAM5.2-POSITIVE  
CELLS IN DOG NIPPLES**

*Yasuno K, Kobayashi R, Yoshimura H, Takahashi K, Ohmachi T, Kamiie J, Shirota K.  
Azabu*

*University, Japan, yasuno@azabu-u.ac.jp*

**Introduction:** Non-keratinocytic cells with clear or vacuolated cytoplasm are frequently observed within the epidermis of dog nipples. We found that most of these cells expressed cytokeratin (CK) CAM5.2, a marker of luminal epithelial cells. In the present study, we investigated the characteristics of these intraepidermal CK CAM5.2-positive cells.

**Materials and Methods:** Nipple tissues from 35 dogs of both sexes were examined. Immunohistochemical staining was performed for CK CAM5.2, CK14, CK20,  $\alpha$ -smooth muscle actin, p63, melan-A, and E-cadherin.

**Results:** Intraepidermal CK CAM5.2-positive cells were present in 21 dogs (60%). They were present singly or formed small clusters within the basal layer. Immunohistochemical analyses revealed that they were positive for E-cadherin, but negative for all other markers examined. Some cells formed a vacuole or lumen in a single cell in which microvilli were present on the luminal surface by electron microscopy. Multifocal proliferation of these cells was observed in the nipples of 3 dogs. In these lesions, proliferating cells formed bilayered tubules with CK CAM5.2-positive inner and CK14/p63-positive outer cells.

**Discussion & Conclusion:** This report describes the presence of intraepidermal CK CAM5.2-positive cells in dog nipples. These data suggested that these cells could be of a lineage of luminal epithelial cells of the papillary duct in the nipples, and that they could form adenomatous lesions.

**P166- CANINE DILATED CARDIOMYOPATHY IS ASSOCIATED  
WITH INCREASED MYOCARDIAL ICAM1 EXPRESSION**

*Sonja Fonfara<sup>1</sup>, Udo Hetzel<sup>1</sup>, Mark Oyama<sup>2</sup>, Simon R Tew<sup>3</sup>, Anja Kipar<sup>1</sup>*

*1 Section of Veterinary Pathology and Parasitology, Faculty of Veterinary Medicine, University of Helsinki, Finland. 2 Department of Clinical Studies, University of Pennsylvania, Philadelphia, USA. 3 Department of Musculoskeletal Biology, University of Liverpool, Neston, UK [akipar@liverpool.ac.uk](mailto:akipar@liverpool.ac.uk)*

**Introduction:** Intercellular adhesion molecule (ICAM)1 is an important factor of endothelial cell activation and is crucial for leukocyte recruitment. It can also be expressed in the myocardium. We aimed to assess its potential role in canine dilated cardiomyopathy (DCM).

**Material and Methods:** Myocardial samples of healthy control dogs, dogs with DCM and dogs with cardiac diseases other than DCM were investigated for the transcription of ICAM1 and a range of relevant cytokines. Immunohistology served to identify the cells expressing ICAM1, IL-6 and TNF $\alpha$  protein, infiltrating leukocytes (T/B cells) and activated, MHC II-positive endothelial cells.

**Results:** ICAM1 transcription was significantly upregulated in dogs with DCM and a positive correlation to IL-1, IL-6, IL-8, IL-10, TNF $\alpha$ , TGF $\beta$ 1 and TGF $\beta$ 3 transcription was observed. In dogs with DCM, cardiomyocytes were shown to express ICAM1 and both examined cytokines, IL-6 and TNF $\alpha$ , and there was a variable degree of leukocyte (T cells, neutrophils, macrophages) infiltration.

**Discussion:** The results suggest a generalised myocardial inflammatory state in dogs with DCM. This might be secondary to disease and associated with severity of disease. However, it also indicates that dogs, like humans, might develop an inflammatory DCM.

**P167- TETRALOGY OF FALLOT IN A PIG**

*Polledo L, González J, Martínez-Fernández B, Pérez-Martínez C, García Iglesias MJ.  
Campus de Vegazana S/N Facultad de Veterinaria. Universidad de Valladolid.*

**Introduction:** Defects of heart and great vessels are common in pigs, especially subaortic stenosis, endocardial cushion defects or patent ductus arteriosus. Tetralogy of Fallot (TOF) is a congenital complicated cardiac anomaly relatively common in human beings and certain breeds of dogs, and the condition is also recognize in cattle, horses, cats and ferrets, but in swine is extremely rare.

**Materials and Methods:** A 2 months-old underweight female piglet was necropsied, and histopathological examination was carried out.

**Results:** The animal showed clinical signs of chronic right side heart failure consisting in multiple edema and chronic hepatic congestion (nutmeg liver), and also clinical signs of acute left side heart failure as pulmonary congestion and edema. Heart showed several congenital defects: ventricular septal defect located high in the septum, overriding aorta, pulmonic stenosis and foramen ovale, which developed secondarily right ventricular hypertrophy, enlargement of the right atrium and poststenotic dilation of the pulmonary artery.

**Discussion:** The primary lesions (ventricular septal defect, dextroposition of the aorta and pulmonic stenosis) led to obstruction to right ventricular outflow, and these four lesions form the TOF.

**P168- ATYPICAL HYPERCHYLOMICRONAEMIA IN A DOMESTIC  
SHORTHAired CAT**

*Blundell Richard, Arrol Lorna.*

*University of Liverpool, UK, r.j.blundell@liv.ac.uk*

**Introduction:** Hyperchylomicronaemia (hyperlipoproteinaemia) is an uncommon disease associated with disrupted lipid transport. Familial hyperchylomicronaemia is an inherited disease due to a deficiency of lipoprotein lipase (LPL) caused by a mutation in the gene, resulting in an autosomal recessive mode of inheritance. Cases typically present with multifocal xanthomata of the skin and visceral organs.

**Materials and Methods:** A 2 year old, male-neutered, domestic short haired cat was presented showing signs of hemiparesis with hypercholesterolaemia (40mmol/l) and hypertriglyceridaemia (10mmol/l) and increased ALT (3000U/l). The animal was euthanased and submitted for post-mortem examination.

**Results:** Throughout the thoracic and abdominal aorta there were multifocal, small (2mm – 2cm), round to ovoid, raised, soft, pale nodules. Examination of haematoxylin and eosin stained sections of aorta revealed multiple sub-intimal atheromas; staining with Oil Red O confirmed the presence of lipid within these nodules. Similar sub-intimal atheromas were observed in small arterioles in multiple locations throughout the body. A large subcapsular haematoma was present in the liver.

**Discussion and Conclusion:** The pathological changes indicate inappropriate lipid storage in the aorta and small arterioles, with the hepatic haematoma providing evidence of vascular weakness. The absence of large xanthomatous lesions is not typical of hyperchylomicronaemia. Vascular atheromas such as those described here are not typical, having been described in one other feline case.

**P169- MORPHOMETRIC CHARACTERISTICS OF THYROID GLAND  
IN APO E KO MICE**

*T. Ristoski*<sup>1</sup>, *T. Tripunoski*<sup>2</sup>, *J. Dimitrova-Shumkovska*<sup>3</sup>

*1 Faculty of Veterinary Medicine, Skopje, Republic of Macedonia; 2 Faculty of  
Medicine, Skopje, Republic of Macedonia; 3 Faculty of Natural Sciences and  
Mathematics, Skopje, Republic of Macedonia*

**Introduction:** Apo E has long been known to play a key role in cholesterol transport and metabolism. In addition, it has indicated that given the multifactorial character of atherosclerosis, thyroid dysfunction has prominent role in its etiology. It is widely known and repeatedly published that hypothyroidism is accompanied with increased level of cholesterol and some other serum lipids, which increases the risk of developing atherosclerosis. Vice versa, several studies showed participation of ApoE lipoprotein in thyroid hormone entry into the cells, which could have a significant stake in peripheral metabolism of thyroid hormones.

**Materials and Methods:** With the present study we sought to address in the 15 weeks old animal model (C57BL/6 wild type versus Apolipoprotein E knockout mice ApoE KO<sup>-/-</sup>), whether Apo E deficiency, can be correlated with altered follicular diameter from peripheral as well as central parts of the thyroid lobes. Formalin-fixed and paraffin embedded thyroid glands were used. Follicular epithelium height and follicular diameter from peripheral as well as central parts of the thyroid lobes were measured with ocular for morphometric analysis, using the Weibl's multipurpose test system M42 (Wild, Switzerland).

**Results:** Marked thickening and height enlargements of peripheral epithelium was visible due to TSH-mediated hypertrophy.

**P170- PANCREAS AND THYROID HYPOPLASIA ASSOCIATED WITH  
RETARDED GROWTH IN A 3.5-MONTH OLD CHIHUAHUA**

*Moreno B, Badiola JJ Departamento de Patología Animal. Facultad de Veterinaria de Zaragoza. bmoreno@unizar.es*

**Introduction:** Pancreas and thyroid hypoplasia are uncommon in all species. This work describes a case of retarded growth in a puppy with pancreas and thyroid hypoplasia.

**Material and methods:** A 3.5 month-old chihuahua with retarded growth, repeated hypoglycaemia episodes and steatorrhea died during a routine examination. A post-mortem was performed and samples taken for histology.

**Results:** An abundant amount of clear liquid was found in the abdominal cavity. The pancreas was hypoplastic and edematous. No thyroid glands were grossly found. Microscopically, a marked reduction and disorganized exocrine pancreas was observed. The endocrine tissue was very difficult to detect. Thyroid gland was composed of small follicles with reduced lumen and little or no colloid. Lymphoid tissues showed marked lymphoid depletion. No other lesions were detected.

**Discussion and Conclusion:** Primary pancreas and thyroid hypoplasia is very rare in dogs. To the best of our knowledge both lesions have never been reported in dogs. In young dogs of some breeds, pancreatic atrophy with lymphocyte infiltration is typically reported and former cases of pancreas hypoplasia are now considered to be atrophy. In this case, lesions suggested a classical pancreatic hypoplasia with absence of both exocrine and endocrine pancreas. Hypoglycemia episodes can be sometimes associated with Addison' disease, however, in this puppy a normal adrenal cortex was found. Thyroid hypoplasia has been associated with retarded growth in puppies due to hypothyroidism. In this case no data about thyroid hormones levels were available.

**P171- SITAGLIPTIN DELAYS PROGRESSION OF RENAL LESIONS  
IN A RODENT MODEL OF TYPE 2 DIABETES**

*Mega Cristina*<sup>1,3</sup>, *Vala Helena*<sup>2,3</sup>, *Oliveira Jorge*<sup>2,3</sup>, *Fernandes Rosa*<sup>1</sup>, *Teixeira Frederico*<sup>1</sup>, *Teixeira de Lemos Edite*<sup>1,3</sup>, *Reis Flávio*<sup>1</sup>

*1Laboratory of Pharmacology & Experimental Therapeutics, IBILI, Medicine Faculty, Coimbra University; 2ESAV and 3Educational, Technologies and Health Study Centre, Polytechnic Institute of Viseu, Portugal. hvala@esav.ipv.pt*

**Introduction:** Diabetic nephropathy is a microvascular complication of diabetes progressing to end-stage renal disease. Thus, ability of antidiabetic drugs to ameliorate renal disease is as important as their capability to control glucose. Whereas the hypoglycemic effects of sitagliptin, an incretin-dipeptidyl peptidase-IV (DPP-4) inhibitor, are well known, its renal effects remain to be elucidated. This study aimed to evaluate the effects of 6-weeks treatment with a low dose of sitagliptin in diabetic nephropathy in the ZDF rat, animal model of Type 2 Diabetes.

**Materials and Methods:** Diabetic ZDF male rats (20-weeks-old) were treated with vehicle/sitagliptin-10 mg/kgBW/day, during 6 weeks (n=8 each). Kidney specimens were stained with haematoxylin-eosin and periodic-acid-Schiff and examined by light microscopy. Semiquantitative rating was assigned to each component, ranging from 0-absent to 3-severe and extensive damage. Damage was assessed by evaluating glomerular and tubulointerstitial lesions (interstitial fibrosis/tubular atrophy – IFTA) and vascular lesions.

**Results:** Renal lesions in ZDF rats were linked with mesangial expansion and extensive sclerosis. Sitagliptin prevented aggravation of glomerular and vascular lesions, as well as IFTA, in diabetic ZDF rats.

**Conclusion:** Results suggest that sitagliptin could provide additional therapeutic benefits against diabetes-associated nephropathy.

**P172- PRESENCE OF KIMMELSTIEL-WILSON LIKE LESIONS IN  
CANINE CHRONIC KIDNEY DISEASE.**

*Vala H, Mega AC, Mesquita J, Nóbrega C, Cruz R, Esteves F, Ortiz AL, Santos C, Teixeira de Lemos E, Reis F. hvala2@gmail.com*

**Introduction:** Nodular increases in mesangial matrix is the definition of Kimmelstiel-Wilson (K-W) lesions. In man, focal mesangiolyses and K-W nodules were positively associated with diabetes, proteinuria and hyalinization of afferent and efferent arterioles. Although, nodular sclerotic lesions may also occur in the absence of diabetic nephropathy and are clinically related to hypertension, smoking, hypercholesterolemia, among others. This study aimed to assess the presence of nodular glomerulosclerosis in dogs in non-diabetic chronic kidney disease.

**Materials and Methods:** A retrospective study including dogs with non-diabetic chronic kidney disease (n=27) was performed. Samples were stained with haematoxylin-eosin and periodic acid of Schiff and classified according to Maxie (2007). Lesions were classified as absent or present and the later, as non-convincing and convincing K-W like lesions. Univariate logistic regression models were performed to measure the association between a positive histological diagnosis of K-W lesions and the accessed histological features (variables membranes, inflammation, atrophy and fibrosis) by using statistical software R with Epicalc package.

**Results and discussion:** Nodular glomerulosclerosis was present in 66.66% of evaluated cases (n=18) of which, 38.88% (n=7) were classified as convincing and 61.11% (n=11) as non-convincing. The convincing K-W like lesions observed, revealed similar microscopic aspects to the descriptions in literature related to man. The presence of fibrosis was positively associated to the diagnosis of K-W lesions (OR=6; p0.05).

**Conclusion:** Presence of K-W like lesions, in dogs with renal failure exposed a possible association with end-stage renal disease. Therefore, the diagnosis of K-W like lesions could be helpful to specify and define renal biopsies.



**P173- ADRENO-HEPATIC FUSION IN DOMESTIC FERRETS  
(MUSTELA PUTORIUS FURUS)**

*Quesada-Canales O, Suárez-Bonnet A, Ramírez GA, Herráez P, Andrada M, Paz Y, Espinosa de los Monteros A.*

*Unit of Veterinary Histology and Pathology. University Institute for Animal Health.  
Faculty of Veterinary. Trasmontaña s/n. oquesada@becarios.ulpgc.es*

**Introduction:** Adreno-hepatic fusion (AHF) is defined as the union of hepatic tissue with the adrenal gland with close intermingling of the respective parenchymal cells. Although AHF is a rather common incidental finding in humans, in the veterinary literature there is only one article reporting this condition in two monkeys. In this work we report 2 cases of adreno-hepatic fusion in domestic ferrets.

**Material and Methods:** A five-year-old neutered male ferret with a history of chronic diarrhea and a one-year-old male ferret with anorexia and sudden death were submitted to the Unit of Veterinary Histology and Pathology where a full necropsy and a histological study were performed.

**Results:** In both cases, a well demarcated, firm nodule, with fluctuant areas, was observed adhered to the right hepatic lobule suspected to be the right adrenal gland. Left adrenal glands were macroscopically normal. Microscopically, the nodules adhered to the liver corresponded with the right adrenal gland, with close intermingling of the respective parenchymal cells and lack of fibrous capsule between the two cell populations. Multiple rounded, variable sized, cystic structures were also observed.

**Conclusion:** To the best of our knowledge, this is the first description of a fusion of cellular elements of the adrenal gland with the hepatic parenchyma in domestic ferrets.

**P174- IMMUNOHISTOCHEMICAL DETECTION OF VEGF SYSTEM  
IN ARRESTING AND VIABLE IMPLANTATION SITES IN IBERIAN  
PIG.**

*García-Fernández RA, Sánchez MA, Sánchez B, García-Palencia P, Ruiz-González I,  
Naranjo C, Palomo A, y Flores JM*

*Departamento de Medicina y Cirugía Animal. Facultad de Veterinaria. UCM. Madrid,  
Spain, jflores@vet.ucm.es*

**Introduction:** Prenatal mortality is a major concern in pork production and highest conceptus mortality coincides with endometrial attachment, around 30 days post-coitum (pc). Embryo viability depends on several factors highlighting vascularization in feto-maternal interface. We focused our study in this period to assess the expression of Vascular Endothelial Growth Factor and Receptor 1 (VEGF and VEGF-R1) in Iberian pig implantation sites.

**Material and Methods:** Immunoexpression of VEGF and VEGF-R1 was performed in arresting (n = 8) and viable (n = 10) attachment sites at days 32-35 pc. vWF (vonWillebrand factor) was used to established the total number of capillaries in the subepithelial area located at the materno-foetal interface and the total number of immunopositive capillaries/  $\mu\text{m}^2$  for VEGF and VEGFR1 were counted.

**Results and Conclusion:** VEGF immunoexpression was detected in the luminal and glandular epithelium, blood vessels and in some stromal cells. VEGFR1 was detected also in the myometrium and conceptus. Total number of capillaries/area, and immunopositive VEGF and VEGFR1 blood vessels, were higher in implantation sites of viable embryos when compared with those of no viable embryos, though not statistically significant. This results point towards an involvement of angiogenic factors in the embryonic lost in Iberian pigs similarly to that previously described for white breeds.

**P175- TNF STAINING PATTERN ON GLANDULAR AND CYSTIC  
CANINE ENDOMETRIAL EPITHELIA**

*Santos C<sup>1</sup>, Vala H<sup>1</sup>, Pires MA<sup>2</sup>, Payan Carreira R<sup>2</sup>*

*1 CI&DETS. Agrarian School of Viseu, Polytechnic Institute of Viseu, 2CECAV-UTAD, Vila Real, Portugal. hvala@esav.ipv*

**Introduction:** Tumour Necrosis Factor (TNF) is involved in tissue regeneration and destruction. It has been found in the uterus of several species, where it shows different expression patterns during disease. This study aimed to compare the cellular pattern of TNF immunorexpression in canine endometrial epithelia in Cystic Endometrial Hyperplasia samples (CEH; n= 48) and control cyclic and postpartal samples (45 and 10 samples, respectively).

**Materials and Methods:** Immunohistochemistry with a specific primary antibody against canine TNF (sc-80386; Santa Cruz Biotechnology; 1:50) was used. The results for TNF immunostaining in the glandular or cystic epithelium were classified as homogeneous or heterogeneous. The presence of cytoplasmic, membrane, focal or diffuse staining was also recorded.

**Results and discussion:** In postpartum and cyclic endometrium an uniform pattern for TNF was found, with sub-cellular location at the cytoplasm and cell membrane. In contrast, in CEH samples the most striking difference was the heterogeneous mosaic pattern for TNF in the cystic epithelium, with focal positive signal in individual cells alternating with negative adjacent cells. An increased proportion of positive cells was observed in areas of major glandular dysplasia. Most positive cells showed apical immunostaining reinforcement.

**Conclusion:** Diseased and healthy endometrial epithelium express a marked distinctive pattern for TNF, suggestive of its possible involvement in the pathology of the CEH process.

## **P176- EVALUATION OF ANIMAL NON-ACCIDENTAL INJURIES IN FORENSIC VETERINARY INVESTIGATIONS.**

*Berzina Dace. Latvia University of Agriculture, Faculty of Veterinary Medicine*

**Introduction:** Statement of the forensic veterinary expert is one of significant evidence to clarify important questions of animal death investigation. The most of these examinations are carried out due to criminal offence against animals according to Latvia legislation. The objective of this work is to evaluate non-accidental injuries related to animal unlawful killing investigated during the last 3 years.

**Material and Methods:** There were examined totally 48 forensic cases. The animal dead bodies were imported for investigation by State Police from different Latvia cities. To clarify the circumstances of each animal death case there were done x-ray investigation, full necropsy and histological examination by light microscopy using haematoxylin and eosin staining.

**Results:** Investigation were carried out in cases of criminal offence against 38 domestic animals (28 dogs, 10 cats) and 10 hunting animals (4 wild boars, 4 roe deers, 1 moose). Examination showed that most of these non-accidental injuries are related to illegal shooting of both hunting and domestic animals. Totally there were 27 animals with gunshot wounds. The rest include 10 cases of blunt force injuries, 6 cases of asphyxia and 5 cases of sharp force injuries. Two investigations of animal cruelty cases carried out signs of torture and mutilation of animal.

**Conclusion:** Forensic veterinary investigation showed that the most often non-accidental injuries are related to illegal hunting, unlawful killing as well as particular cruelty to animals.

## **P177- EVALUATION OF ERYTHROPOIESIS SYSTEM IN BONE MARROW OF HEALTHY HOLSTEIN-FRESIAN COWS (HF)**

*Anna Snarska, Izabella Babińska<sup>1</sup>*

*Department of Internal Diseases, <sup>1</sup>Department of Pathophysiology, Forensic Veterinary Medicine and Administration, Faculty of Veterinary Medicine, University of Warmia and Mazury in Olsztyn, Oczapowskiego St. 13/14, 10-719 Olsztyn, Poland  
izabella.babinska@uwm.edu.pl*

**Introduction:** Blood cells are formed by hematopoietic stem cells which have the ability to self-renew and replenish all blood cell types. The aim of our study was to determine reference values of bone marrow red blood cells in healthy cattle.

**Materials and Methods:** The experiment was conducted on 10 high-yielding, clinically healthy HF cows aged 2-3 years. Bone marrow samples were collected with a marrow biopsy needle, from the medullary cavity of the third and fourth rib in the sternal region. A smears were stained by May Grünwald-Giemsa method.

**Results:** The mean values (in %) for each type of erythroblasts (ERBs) in bone marrow were as follows: proerythroblasts 2.3, basophilic ERBs 4.72, polychromatic ERBs 13.32 and orthochromatic ERBs 19.98 (total number of ERBs 36.32%). Our results were compared with the reference values given by Jain (1986) and a minor variation in the number of basophilic, polychromatic and orthochromatic ERBs were observed. Additionally an increase in the number of orthochromatic erythroblasts was noted with a simultaneous drop in basophilic and polychromatic erythroblast counts.

**Discussion:** A comparison of average normoblast counts yielded normal values for the studied species. It can be concluded that bone marrow sampling in cattle and other animal species is an useful and effective technique for diagnosing acute hematopoietic disorders such as anemia, leukocytosis and coagulopathy.

## **P178- EVALUATION OF LEUKOCYTAL SYSTEM IN BONE MARROW OF HEALTHY HOLSTEIN-FRESIAN COWS (HF)**

*Izabella Babińska, Anna Snarska<sup>1</sup>*

*Department of Pathophysiology, Forensic Veterinary Medicine and Administration,  
1Department of Internal Diseases, Faculty of Veterinary Medicine, University of  
Warmia and Mazury in Olsztyn, Oczapowskiego St. 13/14, 10-719 Olsztyn, Poland  
izabella.babinska@uwm.edu.pl*

**Introduction:** The production and development of leukocytes takes place in the bone marrow in the process of hematopoiesis. During hematopoiesis, leukocytes undergo the following developmental stages: neutrophilic, eosinophilic and basophilic granulopoiesis, monocytopoiesis, lymphopoiesis and megakaryopoiesis. The objective of this study was to determine the activity and effectiveness of bone marrow hematopoiesis in healthy, adult cattle.

**Materials and Methods:** The experimental material comprised 10 high-yielding, clinically healthy HF cows aged 2-3 years. Bone marrow samples were collected with a marrow biopsy needle, from the medullary cavity of the third and fourth rib in the sternal region. A smears were stained by May Grünwald-Giemsa method.

**Results:** Our results were compared with the reference values given by Jain (1986) and revealed that the total counts of granulocytic and monocyte-macrophage series cells were consistent with the norms for the species. However, a significant increase in cell counts was noted in every developmental stage of the eosinophilic and lymphoid lines. Minor differences in microscopic pattern of eosinophilic cells and monocytes in comparison with these cells in other species were seen.

**Discussion:** Granulocytic, monocyte-macrophage and lymphoid development series have to be analyzed in evaluations of the leukocytal system. Bovine inflammatory diseases are difficult to diagnose due to physiologically high lymphocyte counts. Assessments of bone marrow white blood cells at different developmental stages support the diagnosis and the determination of progression of pathological states in animals.

## **P179- STUDY OF BONE MARROW HISTOLOGY: THE PROCEDURE CHECKPOINT**

*Lourenço L, Gama A, Pires MA*

*CECAV-ECAV-UTAD, Vila Real, Portugal, apires@utad.pt*

**Introduction:** Bone marrow is the object of studies in experimental and spontaneous pathology, namely in leishmaniasis infection. The aim of this work was to determine the best way to process bone marrow tissue for histology.

**Material and methods:** The experimental design of this preliminary study was performed with fresh femurs of Wistar rats. In each group, femurs were fixed in buffered formaline at 4%. In Group A the bone was sagittally opened, preserving the bone marrow inside; in Group B the epiphyses were cutted before fixation and in Group C all bone was fixed. After fixation, a 2-hour decalcification (TBD-1) was performed. In the group A bone marrow isolated from the bone was routinely processed, whereas in groups B and C the bone was sectioned longitudinally and perpendicularly, and part of bone marrow was processed alone. 3µm tissue sections were stained with hematoxylin and eosin to accurate the best morphology.

**Results:** All bone marrow tissues demonstrated appropriate fixation and morphology. Nevertheless, in the case of the maintenance of epiphysis, the bone marrow showed best preservation and tissue quantity. The longitudinal section was best than transversal, and when isolated from bone, bone marrow tissue presented rifles, due to a deficient distension of cut surface.

**Discussion & Conclusion:** Our preliminary results showed that bone marrow is best processed when the whole bone is used, on longitudinal sections, after a short decalcification.

## **P180- IMMUNOHISTOCHEMICAL DETECTION OF DENDRITIC CELL MARKERS IN CATTLE PARAFFIN WAX-EMBEDDED TISSUES**

*Romero-Palomo F, Riscalde MA, Molina V, Sánchez-Cordón PJ, Pedrera M, Gómez-Villamandos JC*

*Department of Comparative Pathology, Veterinary Faculty, University of Córdoba, Spain v32ropaf@uco.es*

**Introduction:** Dendritic cells (DCs) are “professional” antigen-presenting cells with a critical role in the regulation of innate and adaptive immune responses. The objective of this study was to characterize the in vivo distribution of DCs in bovine tissues on the basis of their differential expression of potential DC markers such as MHC-II, CD208, CD1b, CD205 and CNA.42, being the latter specific for follicular dendritic cells (FDC) whose origin and role is different to the rest of hematopoietic DCs.

**Materials and Methods:** Six healthy Friesian calves were used in this study. After necropsy, tissues from different organs were formalin fixed, processed by routine methods and embedded in paraffin wax. The avidin-biotin peroxidasa complex (ABC) method was applied to 4 µm tissue sections. The most appropriate dilutions and pretreatments were studied for each of the primary antibodies.

**Results and Discussion:** The most significant results included the unexpected finding of CD208 positive cells within lymphoid follicles and thymus medulla; MHCII followed by CD208 were the most widely expressed markers, both in intensity and amount of labeled cells; CD1b positive cells were found only in thymus and interfollicular areas of some lymph nodes. Cells stained with DEC-205 were scarce and their localization was mainly in non lymphoid tissues; CNA.42 positive cells were localized in primary lymphoid follicles and light zones of germinal centers.

**Conclusion:** These results intend to serve as a basis for the study of DCs in pathological tissues.

Supported by grants from the Junta de Andalucía (P09-AGR-4671)



## **P181- IMMUNOHISTOCHEMICAL EXPRESSION OF CAVEOLIN-1 IN CHRONIC CANINE LIVER DISEASE**

*Nagy Andras-Laszlo, Bolfa Pompei., Taulescu Marian., Tabaran Flaviu., Bouari Cosmina., Gal Adrian., Borza Gabriel., Catoi Cornel.,*

*University of Agricultural Sciences and Veterinary Medicine Cluj-Napoca, Romania.  
nagyandras26@gmail.com*

**Introduction:** Caveolins are the main structural proteins of caveolae. They play a role in important physiological functions such as signal transduction, endocytosis, transcytosis in capillary endothelial cells, potocytosis, intracellular cholesterol transport and tumor suppression.

**Materials and methods:** The study was realized on nineteen hepatic samples from dogs with chronic liver disease, obtained during necropsy examination. These samples were represented by 12 cases of cirrhosis, 1 case of lobular dissecting hepatitis, and 6 cases of chronic hepatitis. Control liver tissue was represented by 4 liver samples from dogs without hepatic lesions. Immunohistochemical study was realized using antibodies against Caveolin-1.

**Results:** In normal liver tissue, Cav-1 was expressed slightly by the endothelial lining cells of sinusoidal capillaries, the endothelial cells of the portal veins, central veins and hepatic arteries, there was also a strong expression in the smooth muscle cells from the tunica media of hepatic arteries. In the cirrhotic tissue a strong increase of Cav-1 expression was observed. Strong expression by the sinusoidal endothelial cells in the areas of sinusoidal capillarization, by the proliferating cholangiocytes, by the activated hepatic stellate cells and mesenchimal cells within fibrous septa was noticed.

**Discussion and Conclusions:** In the hepatic tissue, Caveolin-1 is a good marker of vascular structures with continuous endothelium and a good indicator of sinusoidal capillarization.

**P182- MEASUREMENT OF REID INDEX IN NORMAL PIG LUNGS.**

*Gil V<sup>2</sup>, Ramírez T<sup>1</sup>, Paz Y<sup>1,2</sup>, Quesada-Canales O<sup>2</sup>, Suárez-Bonnet A<sup>1</sup>, Herráez P<sup>1,2</sup>, Andrada M<sup>1</sup>.*

*Department of Morphology<sup>1</sup>. Unit of Veterinary Histology and Pathology. University Institute for Animal Health<sup>2</sup>. Faculty of Veterinary. Universidad de Las Palmas de Gran Canaria. Spain. mandrada@dmor.ulpgc.es*

**Introduction:** In 1960, Reid defined chronic bronchitis in quantitative terms by measuring the ratio (Reid Index), of the thickness of the mucous glands where they lay between the bronchial cartilage and the basement membrane of the mucosa to the total thickness of the wall from perichondrium to the basement membrane. The aim of this work was to estimate this index in normal pig lungs to study if it could be an indicator in chronic bronchopneumonic processes in pigs.

**Materials and Methods:** Measurements were made on bronchi from 13 pigs at slaughter. The number of measurements made in each bronchus varied; in a few was 3, but in the most was 6. The average of the measurements was taken as representative of the particular bronchus. They were made by means of light microscope (10x).

**Results:** The mean thickness of the bronchi wall was 20.69, and of the gland was 6.86, being the mean Reid index 0.34 and the standard error 0.08.

**Discussion and Conclusions:** The normal index in humans is less than 0.4 and according to our results in pigs is 0.34. Further studies with a high number of animals are needed, including pneumonic lungs with chronic bronchitis to compared variations in this index, as occurs in human.

## **P183- EVALUATION AND CHARACTERIZATION OF INTESTINAL OEDEMA IN PIGS**

*Ortiz Ana Liza<sup>1</sup>, Vala Helena<sup>2</sup>, Silva Aura, Venâncio Carlos, Garcia Carla, Ferreira David<sup>1</sup>*

*University of León, Spain. liza.oliveira@gmail.com 2-Polytechnic Institute of Viseu, Portugal. hvala@esav.ipv.pt*

**Introduction:** Authors propose a standardization system for more accurate histopathological evaluation of intestinal oedema in pigs. Specific alterations were assumed to characterize Grade1, Grade2 and Grade3 oedema.

**Material and Methods:** Eighteen Large White pigs underwent total intravenous anaesthesia (TIVA) with propofol and remifentanyl. 25 ml/kg of arterial blood were removed from the femoral artery. Volume was replaced using Ringer Lactate in Gr1 (n=6) and Hydroxyethyl starch 130/0.4 in Gr2 (n=6), 20 minutes after bleeding. Animals of Gr3 (n=6) underwent TIVA without haemorrhage or volume replacement. One hour after, pigs were euthanized and small intestine samples taken for histopathological examination. Oedema was classified in a specific scale from Grade0 to Grade3 (normal, mild, moderate and marked).

**Results:** Grade2 oedema was predominant in duodenum and jejunum in Gr1 (n=3, n=4, respectively). Grade1 was predominant in ileum in both Gr1 (n=5) and Gr2 (n=4), being Grade0 the grade more often observed in this segment in Gr3 (n=3). Jejunum was the only intestinal segment where Grade3 oedema was observed, and only in Gr2 (n=1). The highest frequency of Grade0 oedema for all the intestinal segments was observed in Gr3 (n=8).

**Conclusion:** The characterization used for the different grades of oedema improved uniformity when deciding which grade to attribute in each case and may allow standardization of oedema grading in further studies.

## **P184- IMMUNOHISTOCHEMICAL CHARACTERIZATION OF LANGERIN IN TURBOT, *Psetta maxima* (L.)**

*Sancho AR<sup>1</sup>, Coscelli GA<sup>1,2</sup>, Failde LD<sup>1</sup>, Bermúdez R<sup>1</sup>, Quiroga MI<sup>1</sup>*

*1Universidad de Santiago de Compostela, Lugo, Spain. 2Universidad Nacional de Rosario, Argentina. arsancho@gmail.com*

**Introduction:** Langerin is presently the state-of-the-art marker for identifying mammal dendritic cells, the most powerful antigen-presenting cells known, which play critical roles in the balance between immune tolerance and activation. However, these processes are scarcely understood in fish, mainly due to scant specific commercial markers for these vertebrates. The objective of this study was to achieve an immunohistochemical (IHC) technique for the detection of Langerin in turbot tissues.

**Materials and Methods:** Turbot specimens were sacrificed by chilling on ice and severing the spinal cord. Small samples of skin, muscle, gills, different sections from digestive tract, pancreas, liver, spleen, thymus and kidney were fixed in Bouin's liquid and embedded in paraffin wax. IHC techniques to detect Langerin in turbot tissues were developed, employing a policlonal antibody goat anti-human Langerin.

**Results:** We found Langerin expression in turbot thymus, spleen and kidney mononuclear cells, as well as in elongated cells of digestive tract and in dendritic-like cells of turbot skin, comparable to reactivity seen in human Langerhans cells.

**Discussion and Conclusion:** To our knowledge this study is the first report of IHC detection of Langerin in turbot tissues and teleost skin. Therefore we propose Langerin as a valuable marker to study the teleost immune system.

This work was supported by a project of the Xunta de Galicia 08MMA011200PR

# **DISCUSSION CASES**



**Case 1**

**SPLENIC MASS IN A DOG**

*García-Quirós, A., Penadés, M., Viana, D., Ortega, J.*

*University CEU Cardenal Herrera. Moncada, Spain. jortega@uch.ceu.es*

A 14 year-old, male, cross breed dog was presented with great abdominal distension and marked bulging in the cranial region. A multinodular, cavitated, big mass in the abdomen was described after radiological examination, compatible with sarcoma. Splenectomy was carried out and the organ was submitted to our lab for histopathological examination.

The spleen showed a round, solid mass attached to the cranial border (measuring 35cm in diameter), and a smaller, similar one within the caudal border (reaching 8 cm in diameter). At biopsy examination, different types of well-differentiated mesenchymal neoplasias were observed. Some of the differential diagnoses compatible with these findings are: liposarcoma, osteosarcoma, chondrosarcoma and mesenchymoma.

**Case 2**

**MULTIPLE RAPIDLY PROGRESSING CUTANEOUS NODULES IN A BOXER DOG BUT NO MAST CELL TUMOR?**

*Plog S<sup>1</sup>, Gruber Achim D<sup>1</sup>, Linek M<sup>2</sup>*

*Dept. of Veterinary Pathology, Freie Universität Berlin<sup>1</sup>, and Veterinary Specialists, Hamburg<sup>2</sup>, Germany*

The three years old female Boxer dog presented clinically with multifocal painful nodular cutaneous masses that rapidly increased in size, some of which with severe erythema and/or alopecia, predominantly on the neck, trunk and head. The cutaneous lesions were preceded by gastrointestinal signs including vomitus and diarrhea. Lab results indicated only mild eosinophilia with otherwise unremarkable cell counts and blood chemistry. Initial treatments including antibiotics and pain management were largely unsuccessful. Initial histology was performed on H&E or toluidine blue stained sections.



**Case 3**

**“EPIDERMAL PROLIFERATIVE DISORDER” IN A FERRET (*Mustela putorius furo*)**

*Penadés, M., García-Quirós, A. Zuriaga, E., Ortega, J.*

*University CEU Cardenal Herrera. Moncada, Spain. jortega@uch.ceu.es*

The aim of this work is to report a case of a ferret who presented two different proliferative disorders affecting the dermis and epidermis.

A 6 years-old, entire, female ferret presented an eritematous, pedunculated and ulcerated mass of 0,7 x 0,6 x 0,4 cm in the left forelimb. After clinical examination, an excisional biopsy of the nodule was submitted to our lab for histopathological examination.

The dermis was expanded by a non-encapsulated, well circumscribed and densely cellular neoplasia composed of two types of epithelial cells (basal and sebaceous cells). The epidermis was markedly hyperplastic, presenting severe acanthosis and orthokeratosis and some keratinocytes showed moderate dysplasia. Immunohistochemical staining for Canine Papillomavirus was performed.

Therefore, this ferret presented two different processes affecting the skin: a sebaceous epithelioma in the superficial dermis and a **“papillomatous” proliferation of the epidermis** compatible with several diagnoses, such as: epidermal hyperplasia, squamous (non-viral) papilloma, viral papilloma, in-situ carcinoma and squamous cell carcinoma (SCC).

**Case 4**

**DERMATITIS IN SHEEP: WHAT IS YOUR DIAGNOSIS?**

*Zafra R<sup>1</sup>, Bautista MJ<sup>1</sup>, Pérez EM<sup>3</sup>, Oliver F<sup>3</sup>, Pacheco IL<sup>1</sup>, Escamilla<sup>2</sup>, Acosta P, Pérez J.*

*1University of Las Palmas de Gran Canaria, Spain 2University of Córdoba, Spain, 3CERSYRA, Valdepeñas, Spain, rafael.zafra@uco.es*

In this case report we presented for discussion the lesions found in a flock composed by 100 adult Manchega-bred male adult sheep. The majority of animals were affected and they showed good body condition. Clinical signs include a non-pruriginous dermatitis located in ventral areas of the body (sternal region, scrotum, ventral abdomen and medial aspect of the limbs). Later, these lesions evolved to hyperkeratosis and lichenification. Grossly, alopecia and diffuse erythema and hyperkeratotic foci were found in ventral areas. Antimicrobial therapy did not induce improvement of lesions. Skin samples were collected for histopathology and microbiological culture. The histopathological study revealed pseudoepitheliomatous hyperplasia and hyperkeratosis in epidermis and hair follicles. Some hair follicles, superficial dermis and sweat glands showed a pyogranulomatous reaction composed by neutrophils, eosinophils, macrophages and multinucleated giant cells. In addition, superficial dermis showed a severe diffuse infiltrate of neutrophils, eosinophils and lymphocytes was found around hair follicles. Parasitic structures were phagozytized by multinucleate giant cells and also were observed within hair follicles and sweat glands.

**Case 5**

**CASES OF NERVOUS CLINICAL SIGNS IN A GOAT HERD**

*Polledo L.<sup>1</sup>, Iglesias M.J.<sup>1</sup>, Ferrero C.<sup>2</sup>, Gonzalez J.<sup>3</sup>, Perez-Martinez C.<sup>1</sup>, Garcia-Marin J.F.<sup>1</sup>*

*1 Dpt of Animal Health. University of León, Spain. 2 Serclivet. Veterinary Practitioner. 2 3 Histoleon, Pathology Diagnostic Laboratory. jfgarm@unileon.es*

In a extensive production herd of 240 adult Murciano-Granadina goat breed, twelve animals showed nervous clinical signs: weakness of the hindlegs, opisthotonos and seizures. All animals affected died in 5-8 days. The affected animals appeared in May-June 2012, few days after their introduction in dry pastures. No gross lesions were observed. Histologically, demyelitation and malaci foci were detected in the cranial spinal cord, medulla oblongata and pons, with axonal degeneration and spheroids. Scattered foci of phagocytosis of myelin debris by macrophages were observed.



# **LIST OF PARTICIPANTS**



## LIST OF PARTICIPANTS

| <b>Name (Country)</b>                  | <b>Pages</b>                                     |
|--|--|
| Acín Tresaco, Cristina (Spain)         | 106, 165, 166, 167                               |
| Akane, Hirotishi (Japan)               | 255  |
| Aleksandersen, Mona (Norway)           |  |
| Aleksic-Kovacevic, Sanja (Serbia)      | 210  |
| Alexandru-Flaviu, Tabaran (Romania)    | 251  |
| Alves, Anabela (Portugal)              | 115, 141, 258                                    |
| Amarilla, Shyrlei Paola (Spain)        | 76, 190  |
| Andrada Borzollino, Marisa Ana (Spain) | 143, 184, 185, 186, 195, 218, 241, 245, 287, 296 |
| Artukovic, Branka (Croatia)            | 138  |
| Astrup, Larke Boye (Denmark)           | 99   |
| Babinska, Isabella (Poland)            | 163, 248, 291, 292                               |
| Bacci, Barbara (Australia)             | 135, 236   |
| Bader, Sophie (Germany)                |  |
| Badiola Diez, Juan José (Spain)        | 98, 106, 155, 166, 167, 169, 170, 192, 284       |
| Balseiro, Ana (Spain)                  | 74, 213  |
| Baudimont, Fannie (France)             |  |
| Beha, Germana (Italy)                  | 62   |
| Belluco, Sara (France)                 | 69, 72   |
| Bemelmans, Ingrid (France)             |  |
| Benavides Silvan, Julio (Spain)        | 77, 96, 154, 198, 207                            |
| Benazzi, Cinzia (Italy)                | 62   |
| Bergmann, Whilelmina (The Netherlands) | 108  |
| Berzina, Dace (Latvia)                 | 290  |
| Bettini, Giuliano (Italy)              | 145  |
| Biasibetti, Elena (Italy)              | 68, 243, 270                                     |
| Biolatti, Bartolomeo (Italy)           | 65, 259, 260                                     |
| Blundell, Richard (United Kingdom)     | 282  |
| Bock (Bastianello), Stella (Australia) |  |
| Bolfa, Pompei (Romania)                | 125, 153, 173, 227, 251, 295                     |
| Bollo, Enrico (Italy)                  | 92, 242  |
| Brandes, Kristin (Germany)             | 276  |
| Brown, Corrie (U.S.A.)                 | 51   |
| Brunetti, Barbara (Italy)              | 62, 88   |
| Bryan, Jill (Ireland)                  | 199  |
| Callanan, Sean (Ireland)               | 223  |
| Canadas, Ana Maria (Portugal)          | 119  |

## LIST OF PARTICIPANTS

| <b>Name (Country)</b>                      | <b>Pages</b>               |
|--|----------------------------|
| Canton, German (United Kingdom)            | 77, 202                    |
| Capucchio, Maria Teresa (Italy)            | 68, 182, 243, 270          |
| Cedillo Pelaez, Carlos (México)            | 230                        |
| Charline, Alleaume (France)                | 156                        |
| Chianini, Francesca (United Kingdom)       | 77, 97, 164, 202           |
| Chiers, Koen (Belgium)                     | 72, 95, 103, 107, 150, 277 |
| Cordonnier, Nathalie (France)              | 139                        |
| Corpa-Arenas, Juan Manuel (Spain)          | 191, 223                   |
| Coscelli, German (Spain)                   | 89, 247, 249, 298          |
| Costa Santos, Sara Isabel (Portugal)       |                            |
| Crameri, Flavio (Switzerland)              |                            |
| Cuesta García, Nerea (United Kingdom)      | 132, 238                   |
| Cuesta Gerverno, Jesus Maria (Spain)       | 261                        |
| Cuitiño, Maria (Argentina)                 | 133                        |
| Dally, Claire (France)                     |                            |
| David, Hugo (Portugal)                     | 225                        |
| Dávila Montero, Urso Martin (Spain)        | 275                        |
| De Azevedo Gomes, Ana Manuela (Spain)      | 89, 246, 247               |
| De Brot, Simone (Switzerland)              | 146, 244                   |
| De las Heras, Marcelo (Spain)              | 157, 181                   |
| De Zan, Gabrita (Italy)                    |                            |
| Delgado, Leticia (Spain)                   | 154, 197, 198, 207         |
| Dell'Armeline Rocha, Paulo Ricardo (Italy) | 68, 150, 182, 243, 270     |
| Deviers, Alexandra (France)                |                            |
| Di Palma, Stefano (Italy)                  |                            |
| Díaz, Josué (Spain)                        | 184, 218, 245              |
| Dittmer, Keren (New Zealand)               | 202                        |
| Dolka, Isabella (Poland)                   | 118, 144, 263              |
| Edwards, John (U.S.A.)                     | 49, 78                     |
| Ehrensperger, Felix (Switzerland)          |                            |
| Else, Roderick (United Kingdom)            |                            |
| Escamilla Sanchez, Alejandro (Spain)       | 208, 209, 304              |
| Espinosa de los Monteros, Antonio (Spain)  | 140, 143, 195, 245, 287    |
| Faisca, Rui-Pedro (Portugal)               | 127, 134, 137, 212, 225    |
| Feinstein, Ricardo (Sweden)                |                            |
| Fernandes Jesus, Joao (Portugal)           |                            |



## LIST OF PARTICIPANTS

| <b>Name (Country)</b>                      | <b>Pages</b>                         |
|--|--------------------------------------|
| Fernández, Antonio (Spain)                 | 184, 233, 234, 241, 245              |
| Fernández, Miguel (Spain)                  | 198, 201                             |
| Ferreras Estrada, María del Carmen (Spain) | 96, 154, 197, 198, 201, 207          |
| Figueira, Ana Catarina (Portugal)          |                                      |
| Filali, Hicham (Spain)                     | 98, 167                              |
| Flores, Juana (Spain)                      | 160, 161, 288                        |
| Fontaine, Jean Jacques (France)            |                                      |
| Fuertes Franco, Miguel (Spain)             | 154, 198, 207                        |
| Gaita, Liviu (Romania)                     | 147, 250                             |
| Galeotti, Marco (Italy)                    | 88                                   |
| Galindo Cardiel, Iván (Spain)              | 105, 214                             |
| Gama, Adelina (Portugal)                   | 66, 115, 258, 293                    |
| Gamino, Virginia (Spain)                   | 83, 85, 215                          |
| García Fernández, Rosa Ana (Spain)         | 161, 288                             |
| García González, Ángela María (Spain)      |                                      |
| García González, Beatriz (United Kingdom)  | 238                                  |
| García Iglesias, María José (Spain)        | 201, 281, 305                        |
| García Marín, Juan Francisco (Spain)       | 74, 96, 197, 198, 201, 305           |
| García Nicolás, Obdulio (Spain)            | 177, 178                             |
| García Quirós, Ana (Spain)                 | 191, 301, 303                        |
| Gers, Sophette (South Africa)              |                                      |
| Gómez, Luis (Spain)                        | 261                                  |
| Gomez-Laguna, Jaime (Spain)                | 75, 76, 114, 149, 177, 178, 179, 190 |
| González Fernández, Jorge (Spain)          | 201, 281, 305                        |
| González, Lorenzo (United Kingdom)         | 157, 164                             |
| Gortázar, Christian (Spain)                | 53, 213                              |
| Groene, Andrea (The Netherlands)           |                                      |
| Gruber, Achim (Germany)                    | 64, 262, 302                         |
| Gudan Kurilj, Andrea (Croatia)             | 138                                  |
| Guil-Luna, Silvia (Spain)                  | 63, 114, 117, 120, 237               |
| Guscetti, Franco (Switzerland)             | 70, 146                              |
| Gwozdz, Jacek (Australia)                  |                                      |
| Hard af Segerstad, Carl (Sweden)           | 128                                  |
| Herden, Cristiane (Germany)                | 174                                  |
| Hewicker-Trautwein, Marion (Germany)       | 278                                  |
| Hilbe, Monica (Switzerland)                | 211                                  |

## LIST OF PARTICIPANTS

| <b>Name (Country)</b>                            | <b>Pages</b>          |
|--|-----------------------|
| Hodge, Thomas (France)                           |                       |
| Högler, Sandra (Austria)                         | 101, 267              |
| Insausti, Nerea (Spain)                          | 169, 170, 194         |
| Isidoro, Marcos (Spain)                          | 228                   |
| Jager, Kathrin (Germany)                         | 239                   |
| Jahns, Hanne (Ireland)                           | 104, 223              |
| Jesus Correia, Jorge Manuel (Portugal)           | 94, 122, 123, 124     |
| Jimenez Martínez, M <sup>a</sup> Angeles (Spain) | 91                    |
| Jovanovic, Milijan (Serbia)                      | 210, 269              |
| Juntes, Polona (Slovenia)                        | 235                   |
| Juste, Ramón (Spain)                             | 57, 79, 157           |
| Karkamo, Veera (Finland)                         | 268                   |
| Karlstam, Erika (Sweden)                         | 128                   |
| Kaspereit, Joachim (Germany)                     | 159                   |
| Kipar, Anja (Finland)                            | 171, 280              |
| Kuehn, Nicolas (Switzerland)                     |                       |
| Kukolj, Vladimir (Serbia)                        | 210                   |
| Kureljusic, Branislav (Serbia)                   | 256                   |
| Kuus, Merle (Estonia)                            |                       |
| Laloy, Eve (France)                              | 139                   |
| Langenmayer, Martin (Germany)                    |                       |
| Leeming, Gail (United Kingdom)                   | 171                   |
| Leifsson, Pall (Denmark)                         | 99                    |
| Leipig, Miriam (Germany)                         | 81                    |
| Lilia, Boulouha (France)                         |                       |
| Lindberg, Rony (Sweden)                          | 102                   |
| López Pérez, Mónica (Spain)                      | 273                   |
| Losada García, Ana Paula (Spain)                 | 87, 89, 246, 247, 249 |
| Luca, Roberta (Italy)                            | 67                    |
| Luján, Lluís (Spain)                             | 169, 170, 194         |
| Machado, Gisele (Brazil)                         | 126                   |
| Majo, Natalia (Spain)                            | 83                    |
| Mandara, Maria Teresa (Italy)                    | 136                   |
| Maniscalco, Lorella (Italy)                      | 63, 65, 120           |
| Markina, Anastasia (Russia)                      |                       |
| Marques, Oriana (Portugal)                       | 119, 225              |

## LIST OF PARTICIPANTS

| <b>Name (Country)</b>                            | <b>Pages</b>                 |
|--|------------------------------|
| Martín Caballero, Juan (Spain)                   | 264                          |
| Martín de las Mulas, Juana (Spain)               | 63, 114, 117, 120            |
| Martínez Fernández, Beatriz (Spain)              | 96, 281                      |
| Martínez Martínez, Jorge (Spain)                 | 216, 228                     |
| Matiasek, Kaspar (Austria)                       |                              |
| Méndez, Aniceto (Spain)                          | 275                          |
| Millan Ruiz, Yolanda (Spain)                     | 63, 65, 114, 117, 120        |
| Moayer, Fariborz (Iran)                          | 196, 266                     |
| Moreau, Stephanie (France)                       |                              |
| Moreno Burgos, Bernardino (Spain)                | 155, 157, 170, 192, 284      |
| Morita, Reiko (Japan)                            | 254                          |
| Mortazavi, Sayedpejman (Iran)                    | 262                          |
| Mozos Mora, Elena (Spain)                        | 203, 237                     |
| Nagy, Andras (Romania)                           | 153, 173, 227, 251, 295      |
| Naranjo Freixa, Carolina (Spain)                 | 288                          |
| Navarro Cámara, Jose Antonio (Spain)             | 187, 188                     |
| Nesic, Sladjan (Serbia)                          | 269                          |
| Nguyen, Frederique (France)                      | 61, 113                      |
| Noiva, Rute (Portugal)                           | 94, 240                      |
| Ojok, Lonzy (Uganda)                             |                              |
| Olofsson, Karin (Sweden)                         | 102                          |
| Ortega Porcel, Joaquin (Spain)                   | 129, 301, 303                |
| Ortiz, Ana Liza Cardoso Neto Oliviera (Portugal) | 286, 297                     |
| Osinska, Barbara (Poland)                        | 144, 226, 231                |
| Pacheco Luque, Isabel Lourdes (Spain)            | 208, 209, 304                |
| Pallarés Martínez, Francisco José (Spain)        | 177, 178                     |
| Pearson, Geoff (United Kingdom)                  | 90                           |
| Peleteiro, Maria (Portugal)                      | 94, 134, 240                 |
| Penades Fons, Mariola (Spain)                    | 191, 301, 303                |
| Peña, Laura (Spain)                              | 55, 72, 91                   |
| Peperkamp, Klass (Italy)                         | 73                           |
| Pereira, Daniela (Portugal)                      | 66, 115                      |
| Pereira, Miguel (Portugal)                       | 201                          |
| Pérez Arévalo, José (Spain)                      | 172, 203, 208, 209, 233, 234 |
| Pérez Écija, Rafael Alejandro (Spain)            | 148, 149, 172                |
| Pérez Pérez, Valentín (Spain)                    | 96, 197, 198, 201, 207       |

## LIST OF PARTICIPANTS

| <b>Name (Country)</b>                        | <b>Pages</b>  |
|--|---|
| Pérez-Martínez, Claudia (Spain)              | 74, 201, 281, 305                                   |
| Pérez, Marta María (Spain)                   | 169, 170, 194, 195                                  |
| Pinczowski, Pedro (Spain)                    | 169, 170, 194                                       |
| Pires, Maria Dos Anjos (Portugal)            | 71, 72, 121, 141, 142, 219, 221, 229, 272, 289, 293 |
| Pitarch Moran, Jose Luis (Spain)             | 106, 165, 167                                       |
| Plog, Stephanie (Germany)                    | 262, 302  |
| Pohlmeyer-Esch, Gabriele (France)            |   |
| Polledo, Laura (Spain)                       | 96, 281, 305  |
| Pospischil, Andreas (Switzerland)            | 211   |
| Posthaus, Horst (Switzerland)                | 86  |
| Prata, Daniela (France)                      |   |
| Pumarola, Batlle, Martí (Spain)              | 98, 136, 167, 204, 264                              |
| Ramis, Antonio (Spain)                       | 177, 178, 216, 228                                  |
| Rasotto, Roberta (Italy)                     | 56  |
| Rayner, Emma (United Kingdom)                | 90  |
| Reinacher, Manfred (Germany)                 |   |
| Risalde Moya, M <sup>a</sup> Ángeles (Spain) | 294   |
| Ristoski, Trpe (Macedonia)                   | 283   |
| Roccabianca, Paola (Italy)                   |   |
| Rodríguez Gómez, Irene Magdalena (Spain)     | 75, 149, 177, 179                                   |
| Roels, Stefan (Belgium)                      | 168, 257  |
| Romero Palomo, Fernando (Spain)              | 294   |
| Romero, Debora Cristina (Brazil)             | 85, 131, 167, 215, 294                              |
| Ronza, Paolo (Spain)                         | 87, 89, 247, 249                                    |
| Roperto, Franco Peppino (Italy)              | 67  |
| Sakai, Yusuke (Japan)                        | 183   |
| Sánchez Campillo, Joaquin (Spain)            | 187, 188  |
| Sánchez Céspedes, Raquel (Spain)             | 63, 114, 117, 120                                   |
| Sancho Silva, Ana Rita (Spain)               | 89, 247, 298  |
| Saraiva, Ana (Portugal)                      | 71, 141, 142, 232                                   |
| Schmidt-Posthaus, Heike (Switzerland)        | 86  |
| Scholes, Sandra (United Kingdom)             | 47  |
| Seixas, Fernanda (Portugal)                  | 121   |
| Shibutani, Makoto (Japan)                    | 255   |
| Shirota, Kinji (Japan)                       | 176, 279  |
| Shokrai, Arman (Sweden)                      |   |

## LIST OF PARTICIPANTS

| <b>Name (Country)</b>                  | <b>Pages</b>                 |
|--|------------------------------|
| Simola, Outi (Finland)                 |                              |
| Smith, Ken (United Kingdom)            |                              |
| Soares, Maria (Portugal)               | 122, 123, 124                |
| Suarez, Christian (Spain)              | 160                          |
| Sukura, Antti (Finland)                |                              |
| Szarek, Jozef (Poland)                 | 248, 252                     |
| Szczotka, Anna (Poland)                | 180, 206                     |
| Szczotka, Maria (Poland)               | 151                          |
| Taniai, Eriko (Japan)                  | 253                          |
| Taulescu, Marian (Romania)             | 125, 153, 173, 227, 251, 295 |
| Tripathi, B.N (India)                  | 80                           |
| Une, Yumi (Japan)                      | 217                          |
| Url, Angelika (Austria)                | 101                          |
| Vala, Helena (Portugal)                | 162, 285, 286, 289, 297      |
| Van de Brand, Judith (The Netherlands) | 93                           |
| Van den Ingh, Ted (The Netherlands)    |                              |
| Van Driessche, Karolien (Belgium)      | 107                          |
| Verdes, Jose Manuel (Uruguay)          | 100                          |
| Viana Martín, David (Spain)            | 129, 191, 301                |
| Vilafranca Compte, Miguel (Spain)      | 140                          |
| Vrijenhoek, Mieke (The Netherlands)    |                              |
| Walter, Jakob (Germany)                |                              |
| Wegge, Beatrice (Belgium)              | 103, 168                     |
| Welle, Monika (Switzerland)            | 109                          |
| Wiener, Dominique (Switzerland)        | 109                          |
| Yasuno, Kyohei (Japan)                 | 279                          |
| Yoon, Soon-Sick (Republic of Korea)    | 222                          |
| Zafra Leva, Rafael (Spain)             | 172, 203, 208, 209, 233, 234 |
| Zuraw, Aleksandra (Poland)             |                              |

NOTES

NOTES





NOTES



# Sponsors

---



universidad  
de León

*Leica*

MICROSYSTEMS



Duerolab, S.L.  
Equipamiento de Laboratorio

**abcam**<sup>®</sup>  
*discover more*

**W** WORLD **P**  
PATHOL

**OLYMPUS**

Your Vision, Our Future



THE 31ST MEETING OF THE  
EUROPEAN SOCIETY & COLLEGE  
OF VETERINARY PATHOLOGISTS  
LONDON 2013

**31st Meeting of the European Society of Veterinary Pathology**

**and the**

**Annual Meeting of the European College of Veterinary Pathologists**

**The Institute of Education**

**University of London**

**London, UK**

**4th – 7th September 2013**

***Keynote themes:***

*Diseases of rabbits*

*Orthopaedic pathology in athletes*

*The role of the pathologist in biosecurity*

*Tuberculosis*

*Papillomaviruses in animal tumours*

Email: [esvp2013@gmail.com](mailto:esvp2013@gmail.com)

Website: [www.esvp2013.co.uk](http://www.esvp2013.co.uk)

